

the Ophthalmologist™

In My View

Working in the wake
of COVID-19

10

In Practice

A practical guide to
cataract complications

28 – 31

NextGen

CHLA researcher uncovers
novel biopsy method

42 – 43

Sitting Down With

CEO of Rayner,
Tim Clover

48 – 51

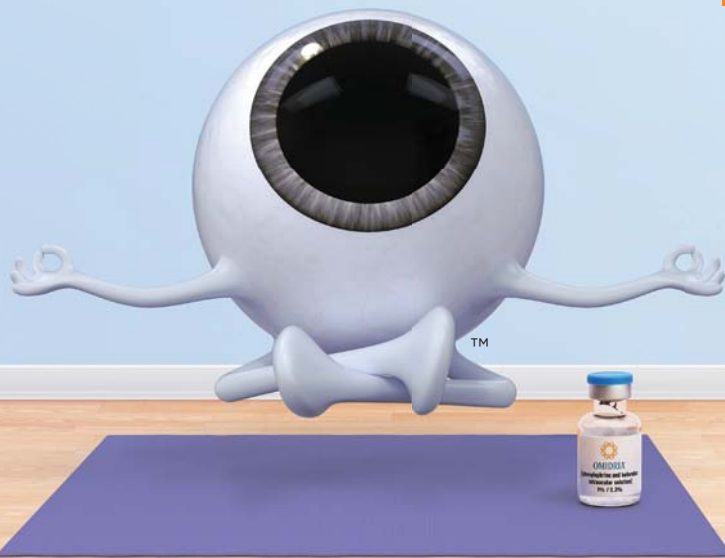Further Afield

Overcoming eye care issues in
underserved populations

14 – 26



Less stress, pure success ...in your O.R. day²



OMIDRIA® (phenylephrine and ketorolac intraocular solution) 1% / 0.3% is added to ophthalmic irrigating solution used during cataract surgery or intraocular lens replacement and is indicated for maintaining pupil size by preventing intraoperative miosis and reducing postoperative ocular pain.

The data are compelling and consistent—OMIDRIA makes cataract surgery better for you and your patients

Published and presented clinical data and manuscripts in preparation report that in post-launch (i.e., not included in current labeling), prospective and retrospective, double-masked and open-label, cohort and case-controlled, single and multi-center studies, the use of OMIDRIA statistically significantly:

- Prevents intraoperative floppy iris syndrome (IFIS)³
- Prevents iris prolapse³

Compared to steroids*:

- Reduces cystoid macular edema (CME)^{4,5}
- Decreases breakthrough iritis⁴
- Reduces pain photophobia⁴

*OMIDRIA used intraoperatively with postoperative NSAIDs (no steroids) when compared to postoperative steroids with or without NSAIDs (no OMIDRIA).

Compared to epinephrine:

- Decreases complication rates⁶
- Decreases use of pupil-expanding devices (PEDs)⁶⁻¹¹
- Enables performance of surgery and postoperative care without the use of steroids—allowing NSAID-only anti-inflammatory therapy^{4,5,7}
- Shortens surgical times^{6,7,9,10}
- Reduces need for opioids (i.e., fentanyl) during surgery while decreasing VAS pain scores¹²
- Prevents miosis during femtosecond laser-assisted surgery^{11,13}
- Improves uncorrected visual acuity on day after surgery⁶

VAS = visual analog scale

OMIDRIA inhibits the release of inflammation-causing prostaglandins, preventing miosis and reducing postoperative pain¹⁴

OMIDRIA is separately reimbursed under Medicare Part B and by many Medicare Advantage and commercial payers.[†] Contact your OMIDRIA representative today or visit omidria.com to learn more.

[†]Based on currently available information and subject to change without notice. Individual plan coverage, payment, policies, and procedures may vary and should be confirmed by the facility. Omeros does not guarantee coverage or payment.

IMPORTANT SAFETY INFORMATION

OMIDRIA must be added to irrigating solution prior to intraocular use.

OMIDRIA is contraindicated in patients with a known hypersensitivity to any of its ingredients.

Systemic exposure of phenylephrine may cause elevations in blood pressure.

Use OMIDRIA with caution in individuals who have previously exhibited sensitivities to acetylsalicylic acid, phenylacetic acid derivatives, and other nonsteroidal anti-inflammatory drugs (NSAIDs), or have a past medical history of asthma.

The most commonly reported adverse reactions at $\geq 2\%$ are eye irritation, posterior capsule opacification, increased intraocular pressure, and anterior chamber inflammation.

Please see the Full Prescribing Information for OMIDRIA at www.omidria.com/prescribinginformation.

You are encouraged to report Suspected Adverse Reactions to the FDA.

Visit www.fda.gov/medwatch, or call 1-800-FDA-1088.

References: 1. HCPCS quarterly update. CMS.gov. Available at: <https://www.cms.gov/medicare/coding/hcpcsrulesetupdates/hcpcs-quarterly-update.html>. Accessed August 9, 2019. 2. Omeros survey data on file. 3. Silverstein SM, Rana V, Stephens R, et al. Effect of phenylephrine 1.0%-ketorolac 0.3% injection on tamulosin-associated intraoperative floppy-iris syndrome. *J Cataract Refract Surg*. 2018;44(9):1103-1108. 4. Visco D, et al. Study to evaluate patient outcomes following cataract surgery when using OMIDRIA with postoperative topical NSAID administration versus a standard regimen of postoperative topical NSAIDs and steroids. Presented at: 28th Annual Meeting of the American College of Eye Surgeons (ACES), the American Board of Eye Surgery (ABES), and the Society for Excellence in Eyecare (SEE), Caribbean Eye Meeting, February 1-5, 2019; Cancun, Mexico. 5. Walter K, Kauffman L, Hess J. Rate of pseudophakic cystoid macular edema using intraoperative and topical NSAIDs alone without steroids. Manuscript submitted for publication. 2019. 6. Rosenberg ED, Nattis AS, Alevi D, et al. Visual outcomes, efficacy, and surgical complications associated with intracameral phenylephrine 1.0%/ketorolac 0.3% administered during cataract surgery. *Clin Ophthalmol*. 2018;12:21-28. 7. Al-Hashimi S, Donaldson K, Davidson R, et al. Medical and surgical management of the small pupil during cataract surgery. *J Cataract Refract Surg*. 2018;44:1032-1041. 8. Bucci FA Jr, Michalek B, Fluet AT. Comparison of the frequency of use of a pupil expansion device with and without an intracameral phenylephrine and ketorolac injection 1%/0.3% at the time of routine cataract surgery. *Clin Ophthalmol*. 2017;11:1039-1043. 9. Visco D. Effect of phenylephrine/ketorolac on iris fixation ring use and surgical times in patients at risk of intraoperative miosis. *Clin Ophthalmol*. 2018;12:301-305. 10. Matossian C, Teves N. Clinical outcomes of phenylephrine/ketorolac intraocular solution versus epinephrine in cataract surgery in a real-world setting. Manuscript submitted for publication. 2018. 11. Walter K, Delwadia N, Cohen J. Continuous intracameral phenylephrine-ketorolac irrigation for miosis prevention in femtosecond laser-assisted cataract surgery: reduction in surgical time and iris manipulation. *J Cataract Refract Surg*. 2019;45(4):465-469. doi: 10.1016/j.jcrs.2018.11.004. 12. Donnenfeld E, Shojai R. Effect of intracameral phenylephrine and ketorolac 1.0%/0.3% on intraoperative pain and opioid use during cataract surgery. Manuscript submitted for publication. 2019. 13. Gayton JL. Effect of early phenylephrine and ketorolac injection 1% / 0.3% (Omidria®) usage on pupil diameter in traditional and femtosecond laser assisted cataract surgery. E-poster presented at: 15th International Congress on Vision Science and Eye; August 10-11 2017; London, UK. 14. OMIDRIA [package insert]. Seattle, WA: Omeros Corporation; 2017.

OMIDRIA® and the OMIDRIA logo® are registered trademarks of Omeros Corporation.

© Omeros Corporation 2019, all rights reserved. 2019-050



OMIDRIA®
(phenylephrine and ketorolac
intraocular solution)
1% / 0.3%



The only time I ventured out of my house last month (other than for “sanctioned” grocery shopping or daily exercise) was to donate blood. The center was eerily empty – social distancing guidelines and the need to operate at 40-50 percent capacity – but the staff were as welcoming and positive as ever. These days, blood donation is an essential aspect of our healthcare systems, but I recently discovered (lockdown is a good time to read...) that the catalyst for development was a moment of great global crisis: World War I. In 1917, in preparation for the Third Battle of Ypres, recent successes in transfusion, as well as the preserving and storing of blood, coupled with the need to rapidly treat wounded soldiers, resulted in the establishment of the first blood donation and storage facilities.

It's sometimes difficult to believe that the crisis we are currently living in can bring about anything positive, but realization of longer-term change is starting to dawn.

Many ophthalmologists, faced with the cancelation of all elective procedures and non-urgent appointments, have started conducting virtual consultations; for Malik Kahook, whose Pandemic Diary is on page 11, virtual health (VH) has suddenly become a day-to-day reality. And on page 32, experts from Moorfields Eye Hospital explore the possibilities of using telemedicine to protect both ophthalmologists and patients during periods of social distancing – or in the event of quarantine or self-isolation.

Distancing regulations and guidelines are likely to last for several months in many countries (1). But will telehealth services become the “new normal” even when other aspects of healthcare get back on track? Rishi Singh, the author of this issue's Profession article, encourages ophthalmologists to see the COVID-19 pandemic as a time to rethink some currently-used solutions and to explore innovative technologies.

I recently spoke with a glaucoma specialist who is acutely aware of the huge backlog of patients who will need to be seen when circumstances finally allow for it. Future predictions of greatly increased patient numbers and outstretched services are now a very real and immediate prospect for ophthalmologists around the world. Much like blood donor centers, what may have started as a forced necessity under exceptional circumstances could become standard practice in the long run.

Reference

1. SM Kissler et al., “Projecting the transmission dynamics of SARS-CoV-2 through the postpandemic period”, *Science*, [Epub ahead of print] (2020). PMID: 32291278.

Aleksandra Jones
Editor



- 03 **Editorial**
The Mother of Invention
by Aleksandra Jones

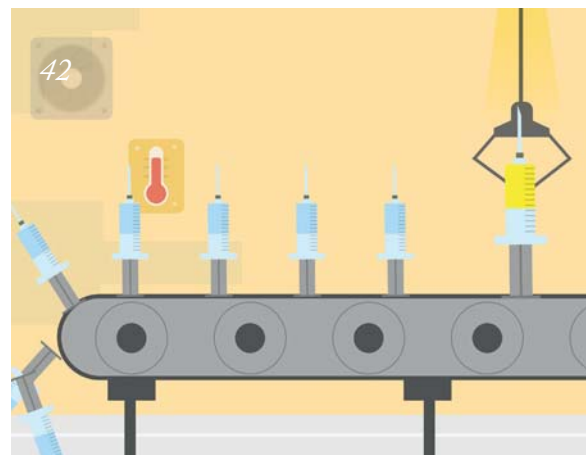
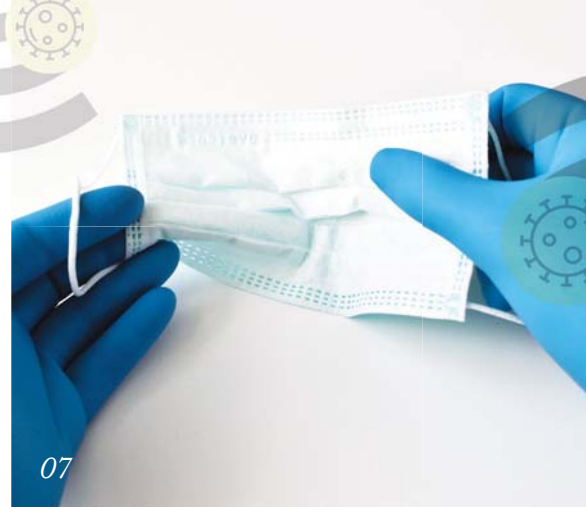Upfront

- 06 The latest news, views and research – from Andrzej Grzybowski's Current Concepts in Ophthalmology to a potential treatment pathway to complement regulation in AMD

On The Cover



Image by Terry Cooper, who spent time in Uganda working with Simon Arunga, getting traditional healers involved in preventing blindness



In My View

- 10 **Pandemic Diaries**
In April, the Health Service Executive in Ireland announced that every single private hospital was being taken over by the public service – and, just like that, Arthur Cummings lost his private practice overnight

Feature

- 14 **Further Afield**
Simon Bush, Simon Arunga, and Johanna Wiedemann discuss the challenges of overcoming eye care issues in underserved populations, from dangers of using traditional medicine in Uganda, to humanitarian projects in the Amazon



In Practice

28 **When Complications Strike**
Sumitra Khandelwal's no-nonsense guide to tackling complex cataract cases – triggered by pre-existing conditions or the surgeon – at the operating table

32 **Tackling COVID-19 with Telemedicine**
With the pandemic putting frontline health workers under mounting pressure, is it possible for ophthalmologists to safely see patients? Dawn Sim, Peter Thomas, and Chris Canning discuss

35 **Wait, Treat, Repeat?**
With DME remaining a major cause of vision loss, it is essential that ophthalmologists know how to manage it in the most effective way, says Rod McNeil

38 **The LASIK Evolution**
Better aberrometry measurements and refined flap parameters have continuously improved LASIK results – but there is still work to be done, says Kerry Assil

NextGen

42 **Liquid Gold**
CHLA researcher Jesse Berry explains how she uncovered a breakthrough biopsy method for retinoblastoma and why it will open the door to a more accurate treatment response

Profession

46 **From Necessity Comes Invention**
For Rishi Singh, COVID-19 is an opportunity for creativity. From virtual visits to home testing, there are plenty of ways to continue caring for patients – if you are able to try

Sitting Down With

48 **Tim Clover, CEO of Rayner,**
passionate about R&D

the Ophthalmologist

ISSUE 44 - MAY 2020

Feel free to contact any one of us:
first.lastname@texerepublishing.com

Content Team

Editor – Aleksandra Jones
Kirstie Anderson (Commercial Editor)
Phoebe Harkin (Deputy Editor)
Lauren Robertson (Deputy Editor)

Commercial Team

Publishing Director – Neil Hanley
Sam Blacklock (Associate Publisher)
Paul Longley (Business Development Executive)
Ross Terrone (Business Development Executive Americas)

Design Team

Head of Design – Marc Bird
Hannah Ennis (Senior Designer)
Charlotte Brittain (Designer)

Digital Team

Digital Team Lead – David Roberts
Peter Bartley (Digital Producer Web/Email)
Abygail Bradley (Digital Producer Web/App)

Audience Team

Audience Growth Strategy Manager
– Brice Agamemnon

CRM & Compliance

CRM & Compliance Manager – Tracey Nicholls
Hayley Atiz (CRM Assistant)

Commercial Support Team

Internal Systems Manager – Jody Fryett
Dan Marr (Campaign Reporting Analyst)
Jennifer Bradley (Production Assistant)
Lindsey Vickers (Project Manager – Webinars)

Events Team

Events Manager – Alice Daniels-Wright
Jess Lines (Events Coordinator)

Marketing Team

Marketing Manager – Katy Pearson
Jo Baylay (Marketing Executive)
Kevin O'Donnell (Marketing Executive)
Matt Everett (Social Media Manager)
Joe Box (Social Media Assistant)

Accounts Team

Kerri Benson (Accounts Assistant)
Emily Scragg (Accounts Apprentice)

Human Resources

Human Resource Manager – Tara Higby

Management Team

Chief Executive Officer – Andy Davies
Chief Operating Officer – Tracey Peers
Senior Vice President (North America) – Fedra Pavlou
Financial Director – Phil Dale
Commercial Director – Richard Hodson
Content Director – Rich Whitworth

Change of address: info@theophthalmologist.com
Hayley Atiz, The Ophthalmologist, Texere Publishing,
175 Varick St, New York, NY 10014.

General enquiries
www.texerepublishing.com | info@theophthalmologist.com
+44 (0) 1565 745 200 | sales@texerepublishing.com

Distribution: The Ophthalmologist North America
(ISSN 2398-9270), is published monthly by Texere Publishing
Inc, 175 Varick St, New York, NY 10014. Single copy sales
\$15 (plus postage, cost available on request info@info@
theophthalmologist.com). Non-qualified annual subscription cost
is available on request.

Reprints & Permissions – tracey.nicholls@texerepublishing.com
The opinions presented within this publication are those of the authors
and do not reflect the opinions of The Ophthalmologist or its publishers,
Texere Publishing. Authors are required to disclose any relevant
financial arrangements, which are presented at the end of each article,
where relevant. © 2017 Texere Publishing Limited. All rights
reserved. Reproduction in whole or in parts is prohibited.

texere
publishing



The H Factor

Researchers uncover a new connection between elevated FHR-4 levels and AMD

Researchers have found increased levels of complement factor H-related Protein 4 (FHR-4) in plasma and serum samples of 484 late AMD patients (characterized by geographic atrophy and/or choroidal neovascularization) compared with 522 phenotype controls (1). Further, the research team – based out of Cardiff University, Queen Mary University of London, the University of Manchester, and Radboud University Medical Center – found FHR-4 present in the AMD-affected parts of the eye.

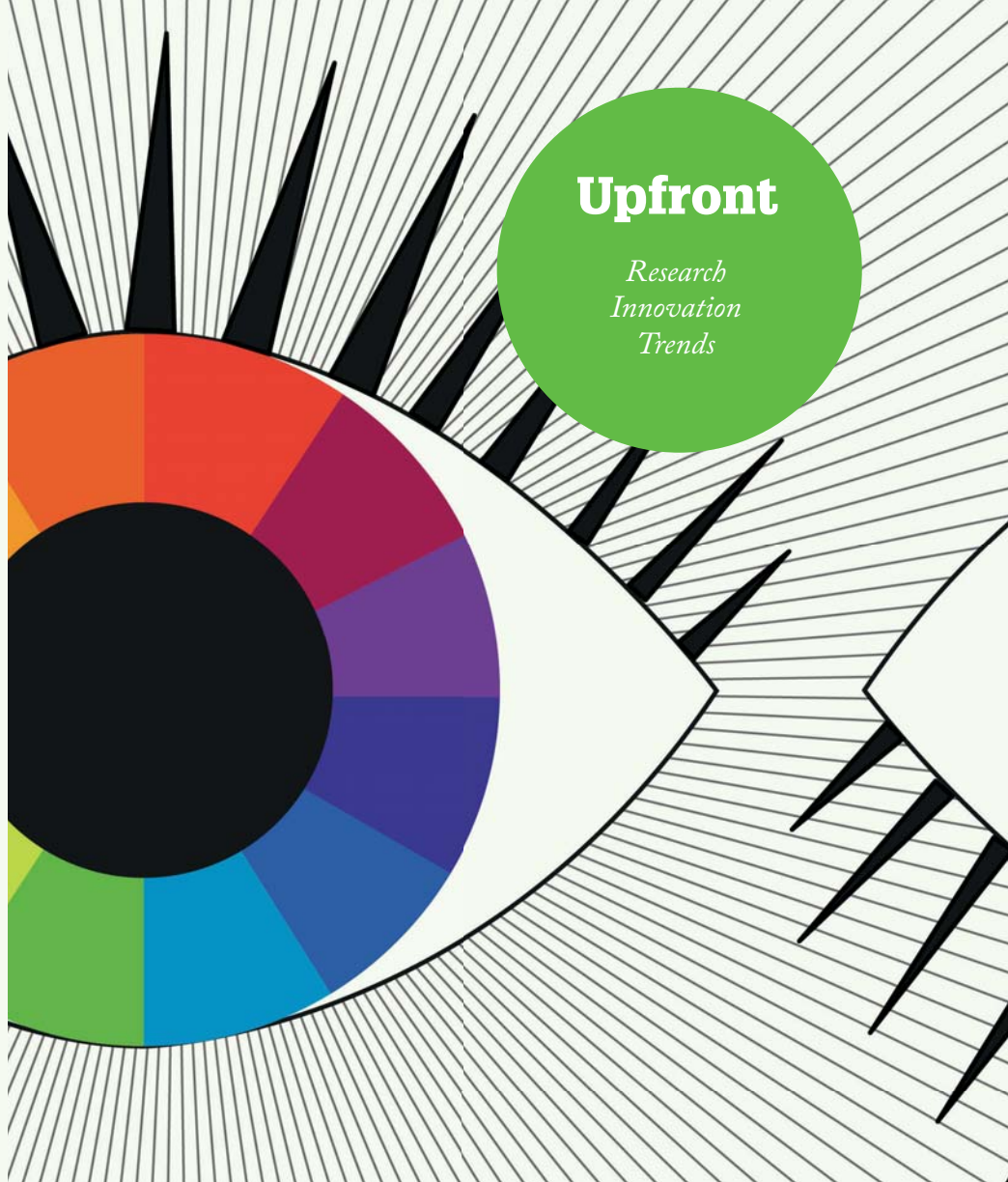
To discover whether increased levels of FHR-4 were a cause or consequence of AMD, the team turned to genetics. The genes coding for factor H, FHR-4 and other FH-family proteins are typically found in a tight cluster on chromosome 1. A genome-wide association study revealed that variants in this gene cluster have the biggest effect on FHR-4 levels, overlapping with other chromosome 1 variants that determine a well-established 20-year-old genetic risk of AMD. The team's findings suggest that genetically determined increases in blood FHR-4 levels lead to more FHR-

4 in the eye, which in turn increase the risk of the uncontrolled complement activation that drives the disease. The team hopes its findings will provide a new route to treatment by restoring

complement control in the eye.

Reference

1. V Cipriani et al., *Nature*, 11, 778 (2020). PMID: 32034129.



INFOGRAPHIC

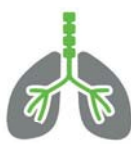Recommended Protocols for Seeing Patients

The guidelines for limiting the risk of infection

TRIAGE PATIENTS PRIOR TO ENTERING THE WAITING ROOM FOR:



Fever



Respiratory illness

Contact with a person with confirmed COVID-19 in the last 2 to 14 days



YES:

Send home to speak to primary care physician

NO:

Keep patients at least 6 feet from one another

USE COMMERCIALLY AVAILABLE SLIT-LAMP BARRIERS OR BREATH SHIELDS

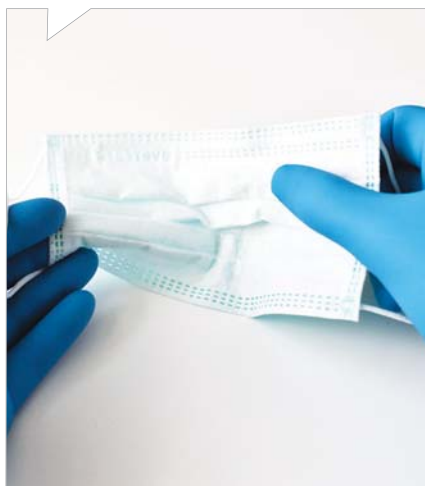



BUSINESS IN BRIEF

The industry's contributions to the global fight against COVID-19

- In light of global PPE shortages, SimulEYE has shifted its focus from the design of ophthalmic surgical training models to the manufacture and sale of protective equipment. The line currently consists of extra-large breath and germ shields and face masks, all built in the USA to stringent medical guidelines.
- Johnson & Johnson has partnered with BARDA to accelerate research into a potential COVID-19 vaccine. They have collectively



invested \$1 billion to increase global manufacturing capacity in the hopes of supplying more than one billion doses of the vaccine. Phase 1 human clinical studies are expected to start by September 2020, with the first batches available for use expected in early 2021.

- ImprimisRx has announced an exclusive agreement with US platform, Doxy.me, to provide more than 100,000 healthcare professionals with the Clinic level Doxy.me telemedicine solution for free. The move comes as recent regulation changes allow telemedicine services to cross state lines, limiting the need for face-to-face interaction.
- Bausch Health Companies has outlined several initiatives to support healthcare providers during the pandemic. They are ramping up production of chloroquine and azithromycin with the goal of donating products where and when needed, and have already begun donating antiviral VIRAZOL for nebulization in Italy.
- The US Federal Communications Commission has funneled \$200 million into not-for-profit and teaching hospitals, clinics and local health agencies to support telehealth as part of the Coronavirus Aid, Relief and Economic Security Act.

Checking on the Kids

With pediatric visual acuity visits postponed, can home-based testing options fill the gap?

During the COVID-19 pandemic, many scheduled appointments are canceled or postponed – including those for pediatric patients, whose visual acuity (VA) is not currently being monitored by professionals. Nevertheless, there are ways in which parents can check VA at home, using smartphone-based systems – and many practices are looking into setting up virtual appointments. Available options include Peek Acuity's vision check apps for Android smartphones (1) and the iSight Pro app from Kay Pictures, which is available free of charge for the next six months on Apple devices (2). Kay Pictures is developing a version specifically dedicated for parents. Notably, further research into safety and efficacy of VA testing conducted by parents is needed.

References

1. Peek, "Peek Acuity" (2019). Available at: <https://bit.ly/2XyBdbK>.
2. Kay Pictures, "6 Months Free Use of iSight Pro" (2020). Available at: <https://bit.ly/2xr1uOs>.

USE A **SURGICAL MASK** OR CLOTH FOR THE PATIENT



USE A SURGICAL MASK OR AN N95 MASK WHEN AVAILABLE, AND **EYE PROTECTION** FOR YOURSELF

USE **TELEMEDICINE/ TELEHEALTH SERVICES** WHERE POSSIBLE

Source: AAO, "Important coronavirus updates for ophthalmologists" (2020). Available at: <https://bit.ly/2V6W0BH>.

A Broad View of the Field

How to keep an eye on recent developments in ophthalmology

Andrzej Grzybowski, Professor of Ophthalmology and Chair of the Department of Ophthalmology at the University of Warmia and Mazury in Olsztyn, Poland, tells us how his book – *Current Concepts in Ophthalmology* – offers readers a helicopter view of the latest advances.

What inspired the project?

Like most ophthalmologists, I am a specialist: in cataract and refractive surgery – the anterior segment – but I am also trained retina surgeon, although I'm presently involved mostly in some research projects in medical retina. These are not small areas of expertise, and keeping up with all the latest news, research, and innovations takes a lot of time and effort.

I looked for a book that would give me an overview of the most important current concepts and main contributions in areas of ophthalmology outside of my



subspecialties and, surprisingly, I could not find one. So I decided to publish it myself!

What were your guiding principles in compiling the book?

I knew that the key to success was inviting world-renowned experts on the topics covered, and I can say that each area is presented by an unquestioned authority on the subject. I asked them all the same question: which achievements from your field in the last few years have had the biggest impact on moving ophthalmology forward?

From the start, I knew we couldn't possibly feature every single important aspect of eye care – it would require many volumes, across tens of thousands of pages. My brief for the chapter authors

was to include whatever vital information they could feature on 30 pages.

What is the biggest strength of the publication?

The wonderful authors are the best guarantee that the content is relevant and current. These leading experts include Jorge Alio on refractive surgery, Vincenzo Sarnicola on cornea, Keith Barton on glaucoma, Francesco Bandello on macula, Sue Lightman on uveitis, Harry Flynn on vitreoretinal surgery, Neil Miller on neuro-ophthalmology, Ken Nischal on pediatric ophthalmology, and Bertil Damato on ocular oncology.

Current Concepts in Ophthalmology, edited by Andrzej Grzybowski, is available from Springer.

Ghana's Hidden Hero

Sightsavers advisor shortlisted for a prestigious humanitarian prize

Agatha Aboe, a Sightsavers Global Trachoma Advisor, has been shortlisted for a coveted humanitarian honor at The Bond International Development Awards.

Aboe, from Accra, Ghana, was nominated for her work implementing house-to-house searches in the northern and upper west regions of the country to find people with trachomatous trichiasis – the most severe stage of the disease. Her idea helped Ghana become the first sub-Saharan African country to eliminate trachoma in June 2018. Ghana's Ministry of Health awarded Aboe a Citation of Honor, stating, "The story of the elimination of trachoma in Ghana cannot be complete without the mention of her name. She stood as a strong

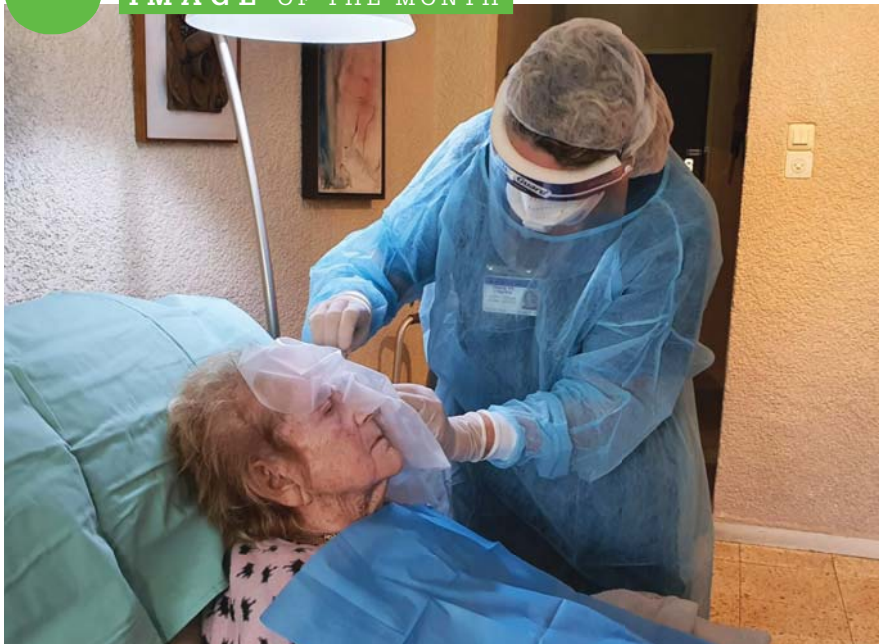pillar and saw the program through from beginning to end."

Aboe's response? "Blinding trachoma has plagued humanity for thousands of years, but we are now on the cusp of ending it. It is an honor to have spent a large part of my career working to help achieve this mission."





IMAGE OF THE MONTH

*Stay at Home*

Intravitreal injections administered at the patient's home during the COVID-19 pandemic.

Credit: Anat Loewenstein, Chair, Division of Ophthalmology, Tel Aviv Medical Center; Vice dean, Sackler Faculty of Medicine, Tel Aviv University, Israel

Would you like your photo featured in Image of the Month?
Send it to edit@theophthalmologist.com

QUOTE OF THE MONTH

"While I am well and my family is healthy, I work with tears in my eyes and a pit in my stomach."

Louis R. Pasquale, Professor of Ophthalmology and Site Chair at the Department of Ophthalmology; Director, Mount Sinai/NYEE Eye and Vision Research Institute, New York, USA

Lifting the Cloud

Research into a rare genetic disease could improve understanding of glaucoma

A new retrospective observational study sheds light on a rare hereditary neurodegenerative disorder – familial amyloid polyneuropathies (FAP). FAP is usually diagnosed by the age of 50, leaving patients with less than 10 years to live; ocular symptoms include cloudiness and glaucoma. The disease attacks the liver and eyes, because it affects a gene encoding a protein called TTR, produced in those organs. The study conducted at Shinshu University Hospital in Matsumoto, Japan, shares best practice protocols developed while caring for patients with FAP, including the use of small-gauge vitrectomy, which resulted in an improvement of patients' vision, but meant that IOP had to be closely monitored and surgically managed. Researchers hope that this study of a very rare disorder can help better understand post-vitrectomy IOP changes.

Reference

1. S Kakiyama et al., *Sci Rep*, 10, 5574 (2020). PMID: 32221479.

SPECIAL SERIES
Glaucoma Management

In My View

Experts from across the world share a single strongly held opinion or key idea.



Pandemic Diaries: Ophthalmology in the Time of Coronavirus

We asked ophthalmologists around the world to tell us how their professional and personal lives have changed during the COVID-19 pandemic

Steve Charles, CEO and Founder, Charles Retina Institute, Clinical Professor of Ophthalmology, University of Tennessee, TN, USA

We still see patients and conduct procedures, but we have introduced certain preventative measures. All staff and patients undergo a temperature check, and they are asked about their travel and cough history before entering the building. We continue to administer monthly anti-VEGF injections, and perform surgical procedures, with the exception of those that are fully elective – such as rare instances

of vitreous condensation vitrectomy. All practice staff wear masks – I opt for an N95 mask in the operating room, but also while working in the office, and shopping for groceries or medications. After work, I cook, eat and exercise alone in my apartment.

Anat Loewenstein, Chair, Division of Ophthalmology, Tel Aviv Medical Center; Vice dean, Sackler Faculty of Medicine, Tel Aviv University, Israel

We continue to offer intravitreal injections to our patients but are providing home injections for patients who are reluctant to come to hospital. Retina specialists check every patient's file and determine if injections are necessary. If so, we recommend that the patient comes in for "fast-track" treatment, coming in just for the injections (if they are in the loading phase or treated by capped PRN regimen or fixed regimen). If they are still reluctant to come to the hospital, we visit their homes to perform the injection. We are fully protected at all times, and we keep a sterile setting. This method has been very successful and patients are very grateful

for this approach. With the generosity of Novartis, Israel we got a mobile OCT that we can take to our patients' homes. We also have a separate space that we can open to injections and treatments of patients who don't want to come to the hospital but will come to a remote area.

Florian Kretz, CEO of PVK Precise Vision GmbH, Precise Vision Augenärzte Erlangen and Lead Surgeon at Augentagesklinik Rheine and Greven, Germany

Most of my thoughts at the moment revolve around getting through these difficult times: taking care of my staff, preparing my patients adequately and making it possible for them to visit the clinic safely. Of course, the situation has also affected our research activities; we have had to stop time-consuming examinations or radically decrease their numbers, as the risk to patients and staff is too high. We've had to shorten our employees' working time, but fortunately we haven't had to let anyone go. We're continuously developing the best and safest working practices and procedures to protect our patients and staff as best we can. I have been reading a lot

of news and research around SARS-CoV-2 and COVID-19, looking into potential antiviral therapies and the use of hydroxychloroquine tablets, but I believe that if something effective for dealing with the virus existed, we would already know about it.

That's why I think we need to focus our efforts on keeping everyone safe for now, by finding ways of controlling the spread. We also have to start preparing now for life after the pandemic, when all the patients whose appointments and procedures have been postponed will come back to our practices.

Malik Y. Kabook, The Slater Family Endowed Chair in Ophthalmology, Professor and Chief, Glaucoma Service at the Sue Anschutz-Rodgers Eye Center, The University of Colorado's Department of Ophthalmology, Aurora, USA

Since "COVID-19" entered into our vocabulary a few short weeks ago, many things have changed both in my personal and professional life.

On the work front, we have removed non-urgent-care patients from both the clinic and the operating room. This has resulted in a dramatic reduction in face-to-face patient care and a steep reduction in surgical numbers over the past three weeks. We are still seeing urgent and post-operative patients and we are still performing some glaucoma surgeries for those needing immediate care. However, the majority of our visits now lie in the realm of Virtual Health (VH).

I was part of the internal committee tasked with exploring and implementing workflows around VH, which we greatly expedited by exploring all known options and adapting standard operating procedures that others had created to suit our needs. We trained our entire faculty on using our hospital VH system (EPIC with VidoConnect) and started seeing patients

online just a few days after eliminating face-to-face non-urgent care. Many of our doctors are seeing VH patients from home and becoming more and more active on this platform with each passing day.

I am impressed with how resilient many of my partners have been throughout this entire ordeal. My colleagues have been in good spirits and most have rolled up their sleeves to figure out new workflows, new solutions and novel ways to enhance care for patients, and have been very supportive of each other.

"We're continuously developing the best and safest working practices and procedures to protect our patients and staff as best we can."

On a personal level, my wife (who is a physician practicing family medicine) and I are both at home at all times when not in clinic. We also have a 7-year-old son who is home from school (all schools closed here two weeks ago) so we spend a great deal of time homeschooling him and keeping him entertained. We spend some time outside on walks and riding bikes to stay healthy. This also gives some degree of distraction from the news and the daily grind of seeing patients in clinic or using VH.

We pass time by watching movies, talking to family members around the world using FaceTime, and playing games. The one silver lining in all of this has been the added time we get to spend with each

other, and I feel our bonds strengthening every day.

Despite all of the clinical and personal responsibilities, our startup work also continues in earnest. I continue to have daily video and phone calls with team members and our research, manufacturing and testing has not slowed down. The whole team is committed to meeting our timelines and planning for the day when we can all sit in the same room again and find better ways to treat patients with blinding diseases.

Arthur Cummings, Medical Director, Wellington Eye Clinic, and Consultant Ophthalmologist, Beacon Hospital, Dublin, Ireland

The rate of change is the single most dominant thought in my mind over the last few days. We all live in the modern world that is fast moving, and as physicians and surgeons (and in many cases clinic owners), we are used to making decisions on the fly. Right now, however, these significant decisions are passing by at the fastest pace that I have witnessed outside of a rugby match or a conflict situation. I am thinking that our greatest assets in the near future will be remaining positive, flexible and adaptive, and knowing that the new normal over the next few months is going to be continuous change.

Since the outset of this pandemic, we gradually accepted the fact that we were going to shut down the clinic and stop conducting elective procedures until things were normal enough again and our practice could continue. In high-cost practices, such as cataract and refractive centers, the only way to make ends meet has been to ensure that there is adequate volume.

The term "social distancing" was basically unheard of just a few months ago and now it is on everybody's lips; and the concept is not going to disappear once this particular virus has gone. So, our new clinics will

have to take this into account and arrange to see people with more space between their appointments, creating less traffic in the clinic. I will probably have to alternate between surgical cases and clinic patients all the time, every day. In this way, the entire clinic space would be utilized, but the number of people in each space would be halved. However, with so many people being out of work, it is very likely that the demand for elective surgery is going to drop significantly. More so than ever before, we are going to have to differentiate ourselves from our competition.

At least, this was my plan until last week.

Last week, the Health Service Executive (HSE) in Ireland announced that every single private hospital was being taken over by the public service or HSE. And that means the private practice has basically disappeared overnight. If you treat your private patient's cataract in one month's time, when operating theaters are potentially open again, you will not be paid for it by the health insurer; the only cases being done for the foreseeable future are going to be public service cases. The entire population of Ireland is now being serviced by the public health service. Private practice consultants have been offered temporary locum positions within the HSE for three months or longer, but it may not be in their specialty or in the hospital that they normally work in. Should you decide not to participate in the locum opportunity, it may appear as though you are self-serving and don't care about the community. Should you decide to take on the locum position, you now do not have enough time to work on your business plan to survive this downtime for you and your (often numerous) staff members. In practice, it is Hobson's choice. Only time will tell whether you made the right call or not. It's a decision that one must make quickly, and then move on with conviction.

We all know that this is temporary, and we know a lot more about the anticipated

recovery than we did with the financial crash of 2008. We are going to flatten the curve and then – once we come out of the first hit from the virus – we will have new waves of people being infected, but it will be far less damaging than the current episode. My fear is that COVID-19 will have a little brother called COVID-20 next year and, until we get a vaccine in large-enough volumes, we are going to be managing our businesses and practices in a COVID environment. In the meantime, we may find ourselves with a changed mindset about the things that are really important to us; we may discover how much people really mean to us, and that health is truly our greatest asset.

Meanwhile, all we can do is believe in the future and do whatever we can to make it as bright as possible.

Sheraz Daya, Medical Director, Centre for Sight, UK

These are truly unusual times. The rapidity and suddenness with which events have taken place – along with day-to-day status changes of each nation – point to one word: unprecedented. The same word describes the level of future uncertainty. We've all had to think on our feet, learning to deal with issues as they come along.

The impact on my own practice has been devastating, with almost no revenue coming in over the last two weeks, with a slowdown in the week prior to the formal "lockdown." With two surgical sites and an additional satellite site (in the midst of a build-out and relocation), we have had to act very quickly.

There are three main areas that we considered: our patients, our staff, and business continuity.

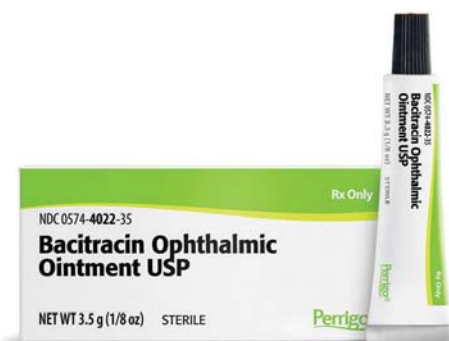I. Our patients. The primary concern, when dealing with elderly patients in particular, has been to avoid putting them in a situation of compromise, balancing their

"We are currently putting in place a process for telemedicine for our existing and new patients who wish to be "seen," with a clear understanding that this type of consultation does not replace a face-to-face appointment and direct examination with appropriate investigations.."

increased risk of contracting an infection with the severity of their eye problems. We made the decision very early to formally shut down; at the same time, many patients were sensibly canceling their appointments. We needed to schedule a surgical session to accommodate two corneal transplants, as well as several patients who came for treatment from overseas. The transplants were performed successfully, and bilateral sequential cataract surgery was performed on cataract patients on the final surgical list. Patients were seen the next day, using face masks and eye protection, with a complete alcohol clean-up of all points of contact between them. Following the

Look Who's Back

Bacitracin Ophthalmic Ointment USP



www.BacitracinRx.com

Perrigo

their salary (including national insurance and pension contributions) up to £2500 per month. This has been a tremendous relief as staff salaries are a large component of overhead costs – the case for many similar practices. Suspension of loan and mortgage payments has also been negotiated with our supportive bankers, further reducing cash burn and helping survival. Nevertheless, there are still considerable outgoing costs, many of which will have to be absorbed with unquestionable impact on working capital.

When I think about the future, I have no doubt that life is going to change at least for the next two years until reliable tests are available and a vaccine has been developed or if we have indeed developed the desired “herd immunity.” Immediate changes are probably going to include acceptance of telemedicine, particularly for vulnerable elderly patients. I expect there will be (and I look forward to) even more collaboration with optometric sources of referral, with investigations and evaluations taking place at local optometric practices with follow-up contact by ophthalmologists. We’ve developed a portal that will help the process – and it’s ready for roll-out. There will be more bilateral sequential cataract surgery and one-stop cataract surgery with patients being evaluated and treated on the same day. This will require good processes for prior counseling and consent, which many practices (including ours) already have in place. We will undoubtedly face more challenges, but we are certainly looking forward to getting back to work. I am hopeful that readily available – and reliable – antibody and PCR testing will be a game-changer that permits many (perhaps with “COVID-19 Immune identity cards”) to begin their journey towards “the new normal.”

If you'd like to let us know how the COVID-19 pandemic has affected your life and work, please email aleksandra.jones@texerepublishing.com

shutdown, we have continued to see a few emergency patients and acute follow-ups, and performed bilateral cataract surgery in one patient with impending angle closure and high pressures.

We are currently putting in place a process for telemedicine for our existing and new patients who wish to be “seen,” with a clear understanding that this type of consultation does not replace a face-to-face appointment and direct examination with appropriate investigations.

II. Our staff. Safety and well-being of staff was addressed by the provision of N95 masks, along with eye protection, prior to the lockdown. We also designed and manufactured Perspex shields for installation on our slit lamps, YAG lasers, and ophthalmic investigative devices, so all technicians and ophthalmologists evaluating patients were protected. As there was a decrease in activity, most clinical staff stayed at home and we conducted trials of administrative staff working remotely. We implemented telephone redirection, establishment of virtual private networks (VPNs), and conducted meetings via Zoom. We were essentially ready by the time the formal lockdown was announced in the UK. Since then, the majority of our staff have been furloughed, with only a skeleton crew available to deal with back-office activities, including patient scheduling, marketing, and management.

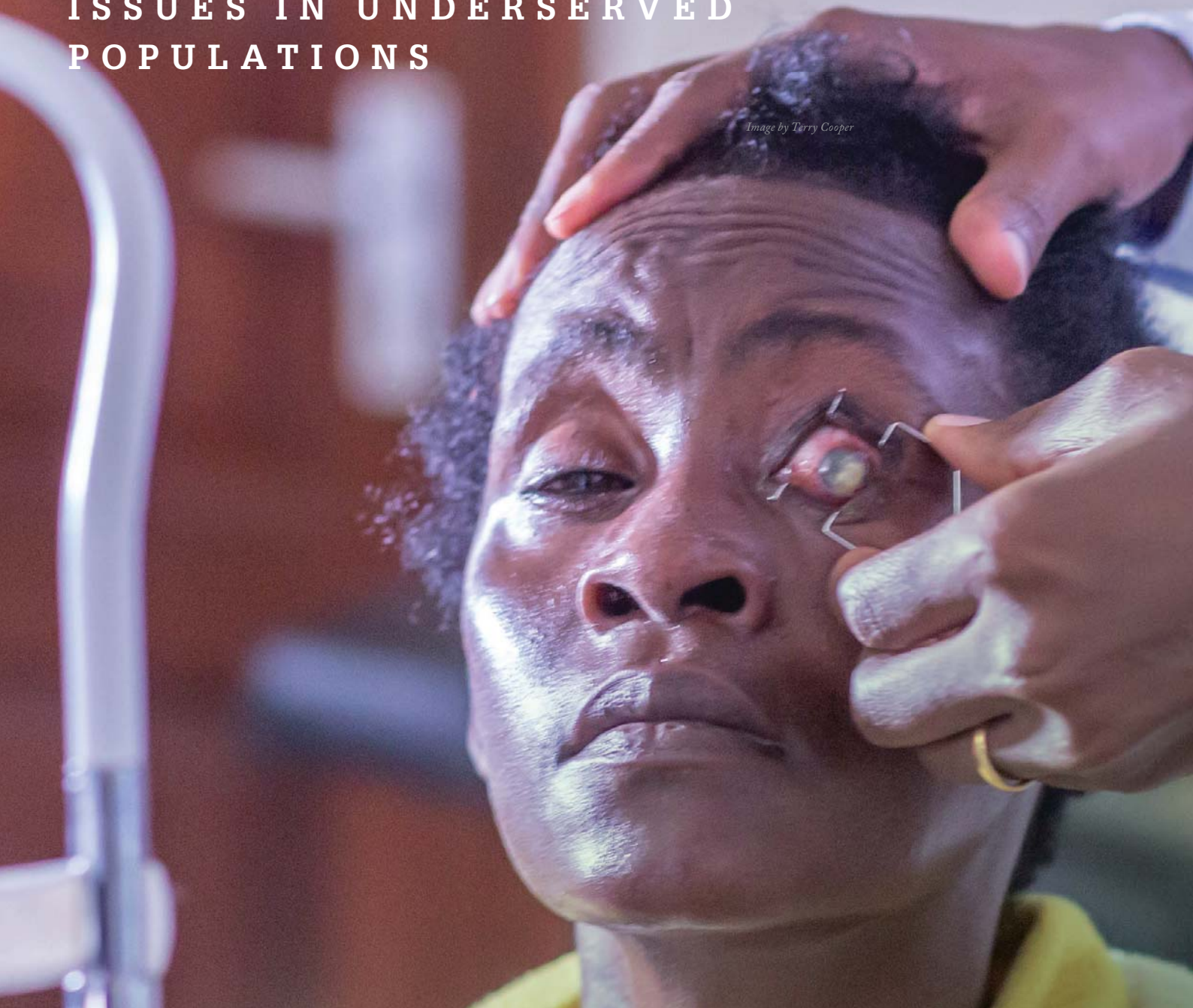I have to say, it has at least been a good time to accomplish much on the “To Do” list of non-clinical processes and projects. Part of the skeleton crew includes clinical staff to triage clinically-related calls, and assist in emergency clinics and surgery. Staff understanding and level of cooperation in helping out with the current situation has been nothing short of impressive and I am very grateful and wish to thank them all.

III. Our business continuity. Addressing this topic has been very challenging. We have been very fortunate in having the UK government announce a grant/subsidy for all furloughed workers to 80 percent of

FURTHER A FIELD

OVERCOMING EYE CARE
ISSUES IN UNDERSERVED
POPULATIONS

Image by Terry Cooper





Making Life

A LITTLE BIT SWEETER

Eliminating infectious diseases that lead to blindness in Africa – an eye-opening view from the frontlines



WITH SIMON BUSH, DIRECTOR OF NEGLECTED TROPICAL DISEASES, SIGHTSAVERS

The impact that neglected tropical diseases can have on communities really hit home for me in 1999. At the time, I was the Regional Director at Sightsavers for West Africa. I went on a field trip to Mali, where I traveled to a village a few hours outside of Bamako. Half of the village's population was blind due to onchocerciasis – otherwise known as River Blindness.

River blindness is caused by a parasitic worm (*Onchocerca volvulus*), which is transmitted by bites from infected blackflies that live by rivers and streams. In the body, the worms produce embryonic larvae that migrate to the skin and eyes. Skin changes are a common symptom, but it's also possible for people to develop eye lesions that can lead to permanent blindness.

Sightsavers has been working with neglected tropical diseases for years, particularly those that cause blindness, like onchocerciasis and trachoma, but reading about these diseases and seeing the impact first-hand is very different. I was particularly shocked by the number of young people who were affected by the disease, including children. In this particular village, many able-bodied men and women were affected – and, as a result, the community was unable to farm.

There is no vaccine or preventative medicine for river blindness, but there is a treatment (ivermectin). At the time, treatment had been rolled out in numerous areas thanks to donations from Merck, but this particular village had missed out – despite the fact that nearby villages were being treated. It made me realize how important total elimination is. It's not enough to help some villages – patients everywhere need access to medicine.

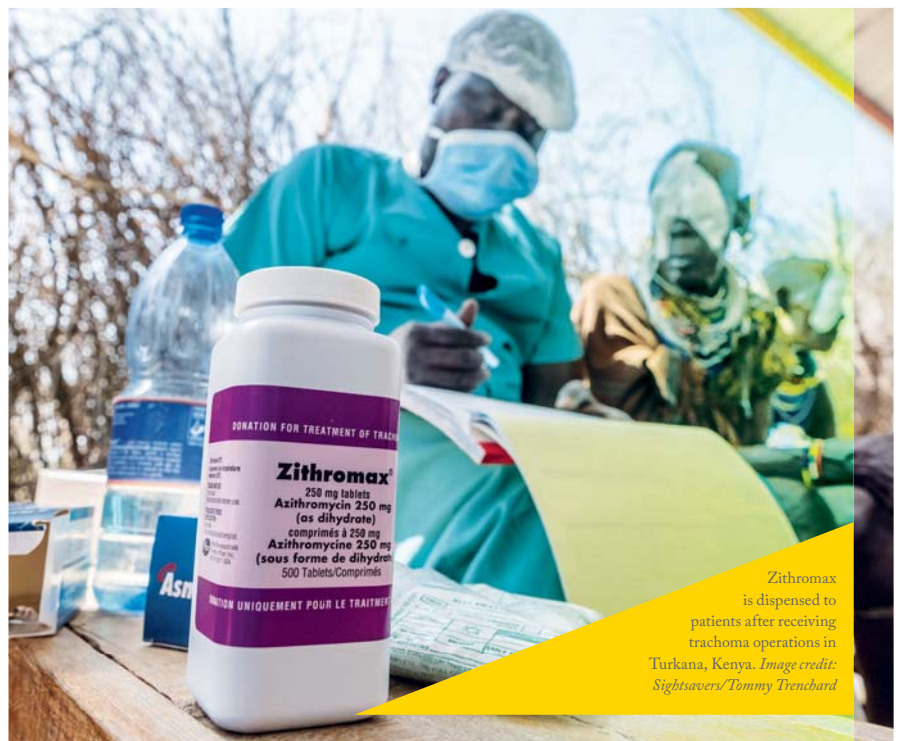



Samer Bahar Mikhael takes Zithromax as part of a mass drug administration to combat trachoma near Matay, Minya Egypt. Image credit: Sightsavers/Sima Diab



A teenage girl takes treatment as part of mass drug administration to combat trachoma in Naandi, Ezo in South Sudan. Image credit: MENTOR/Olivia Wetherill.



Zithromax is dispensed to patients after receiving trachoma operations in Turkana, Kenya. Image credit: Sightsavers/Tommy Trenchard



12ml

98

10ml

87

8ml

KEY milestones

Fortunately, we have made progress. In fact, we've hit some incredible milestones since the London Declaration on Neglected Tropical Diseases in 2012, which aspired to control or eradicate certain diseases by 2020. Today, the blinding impact of onchocerciasis has been reduced thanks to mass drug administration programs – and we're even talking about the elimination of disease transmission in a few years' time. According to WHO, around 217.5 million people are at risk of contracting river blindness. Around 20 million people are actively infected; 14.6 million people are affected by the skin disease; and around 1.1 million people are living with blindness or visual loss. Ninety nine percent of those people live in rural Africa. Thanks to the donation program by Merck, nearly 52 million people have been treated globally. In other words, over the years, Sightsavers has helped support the treatment of one in four of all the individuals treated.

But the program could not have happened without the donated drug. Incidentally, ivermectin was one of the first drugs to be donated by a pharma company – and Merck has committed to the donation program for as long as required. In Nigeria last year, transmission of the disease in two large states was interrupted. And that represents a huge success, because Merck and Sightsavers have been treating people in Nigeria since the 1980s. We still need surveillance systems to ensure the disease does not return, but it's an incredible achievement. It also shows how long it takes to make progress and achieve elimination or interruption of transmission.

There have also been major milestones in trachoma – another infectious disease that can cause blindness. It causes roughening of the inner surface of the eyelids, and can lead to enormous pain and blindness. I've visited communities affected by the disease and patients have told me that it is like having sand in your eye; every time you blink, your eye is scratched. A key milestone for this disease was the Global Trachoma mapping project, which was launched in December 2012 and completed in January 2016. It sounds basic, but to achieve elimination, you first have to map out where you need to apply donated drugs and other programs. It was the largest infectious disease mapping program ever undertaken and has really pushed the trachoma elimination program forward.

Pfizer has been donating the antibiotic Zithromax to treat trachoma for around 20 years now through the International Trachoma Initiative (Sightsavers is one of the many partners in this initiative). It's a great example of a public-private partnership. It was first established in 1998 – with Pfizer initially committing to 10 million doses. Today, they've delivered over 897 million doses. And here's another fantastic achievement: in 2018, Ghana became the first sub-Saharan African country to eliminate trachoma.

Donating drugs is a proven approach and is part of the WHO's

SAFE strategy for tackling trachoma – surgery, antibiotics, facial cleanliness, and environmental improvement. Trachoma is still prevalent in 40 countries – and to achieve elimination, these countries are reliant on Pfizer's free antibiotics. Pfizer has extended the donation until 2025. Another amazing statistic: because of the donations and all of the fabulous partners working in trachoma, the WHO announced in 2019 that the people at risk from trachoma had fallen from 1.5 billion people living in trachoma endemic areas to just over 142 million in 2019 – a reduction of 91 percent! And though it may not be the elimination that we had hoped to achieve by 2020, a 91 percent reduction is still an incredible achievement.

IT matters

There is no doubt that the field of neglected tropical diseases is challenging. It's one thing to aim to reduce the incidence of disease, but elimination is incredibly difficult, especially once you've reached over 90 percent of your target population and need to find those last few patients – who may be located in remote areas, or areas of conflict with security risks for aid and healthcare workers. For pharma companies, donating important drugs for years also comes with financial implications. But now, more than ever, it is important that all stakeholders – governments, pharmaceutical companies, charities and community groups – work together to ensure donations are sustainable and delivered safely. We don't just want to control diseases like trachoma and river blindness – we want to eliminate them. When you are aiming for treatment coverage, it doesn't matter if you don't hit your target one year because you can probably catch up the next year, but when you are striving for elimination, you need to consistently hit and exceed your target every year.

Recently in Ghana, where I live, I traveled to some communities where Sightsavers has been distributing drugs for river blindness and lymphatic filariasis. One lady told me that our work makes life sweeter. I've read a lot of case studies about our work and how it empowers workers and communities to increase agricultural production, but when somebody simply tells you that your work makes their life sweeter, it really means something.

In another village, I spoke with the community leaders about blinding trachoma and they simply said, "We don't have that disease anymore."

Without drug donations, we could never have come this far.

For those of you who are removed from direct interaction with the patients afflicted by tropical diseases – for example, policymakers or professionals in pharmaceutical companies or research organizations that develop or donate drugs for neglected tropical diseases – please remember that your work really matters. It is making a huge difference to human lives.

Healing Together


How working with local healers can help avoid vision loss from microbial keratitis

BY SIMON ARUNGA, CLINICAL LECTURER IN OPHTHALMOLOGY AT MBARARA UNIVERSITY OF SCIENCE AND TECHNOLOGY, UGANDA

All doctors will know that there are certain cases that stay with you forever. For me, one such case was a young child from my own home village, where my parents still live. Something fell into the child's eye, and he developed an infection – microbial keratitis. When his parents realized, they took him to a village clinic, where the young patient was given medication. The parents only brought the child to our specialized eye hospital when they became aware that the medicine wasn't working. I knew immediately it was too late to save the eye – the infected cornea had practically melted away. I had to deliver the bad news to the parents, whom I had known from a young age, all the while knowing that the outcome would have been very different if they had come to me earlier. We had to remove the child's eye, which is a difficult procedure in itself, all the time thinking of the impact this disfiguration would have on his education, future career, and other prospects.

I wanted to help find solutions to help stop more children and adults losing eyes to infection. After my ophthalmology residency, I started a collaboration with my professor, Matthew Burton, at the London School of Hygiene and Tropical Medicine to help us understand the epidemiology of the disease, the underlying risk factors and causes, and how to prevent blindness. We have been working on the project for the last three years, treating patients from south-western Uganda who come to us with microbial keratitis.

One of the things we are really interested in is the patients' journey: we are keen to know what happens between the time the person gets the first symptoms and the time they visit our eye hospital. It is important because microbial keratitis is what I call a "time disease." If someone gets this condition, they should start effective treatment within 72 hours in order to have a good



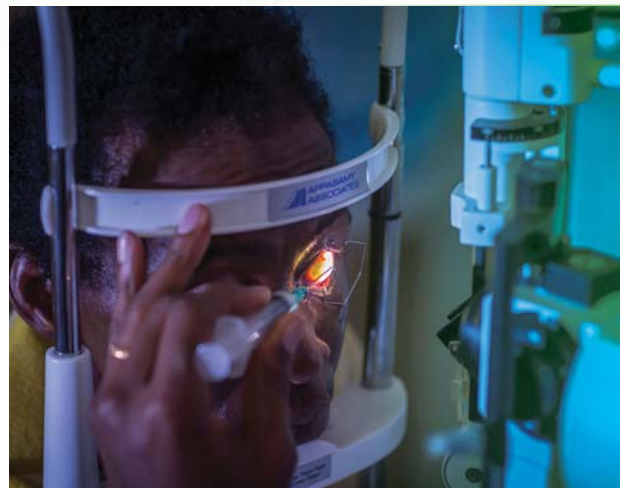
Simon Arunga takes a detailed photograph of a patient presenting at his clinic with a sore left eye. It shows obvious signs of a potentially serious infection that could lead to permanent blindness if left untreated. All images were taken by Terry Cooper.



Arunga spreads some of the sample on agar in a petri dish, which will allow the bacteria to multiply before carrying out further tests. The patient was found to be suffering from a serious infection and treatment was started immediately.



Arunga takes a sample from the front of the patient's eye in order to carry out diagnostic tests. These include looking at any bacteria under a microscope, preparing a culture, and then testing the sensitivity of the bacteria to see which antibiotic would be most effective.



A traditional healer from Bugamba near Mbarara demonstrates how he squeezes the leaf of an aloe vera plant to release its sap. He then produces an ointment which he uses to treat a variety of skin conditions.



Traditional healer Kaperi shows a leaf from an aloe vera plant. He is very well respected in his community, and represents a dilemma: trying to convince patients that traditional healers may not be able to help with more serious conditions.

OUR TREATMENT PROTOCOL

*for patients with
microbial keratitis*

Affected patients usually experience pain and a foreign body sensation in the eye, as well as redness and excessive tear production. It is sometimes caused by an object falling into the eye or an injury. Our first step is to screen all patients for HIV and diabetes, since we found that almost 40 percent of HIV-positive patients did not know they were infected before coming to us with an ophthalmic issue. We then conduct an ocular examination using a torch and a slit lamp, and document the findings.

Before checking patients' vision, we

take photographs of the front of the eye to document clinical findings digitally. Following that, we apply anesthetic drops and take a sample from the cornea at the slit lamp or under an operating microscope if the patient is anxious. We use some samples for microscopy, some as culture, and some as genetic PCR material.

We are fortunate to have a laboratory microscope that helps us to quickly determine if someone has been infected by fungi or bacteria – that is critical when deciding on the initial treatment. We send the rest of the samples to the main microbiology lab, where they are processed, and we get the results back in two to three days. By that time, the patient will have already started initial treatment. Depending on the severity of the condition, some patients can be treated at home, or if the infection is severe, they are admitted

to hospital for close monitoring.

In the first week, the treatment is given hourly, day and night, until the patient responds to medication. On average, patients with fungal keratitis are treated for 8–10 weeks, and patients with bacterial keratitis require a much shorter treatment regime. If a patient does not respond to the treatment, we amend it depending on the culture and the sensitivity results we receive from the lab.

If there is a perforation, we sometimes apply glue and use a contact lens, but we mostly use a conjunctival flap, and occasionally perform an ultrasound to check if the infection has extended to the deeper layers of the eye. If the eye needs to be removed, we offer the patient counselling. We also work with a trained oculist – a technician able to fit artificial eyes. We discharge patients from our care after three months, following control appointments.

outcome. However, we found that it usually took patients two weeks or longer to see an eye care professional. By the time they did, for most of them it was too late to save their vision, or even their eyes.

We found that the majority – six out of 10 – of our patients used traditional eye medicine before coming to see us. This was not surprising, as in Uganda traditional treatments are a widely used alternative to conventional medicine. We discovered that patients who used traditional eye care methods came to us much later, and their outcomes were much worse, compared with patients who did not use alternative methods; a much larger proportion of the first group became blind, or lost their eyes.

Traditional medicines are commonly contaminated and contain microorganisms that can damage the eye. A pre-existing eye condition, such as an injury (common in farmers or gardeners), corneal scar or local infection around the eyelids or the eye drainage system, gives microorganisms easy access to the eye. Also, conditions such as HIV or diabetes, or applying steroids to the eye, reduce the immune system's natural ability to fight off an infection.

TRADITIONAL *trouble*

Ideally, we would simply like to encourage people not to use traditional eye medicine, but achieving behavioral change is extremely difficult, especially when it results from deep-rooted

beliefs. In the local language, microbial keratitis is described as a “storm” – a destructive force that people believe only traditional medicine is capable of curing. Community elders and traditional healers – respected members of the community – tend to encourage this viewpoint. We decided to work on “sensitization messages,” and have been fortunate to be working with Terry Cooper, an award-winning photojournalist, to develop audio-visual messages focusing on the experiences of patients who had used traditional medicine in eye care. We record their messages and distribute them in local communities. Hearing messages from their peers is a lot more effective for people than listening to a “white coat” physician, and they begin to realize the danger and the extent of damage that traditional methods can cause.

Telling traditional healers that their ways don't work is proving to be even more controversial, but with clear evidence and real case studies it is possible. It would not be wise to antagonize healers, so we need to find a way to bring them on board. There is a precedent to our work: Uganda has a history of HIV pandemic, and one of the ways it was combated was through health workers and healers working together. The umbrella body for traditional healers of Uganda (THETA) worked with healthcare professionals, and made changes to their practice, for instance, not using the same knife for different patients. We hope that we can emulate this important work in eye care, and that this way of getting our message across to communities will work to the benefit of our patients.

In the Same Boat

“Oftalmologia humanitaria” – my experience on an expedition to prevent sight loss in a remote region of the Amazon

BY JOHANNA WIEDEMANN, OPHTHALMOLOGIST
AT THE DEPARTMENT OF OPHTHALMOLOGY,
UNIVERSITY OF COLOGNE, GERMANY

In March 2020, I joined a group of highly trained surgeons and select members of the medical community – mainly ophthalmologists – on an expedition through the Amazon. The aim: to restore sight and prevent blindness. The Instituto da Visão-IPEPO from São Paulo, Brazil, provides cataract surgical services, free glasses, and tertiary eye care to cover a population of over two million people in metropolitan São Paulo, the Amazon, and beyond, with the use of telemedicine and other innovative technologies.

The project “Oftalmologia humanitaria” was founded by Rubens Belfort Jr., Head Professor of Ophthalmology at the Federal University of São Paulo. Belfort, along with Jacob Moyses Cohen, Professor of Ophthalmology at Federal University of Amazonas in Manaus, Brazil, usually organize two or three expeditions a year, each time to a different place in the Amazon – typically, supported by the Brazilian navy, and the ophthalmic industry. Notably, the project received the 2019 Antonio Champalimaud Vision Award, which has the support of The Right to Sight – an initiative in collaboration with the World Health Organization and the International Agency for the Prevention of Blindness.

The single greatest cause of blindness in developing countries or remote locations with little to no access to medical care is cataract. In places with high UV radiation, pterygium also has a huge impact on decreasing vision. Uncorrected refractive error, including presbyopia, is also major cause of sight deterioration. And so, during our expedition through the Amazon the goal was to perform cataract and pterygium surgery, use telemedicine to check for glaucoma by evaluation of the papilla, and distribute glasses. I was told that the surgical program worked in three steps. The first step: preselection of patients by the residents at the Cohen clinic in Manaus; the second step: the surgery itself; and then, some days later,



Burnier and
Wiedemann in the
operating room in Urucara,
Amazon state.



we would arrange another visit – the third step – to check for postoperative complications, which would be treated in Manaus, if necessary. The Cohen clinic is operated by Jacob Cohen and his son Marcos Cohen. Marcos, a highly experienced surgeon, taught me a lot, mainly in the field of pterygium surgery.

The mission was only a short one – lasting four days – so we used a smaller boat, without the support of the navy, to travel to Urucara and Parintins. Parintins is a municipality in the far east of the Amazonas state in Brazil. The city is located on Tupinambarana Island on the Amazon River, and the population of the entire municipality is around 114,273. Urucara is much smaller. Both places have small hospitals, but no ophthalmology services, and the 16-hour boat journey to the large hospitals in Manaus is not affordable for the majority of the population.

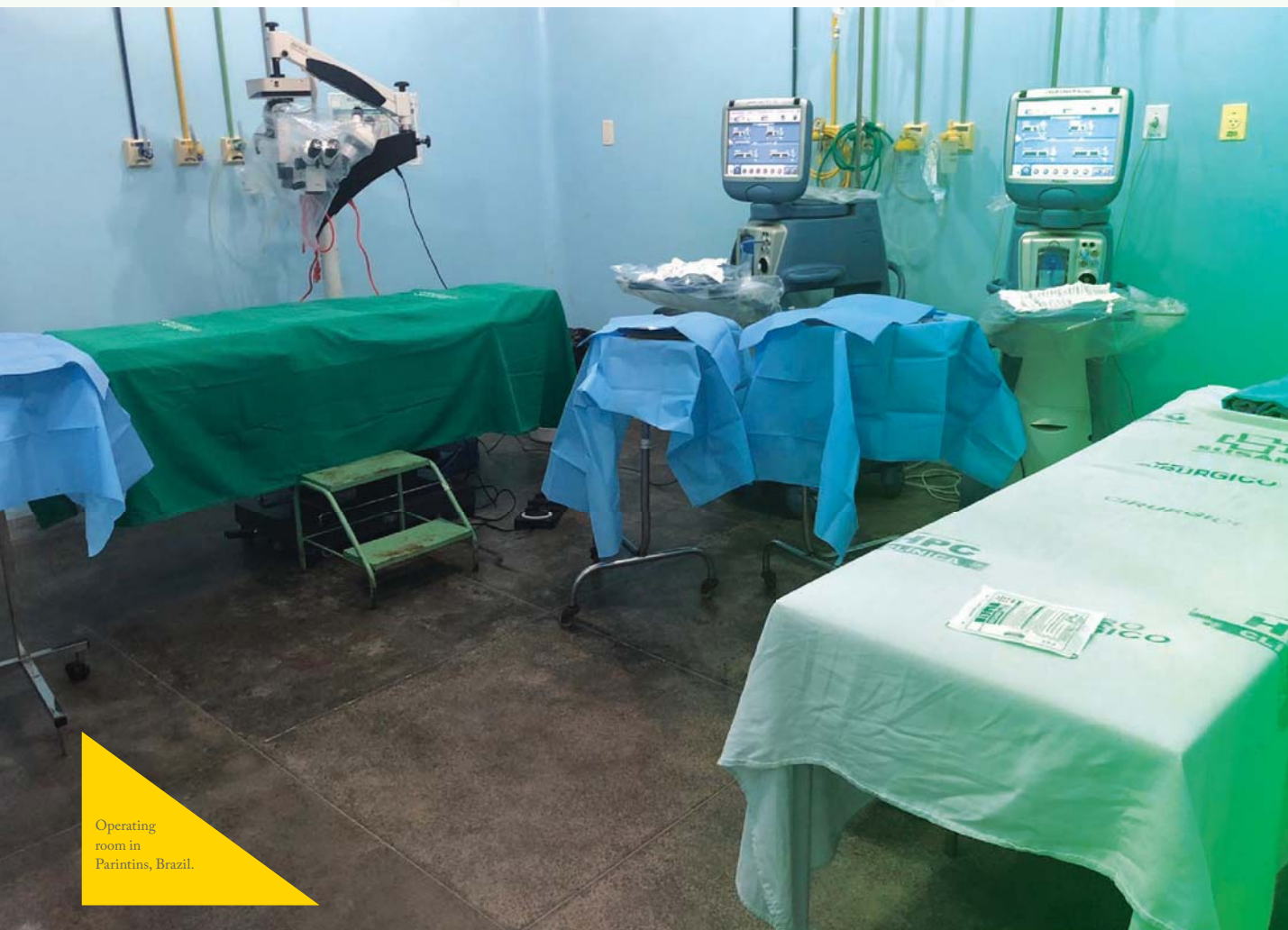The trip started at the international São Paulo Guarulhos airport. I was surprised not to see any locals at the gate five minutes before boarding time. But I quickly learned some cultural differences: in Germany time might be measured in minutes, in Brazil it is hours, but in the Amazon, it's days! After a four-hour flight we arrived in Manaus, the capital of Amazonas – and the only city in the world with two million inhabitants that can be reached only by airplane or boat. We boarded our boat, the D. Luna, and sailed through the night; we were supposed to arrive at our first stop and start surgery the very next morning at 7am. During that first evening, I was introduced to the crew and the team, which included highly honored members of the ophthalmological community, such as Rubens Belfort and Alfred Sommer, a professor of epidemiology and ophthalmology, and former dean of the Johns Hopkins Bloomberg School of Public Health, who dedicated his life to blindness prevention strategies, child survival, and public health. Also on board was Miguel Burnier, a professor of ophthalmology, pathology and oncology at McGill University in Canada and President of the PAAO (Panamerican Association of Ophthalmology), who was an inspiring teacher.

My bunkmates were two medical students, Laeticia Ettinger and Laura Nishimura, and Barbara Clemente, one of the younger surgeons, who has since become a great friend and teacher; she had just finished her surgical fellowship with Belfort. The four of us occupied two berths, so we were forced to get to know each other quickly; luckily, we got along really well.

We arrived at Urucara at noon, welcomed by the city mayor, and began to set up the equipment for surgery. We brought boxes containing the IOLs, reading glasses, surgical material, and phaco machines. Patients had been waiting for us patiently since 4am, but there were no complaints, just smiles and words



The D. Luna next to the bigger navy boat from a previous expedition.



of gratitude. That day, we performed around 50 surgeries, finishing around 10pm. All surgeries were supervised by the anesthesiology team members: Lenilson Moreira and Gustavo Saraiva. All patients received an IV-free, sublingual sedation, and topical – and if necessary peribulbar – anesthesia. After the first day we had to pack everything up again, and we sailed to Parintins, where we arrived the next morning. We spent two days there, and performed 100 cataract procedures.

The surgical team included four surgeons: Lincoln Freitas, Fernando Drudi, Marcos Cohen, and Barbara Clemente, as well as two technicians. I watched numerous surgeries over a couple of days, and Lincoln Freitas devoted a day to teaching me how to perform surgery step by step. He has a vast experience in anterior segment surgery, but he is also an incredibly calm and patient teacher, and he taught me the 12

steps of cataract surgery back to front, as every potential mistake has an impact on the surgery, and makes it more difficult. We started with the removal of Healon from the anterior chamber after IOL implantation, and finished with capsulorrhexis.

Operating conditions in the Amazon were (unsurprisingly) very different to the hospitals I had worked in, but it was amazing to see that it is possible to practice responsible medicine using simple means. Such a working environment also calls for creativity: we had to decide how to sterilize materials or where to hang an IV.

What struck me the most were the interactions between medical staff and patients: everyone talked to each other in a very warm, heartfelt way. We felt united under a common cause.



In Practice

*Surgical Procedures
Diagnosis
New Drugs*

28–31

When Complications Strike
Sumitra Khandelwal's no-nonsense guide to tackling complex cataract cases – triggered by pre-existing conditions or the surgeon – at the operating table

32–34

Wait, Treat, Repeat?
With DME remaining a major cause of vision loss, it is essential that ophthalmologists know how to manage it in the most effective way, says Rod McNeil

35–37

Tackling COVID-19 with Telemedicine
With the pandemic putting frontline health workers under mounting pressure, is it possible for ophthalmologists to safely see patients? Dawn Sim, Peter Thomas, and Chris Canning discuss

38–39

The LASIK Evolution
Better aberrometry measurements and refined flap parameters have continuously improved LASIK results – but there is still work to be done, argues Kerry Assil

When Complications Strike

A guide to tackling complex cataract cases – triggered by pre-existing conditions or the surgeon – at the operating table

By Sumitra Khandekwal

As surgeons, we do our best to avoid complications. But no matter how experienced we are, complications do arise. The source could be a patient's pre-existing condition or (whether we like to admit it or not) because of the surgeon. We must remember that each complicated case presents an opportunity for us to learn and improve, so it's important that we understand the precise nature of the problem – and how to best manage it.

Here, I discuss a number of complex cases that any cataract surgeon might encounter at the operating table, and I offer my thoughts on how they could be handled.

When pre-existing conditions are the source...

Visibility

There are certain conditions that can meaningfully obscure the view at the slit lamp when compared with a microscope. When a patient is lying flat, the diffuse lighting of a microscope can make any corneal opacity, haze, or other pathology more visible. To get the best possible view, it is essential to adjust focus and coaxial lighting; decreasing oblique light may also help. Fortunately, newer microscopes limit the need for adjustment – in particular, those with red reflex technology. In some cases, however, we


need more than the latest tech.


A patient with a vitreous hemorrhage, for example, lacks red reflex and as such, visibility under the scope is still poor. In those cases, I use a cell stain (trypan blue) during anterior capsulotomy. If a surgeon thinks they might need a stain, I would recommend that you use it without hesitating. The only caveat is if the patient also has loose zonules; the stain could go to the back of the eye if it's overused (a problem that can be avoided by using a little disperse viscoelastic at the periphery).

Another option when visibility is poor is to use a fragmentation technique that limits the need for a red reflex. I still opt for the surgical microscope with red reflex technology in these cases because, even in eyes with dense vitreous heme or no red reflex, it still allows me to see the metallic reflex of the lens fragmentation device as it breaks the lens into four to six quadrants before phaco.

Density

In the past, dense lenses were not always considered for extracapsular extraction, but thanks to newer phaco platforms, almost any cataract can be broken up using ultrasound technology. Optimization of the density settings is key for fragmentation efficiency with modern platforms; even with the best technology, some cases require a lot of energy to break the lens pieces. In addition, very dense cataracts often have a fibrotic leathery plate that is nearly impossible to crack using standard techniques. Femtosecond lasers can assist in these cases, although the settings may need to be changed to allow for penetration of the deep plate. Ultimately, we have options available to us when working with dense lenses, which should allow us to adequately fragment without causing complications, such as a wound burn or posterior capsular tear.





Zonulopathy

Zonulopathy can be both pre-existing or iatrogenic. Risk factors include trauma, pseudoexfoliation, genetic syndromes, high myopia, and dense lenses. Any prior act of anterior chamber shallowing, such as surgery, vitrectomy, intravitreal injections, or angle closure could also cause zonules to weaken. Although phacodonesis is often visible at the slit lamp, some cases are not apparent until surgery has begun. Certain techniques can help prevent further weakening of the zonules, even when discovered at the operating table. A horizontal chopping technique, or a lens fragmentation device, can help the surgeon adopt an outside-to-in motion instead of the inside-to-out motion used during the divide-and-conquer technique that could exacerbate weakness. Lowering the bottle height or intraocular pressure of the phaco machine can also avoid over-deepening of the chamber. In addition,

using gentle, slow maneuvers is key – so too is having tools, such as capsular retractors, to help prevent the lens from falling back. One consideration is to flip the lens out of the bag if it appears to be falling posterior, and working anterior to the iris plane, taking care to avoid endothelial damage.

After phaco, it is necessary to actually address the loose zonules. I would recommend considering less commonly used technologies to insert the IOL, such as capsular tension rings. Even though they may present some additional challenges to standard inserters, they are a better option in loose zonule cases. The rings are made in several sizes that are dependent on white-to-white to axial length, and their placement redistributes the applied force to the entire circumference of the bag by stretching it taught. However, once placed, removal of the nucleus and cortical material might be more difficult,

so the timing of their use is absolutely crucial. If this route is taken, additional tool, such as a capsular tension segment, are needed.

When the surgeon is the source...

Inexperience

There are many articles in peer-reviewed literature about the cataract surgery learning curve. Though surgical complications can occur under the care of any surgeon, the rate substantially reduces as experience expands; one study showed a nearly 50 percent decrease in the rate of posterior capsule tear and/or vitreous loss after the first 60 cases (1), while another has suggested an improvement after 60–90 cases (2). The Accreditation Council for Graduate Medical Education has set 80–100 cases as the minimum requirement for cataract surgery to graduate from residency. At that rate, not only do complication rates decrease,

“Posterior capsule tears can also occur at any time during nuclear fragmentation, but there are three points during surgery when I have most commonly observed residents encounter these issues.”

but surgeons’ operative time continues to decrease as well.

Tears

Anterior capsule tears are rare but they can happen during surgery. One tactic to minimize occurrence is effective patient sedation; unsurprisingly, movement during a capsulotomy increases the chances of a tear. There are cases when an intumescent lens could also bring about a tear because of the added pressure that it exerts within the capsular bag. If I encountered this complication, I would decompress with a needle, use a heavy viscoelastic, and begin with a smaller capsulotomy than usual to avoid an enlargement of the capsulotomy in the middle.

Posterior capsule tears can also occur at any time during nuclear fragmentation, but there are three points during surgery

when I have most commonly observed residents encounter these issues. The first is during the groove in a divide and conquer case; grooving too deeply (especially on the part of the lens 180 degrees from the wound) can create a tear. The second is when the surgeon is removing the first lens piece and instead of occluding during emulsification, they fully remove it. Understanding the phaco machine and whether it is peristaltic- or vacuum-based as well as how to efficiently capture pieces is key to preventing this error. The third is when the surgeon is emulsifying the last piece, which is to say when there is no nucleus to protect the posterior capsule from the phaco handpiece. Keeping the chamber formed without shallowing and avoiding surge can help avoid this complication.

If a posterior capsule tear does occur, a surgeon’s first instinct should be to go to foot position 1 (irrigation only) and then insert a dispersive viscoelastic without shallowing the chamber. The ability to keep the eye inflated with the dominant hand, while inserting the viscoelastic with the non-dominant hand, is not always easy, and I encourage trainees to practice the maneuver. Once the chamber is filled, the phaco handpiece can be removed and a decision made on the next steps.

Zonulopathy

Iatrogenic zonulopathy can occur at any stage of surgery. Applying too much pressure during lens fragmentation is a common cause among residents; mastering the positioning of instruments is key to avoiding this complication. If there is an area of zonular dehiscence, it is also important to employ techniques that can avoid enlarging or further weakening

the area (as noted earlier). Finally, if there is an area of zonule weakness, it helps to use a dispersive to push back the equator to avoid further complications.


From my experience, zonular damage occurs most frequently during cortical removal, and it’s often created by moving the aspiration handpiece too peripherally, where there is very little cortical material, and quickly trying to aspirate. A type of “snap back” of the material can sometimes be seen in these situations; instead of cortical material flowing into the aspirator, the equator resists the movement. Once an area of zonule weakness is identified, it helps to limit the amount of vacuum and to remove cortical material in a different area. Changing to a bimanual setting can be helpful. When it comes to addressing the area of weakness, gentle movement toward the area of weakness is best. In accordance with the Miyake-Apple technique, the best way to limit zonule dehiscence is to go tangential to the equator rather than pulling perpendicular and centrally.

And Lastly...

Alert discreetly

The most important resource that a surgeon has is their team; in cases of complications, you must find a way to discreetly alert them that the surgical plan has changed, so that they are all aware and ready to assist – all without alarming the patient. If the patient is relaxed and under anesthesia, the surgeon can get through the case without the patient ever knowing there was a complication until it is explained postoperatively. Sometimes it helps to have a code word. For example, when I calmly say,

“let’s open the vitrector,” the whole operating room understands that there’s a complication and everyone – from anesthesia (more sedation, including topical, may be required), to the circulator, to the scrub nurse – is aware and ready to respond.



Tools at the ready

Surgeons must ensure that they have all tools at their disposal to manage complications ahead of every surgery. When complications happen, they happen quickly and the whole operating team needs to be equipped to respond. Understanding the set-up, how the machines operate, and how to troubleshoot are all very important. I have listed some tools and medications that are useful when handling complications in Table 2.

It is also important to have all lens options and formulae available, even during a routine case, not just one-piece IOLs, but also three-piece and scleral fixated lenses. Understanding the lenses – and how to load them – is essential.

Plan for the worst, do your best

The second a complication occurs – whether surgeon-induced or somewhat anticipated – there is a moment of surgeon stress. The key is to have a plan, to manage complications calmly, efficiently using the tools at your disposal. No surgeon wants to encounter complications, but they occur even in the most experienced of hands. Addressing pre-existing conditions, being aware of common surgical pitfalls, and knowing how to manage anything you might encounter will all help ensure a successful outcome for your patients.

Sumitra Khandelwal is an Associate Professor of Ophthalmology at Baylor College of Medicine. She also trains

residents and cornea fellows at the Alkek Eye Center and Michael E. DeBakey Veterans Affairs Medical Center in Houston, Texas, USA.

References

1. Rogers et al., "Impact of a structured surgical curriculum on ophthalmic resident cataract surgery complication rates", *J Cataract Refract Surg*, 35, 1956 (2009). PMID: 19878829.
2. J Randleman et al., "The resident surgeon phacoemulsification learning curve", *Arch Ophthalmol*, 125, 1215 (2007). PMID: 17846361.
3. A Woodfield et al., "Intraoperative phacoemulsification complication rates of second- and third-year ophthalmology residents", *Ophthalmol*, 118, 954 (2011). PMID: 21539981.



Tackling COVID-19 with Telemedicine

With the pandemic putting frontline health workers under mounting pressure, is it possible for ophthalmologists to safely see patients – without putting themselves at risk?

*By Dawn Sim, Peter Thomas,
Chris Canning*

Telemedicine is taking center stage in the current COVID-19 crisis. By mitigating the need for clinicians to be in the same place as patients, we protect patients by keeping them out of the crowded hospital environment, and we protect clinicians by reducing the time they spend in close physical proximity with patients.

Much of the early discussion surrounding COVID-19 in ophthalmology has been about the 34-year-old Wuhan ophthalmologist Li Wenliang, who raised awareness of the risk to eye clinicians in the early outbreak of January 2020, and tragically died. We now understand much more about the disease, in particular about the danger of spread via asymptomatic patients or those presenting with conjunctivitis.

The close physical proximity between patient and clinician during the slit-lamp examination presents an opportunity for disease transmission – particularly if effective use of personal protective equipment and disinfection regimes aren't observed. As our understanding

of the disease continues to accrue – and with increasing strain on healthcare systems – the utility of telemedicine in a predominantly outpatient specialty, such as ophthalmology, needs to be addressed. How can we see our patients safely at a time such as this?

Telemedicine is a useful way to reduce face to face encounters at a time of mandated social distancing and self-isolation. Though no program can be created overnight, by definition, telemedicine is a resource to be shared – and we can harness what is already in place. Here is the practical utility of telemedicine for ophthalmology in the COVID-19 pandemic:

1. The power of virtual triage
“Forward triage” is a recognized strategy for managing healthcare surges – sorting patients for medical treatment on the basis of need before they present physically to a healthcare facility. Any reduction in face-to-face consultations at a time like this will protect patients, doctors, and the wider community. The utility and ambition of forward triage will grow with the increasing need for social distancing and self-isolation.

The key to successful implementation of forward triage is good risk stratification based on a clear required minimum dataset. In ophthalmology,

this will include elements of clinical history, objective measurement (visual acuity, intraocular pressure), and imaging (photographs, OCT, visual fields). Triage protocols may be optimized by automated “smart” decision trees guiding structured data gathering, with or without diagnostic imaging. Big Picture Medical, a

*“Any reduction
in face-to-face
consultations
at a time like this
will protect
patients, doctors,
and the wider
community.”*



cloud-based telemedicine platform linking optometrists in the community to ophthalmologists at Moorfields Eye Hospital, is such an example.

It has previously reduced hospital attendances by more than 50 percent in some clinics, while further risk stratifying those that did need face-to-face review. Last year, there were 7.86 million ophthalmology outpatient attendances in England alone, meaning that there is huge potential for this technology to relieve pressure on eye services in times of greatest strain.

2. Take the slit-lamp out of the equation
Advanced imaging and diagnostic techniques beg the question whether an ophthalmic slit-lamp examination is now needed in all cases. This examination requires the juxtaposition of clinician and patient – closer than that encountered in most face-to-face medical consultations.

Barrier shields may reduce, but will not eliminate, the risk of cross-infection between the two. A critical assessment of the benefits and risks of slit-lamp

examination is now needed in some clinics, such as repeat intravitreal injections and stable glaucoma, might dispense with it altogether.

3. The video eye consultation

The video eye consult is particularly suited for subspecialties, such as minor eye emergencies, oculoplastics and strabismus. Following in the footsteps of tele-dermatology, platforms such as Consultant Connect and Attend Anywhere are increasingly being used in the National Health Service (NHS) in the UK. Patients benefit from more convenient and often earlier access to specialist care. For example, a virtual waiting room system that mimics eye clinics and eases its incorporation into the clinical workflow.

Recently, a collaboration between the NHS Forth Valley and Moorfields Eye Hospital demonstrated the world's first tele-examination of an eye in 4K resolution using 5G broadband, where a video of a slit lamp examination was streamed live between London and a conference in Edinburgh. This represents a turning point in tele-ophthalmology as we were able to deliver detailed video in real time, using readily available equipment.

The system is currently in use by NHS Forth Valley to allow remote examination of patients in community optometry practices and within Moorfields Eye Hospital to allow remote examination by senior on-call doctors.

In the light of COVID-19,

many routine visits to the eye clinic may have to be subdivided to reduce in-person contact; either diagnostic in-person visits (orthoptic assessment, biometry, OCT retinal scan), or video-based pre-surgery consults with the anaesthetist and surgeon. A combination of an in-person visit for OCT and visual fields, for example, and a video consult to discuss the results reduces the number of contacts for clinician and patient – and the time spent in clinic waiting areas.

Many other applications continue to be evaluated in ophthalmology, including post-operative care and monitoring of stable eye conditions, such as thyroid eye disease and diabetic retinopathy.



4. Self-Care


Reassurance and communication with patients who have chronic diseases, such as dry AMD or diabetic macular edema (DME),

may be enhanced with home-monitoring of patient symptoms. Examples include the Alleeye application (Oculocare Ltd), which enables monitoring of visual distortion on a mobile device and mobile phone-based, digitized patient reported outcome measure (PROMs) – both of which permit ophthalmologists to remotely monitor patients on a granular level; we should know how patients are faring daily between hospital appointments.

5. Communication

“Why are you ringing me?”

We live in an age of instant messaging, and yet clinically we still rely on phones, emails and pagers. A move to instant messaging apps allows easier team-based communication, which makes patient handover more robust – especially when





individual team members unexpectedly have to go into isolation. Most of these apps allow photography within the app, and low-cost smartphone slit-lamp adapters (many telescope adapters cost less than \$30) will allow clinical images to be taken using the clinicians' own device, and sent for an instant specialist review. This technology provides a "rough-and-ready" store-and-forward solution at a time when certain critical skill sets might be physically unavailable.

Can't go paperless? Go paperlite!

When it becomes impossible to access a set of paper records, even the briefest digital descriptor of clinical history (for example, scanned PDFs of letters) may facilitate management. Communication failure is a known key factor in patient harm. If clinicians are able to access electronic medical records via remote

connections, eye clinics may still carry on, albeit via telemedicine.

6. Systems developed in a crisis might persist

During a crisis, such as the current COVID-19 outbreak, it is inevitable that hospitals will rush to implement remote management systems that allow them to provide some care to patients unable or unwilling to come to hospital. We are already seeing some relaxation of the usual governance requirements in the UK, where NHSX (a unit responsible for implementing digital technologies to health and social care in the UK) has indicated that clinical need can outweigh usual standards of best practice.

Importantly, the Information Commissioner in the UK "has assured NHSX that she cannot envisage a situation where she would take action

against a health and care professional clearly trying to deliver care." As the crisis passes, however, we are likely to see many of the systems set up to meet short-term need, morphing into long-term solutions.

These new systems should be subject to constant scrutiny to ensure that they develop towards offerings that meet the standards expected during normal times. In this way, the current crisis could transform our healthcare systems towards the remote delivery of care upon which so many national strategies rely.

Dawn Sim is Director of Telemedicine at Moorfields Eye Hospital, Peter Thomas is Director of Digital Innovation at Moorfields Eye Hospital, and Chris Canning is Chief Clinical Informations Officer at Moorfields Eye Hospital, London, UK.

Wait, Treat, Repeat?

A practical guide to managing diabetic macular edema

By Rod McNeil

It is widely known that the global prevalence of diabetes – as well as the complications, deaths, and societal costs associated with it – continue to escalate, with no signs of abating. Unsurprisingly, eye specialists are encountering more patients with diabetic eye disease today than ever before. With diabetic macular edema (DME) remaining a major cause of vision loss, it is essential that all ophthalmologists know how to manage their diabetes patients in the most effective way.

Here are some practical pointers on how to manage DME, based on substantive clinical trial evidence published by the independent body, Diabetic Retinopathy Clinical Research Retina Network (DRCR.net), and key presentations given on the international congress stage.

Start treatment with anti-VEGF therapy

Intravitreal anti-vascular endothelial growth factor (anti-VEGF) therapy is the recommended initial treatment for vision impairment due to DME; it has been shown to provide superior visual and anatomic outcomes compared with laser photocoagulation treatment alone (1, 2, 3, 4). In the DRCR.net Protocol I study, anti-VEGF therapy with prompt laser proved to be no better than anti-VEGF treatment plus deferred laser (2, 3), and as such, laser use should be reserved for those eyes that


show no improvement beyond six months of anti-VEGF therapy.

When to consider first-line aflibercept

Intravitreal aflibercept has shown superiority to ranibizumab and bevacizumab over the first and second year of treatment, respectively, in DME eyes with baseline visual acuity (VA) 20/50 or worse (<69 letters) (1, 5, 6), which makes it the anti-VEGF drug of choice in these patients. Though aflibercept, ranibizumab and

bevacizumab yield similar gains in vision for patients with 20/32 or 20/40 vision (>69 letters) at the start of treatment, according to data, at 12 months, those receiving aflibercept are more likely to improve by three or more lines of vision (≥ 15 letters) from baseline (5). This improvement in vision has been found to be even more pronounced when patients are treated with aflibercept over a two-year period, in comparison with ranibizumab and bevacizumab (6).

Typically begin with six monthly injections





In most DME cases, resolution of edema and VA outcomes continue to improve through six months of consecutive, monthly anti-VEGF injections (2, 5, 7). Patients are unlikely to lose vision if treated intensively at the start and given subsequent injections or focal/grid laser photocoagulation treatments as needed to achieve stability (8).

Choose anti-VEGF over corticosteroids

Given a choice of intravitreal anti-VEGF or corticosteroid treatment, there is stronger data to suggest that more sustained VA improvement can occur with the former. Treatment groups in Protocol I originally managed with laser or triamcinolone plus laser had a gradual improvement in VA after subsequent treatment with ranibizumab, but – whether phakic or pseudophakic at baseline – did not achieve the same long-

term vision improvements as those treated with ranibizumab as first-line therapy (9). Cataract removal in the presence of edema does not always lead to meaningful vision improvement (10).

In cases of persistent DME after six monthly anti-VEGF injections, corticosteroids also have limited benefit, especially in phakic eyes. Results from DRCR.net Protocol U show that adding an intravitreal dexamethasone implant to continued ranibizumab treatment in patients with persistent DME does not improve VA at 24 weeks more than continued anti-VEGF therapy alone, although combination corticosteroid and anti-VEGF treatment is more likely to reduce retinal thickness and raise intraocular pressure (11).

Resume anti-VEGF only if central subfield thickness worsens

Regardless of anti-VEGF treatment, meaningful gains in vision with minimal risk of vision loss over two years have been observed in eyes with persistent DME through 24 weeks in Protocol T (Table 1) (8). It is suggested that anti-VEGF treatment is only resumed if there is worsening of central subfield thickness on OCT or VA until stability is achieved.

Follow the DRCR.net retreatment regimen

By observing the DRCR.net approach to anti-VEGF retreatment, most eyes with DME treated with ranibizumab, and either prompt or deferred laser, will maintain the vision gains achieved at one year through five years, with little additional treatment required after three years (3). Sustained vision improvements have been shown to be maintained in the absence of continued treatment unless worsening, with fewer

than five injections in years three to five compared with a median of nine injections in the first year of Protocol I. At five years, 56 percent of participants in the deferred laser group in this study did not receive laser.

Vision gains absent at month three? Continue treatment

Eyes showing inadequate response at three months may still go on to experience meaningful vision gains with continued anti-VEGF treatment. Though early visual response to anti-VEGF is associated with good long-term vision outcomes (12), there is substantial individual variability among patients with DME. Limited VA response to anti-VEGF therapy (<5-letter gain from baseline) at week 12 does not preclude further meaningful vision improvement (≥ 10 -letter gain) at two years in many eyes with continued treatment (13). Eyes with limited early VA response have been shown to achieve good vision (20/25 to 20/32) at two years. Changes in central subfield thickness account for only a small proportion of the total variation in changes in VA after anti-VEGF treatment for DME through two years (14).

For DME patients with good vision, observation only may be a good strategy

Sometimes, observation alone is sufficient in DME patients with good vision. In the DRCR.net Protocol V study of DME in eyes with VA 20/25 or better, there was no significant difference in vision loss at two years in eyes initially managed with aflibercept, laser photocoagulation or observation with aflibercept only administered if VA worsened (at least a 5-letter VA decrease from baseline to year two was observed in 16, 17 and 19 percent of eyes in each group, respectively) (15). All three management

strategies resulted in a mean VA at two years of 20/20. The proportion of eyes with VA 20/20 or better was significantly greater with aflibercept (77 percent) than observation (66 percent), while the proportion of eyes 20/25 or better was similar in each group (~85 percent).

Rod McNeil is an independent medical journalist.

References

1. U Schmidt-Erfurth et al., "Guidelines for the management of diabetic macular edema by the European Society of Retina Specialists (EURETINA)", *Ophthalmologica*, 237, 185 (2017). PMID: 28423385.
2. Diabetic Retinopathy Clinical Research Network, MJ Elman et al., "Randomized trial evaluating ranibizumab plus prompt or deferred laser or triamcinolone plus prompt laser for diabetic macular edema", *Ophthalmol.*, 117, 1064 (2010). PMID: 20427088.
3. MJ Elman et al., "Intravitreal ranibizumab for diabetic macular edema with prompt versus deferred laser treatment: 5-year randomized trial results", *Ophthalmol.*, 122, 375 (2015). PMID: 25439614.
4. G Virgili et al., "Anti-vascular endothelial growth factor for diabetic macular oedema: a network meta-analysis", *Cochrane Database Syst Rev*, Jun 22, 6:CD007419 (2017). PMID: 28639415.
5. Diabetic Retinopathy Clinical Research Network, JA Wells et al., "Aflibercept, bevacizumab, or ranibizumab for diabetic macular edema", *N Engl J Med*, 372, 1193 (2015). PMID: 25692915.
6. JA Wells et al., "Diabetic Retinopathy Clinical Research Network. Aflibercept, bevacizumab, or ranibizumab for diabetic macular edema: two-year results from a comparative effectiveness randomized clinical trial", *Ophthalmol*, 123, 1351 (2016). PMID: 26935357.
7. F Ziemssen et al., "Initiation of intravitreal aflibercept injection treatment in patients with diabetic macular edema: a review of VIVID-DME and VISTA-DME data", *Int J Retina Vitreous*, 2, 16, eCollection (2016). PMID: 27847634.
8. NM Bressler et al., "Persistent macular thickening following intravitreal aflibercept, bevacizumab, or ranibizumab for central-involved diabetic macular edema with vision impairment: a secondary analysis of a randomized clinical trial", *JAMA Ophthalmol*, 136, 257 (2018). PMID: 29392288.
9. SB Bressler et al., "Five-year outcomes of ranibizumab with prompt or deferred laser versus laser or triamcinolone plus deferred ranibizumab for diabetic macular edema", *Am J Ophthalmol*, 164, 57 (2016). PMID: 26802783.
10. Diabetic Retinopathy Clinical Research Network Authors/Writing Committee, SB Bressler et al., "Pilot study of individuals with diabetic macular edema undergoing cataract surgery", *JAMA Ophthalmol*, 132, 224 (2014). PMID: 24309926.
11. RK Maturi et al., "Effect of adding dexamethasone to continued ranibizumab treatment in patients with persistent diabetic macular edema: a DRCR network phase 2 randomized clinical trial", *JAMA Ophthalmol*, 136, 29 (2018). PMID: 29127949.
12. VH Gonzalez et al., "Early and long-term responses to anti-vascular endothelial growth factor therapy in diabetic macular edema: analysis of Protocol I data", *Am J Ophthalmol*, 172, 72 (2016). PMID: 27644589.
13. NM Bressler et al., "Early response to anti-vascular endothelial growth factor and two-year outcomes among eyes with diabetic macular edema in Protocol T", *Am J Ophthalmol*, 195, 93 (2018). PMID: 30077569.
14. NM Bressler et al., "Association between change in visual acuity and change in central subfield thickness during treatment of diabetic macular edema in participants randomized to aflibercept, bevacizumab, or ranibizumab: a post hoc analysis of the Protocol T randomized clinical trial", *JAMA Ophthalmol*, Jun 27, doi: 10.1001/jamaophthalmol.2019.1963 (2019). [Epub ahead of print]. PMID: 31246237.
15. CW Baker et al., "Effect of initial management with aflibercept vs laser photocoagulation vs observation on vision loss among patients with diabetic macular edema involving the center of the macula and good visual acuity: a randomized clinical trial", *JAMA*, Apr 29, doi: 10.1001/jama.2019.5790 (2019). [Epub ahead of print]. PMID: 31037289.

The LASIK Evolution

Better aberrometry measurements and refined flap parameters have continuously improved LASIK results – but there is still work to be done

By Kerry Assil

Contemporary LASIK is not a single-system procedure. It incorporates three separate technologies – an excimer laser, a femtosecond laser and a wavefront aberrometer – all of which have undergone many innovations over the past 20 years. Explaining to patients how these advanced technologies combine to provide excellent results can be a challenge. While all excimer lasers deliver very precise 193-nm laser pulses, the pulse delivery algorithms and the sophistication of the aberrometry systems that measure the eye and inform the laser are a major component of how we differentiate our results today. Another significant factor is the way in which the flap is designed. I coined the term EAGLE Vision to more intuitively convey to my patients what the iLASIK Technology Suite (Johnson & Johnson Vision), can now deliver for patients. EAGLE Vision stands for Elliptical-flap, Aberrometry-Guided, Laser-Enhanced Vision.

Measurement innovations

We now have the ability to measure the entire ocular micro-zonal refraction with exquisite detail and accuracy, to inform the excimer laser and precisely guide the laser pulse delivery onto a predetermined stromal grid. The wavefront sensor within the iDesign Refractive Studio has a fivefold greater number of lenslets than its predecessor (the WaveScan) did, capturing more than 1,200 spots over a 7.0-mm pupil. When talking to patients

about this improvement, I use the analogy of a high-definition television with more pixels on the same screen. They understand how that improves the image the device is capturing of their eye and translates that level of precision onto their cornea.

In addition to wavefront aberrometry, the iDesign also integrates five other simultaneous measurements, including full-gradient topography, autorefraction, keratometry, corneal diameter and pupillometry. Because all of these are captured on the same fixation axis, they are spatially registered to one another. The addition of topography data in particular helps to reconstruct an exact mathematical representation of the corneal surface. The additional measurements also enable me to further refine the flap shape and diameter customization (see Flap innovations below).


With this device, we can measure scotopic pupils as small as 4.0 mm, and our treatment indications have been expanded to include wavefront-guided PRK, monovision treatments, and a broader range of astigmatism correction than before. I also explain to patients that as the diagnostic elements of the treatment have improved, we are not only able to improve the ablation pattern but to more consistently rule out patients who have a higher risk of ectasia and should not have Lasik, and may instead benefit from PRK, collagen cross linking, or observation. Better measurement means better selection, better treatment and better results.

Flap innovations

Coupled with the gains in treatment planning, I also consider it very important that this platform allows us to customize and flap diameter, parameters –

including hinge location/width, and flap diameter, shape and thickness – further aiding in achieving optimal outcomes. Because the temporal corneal quadrant is by far the most expansive, it enables many ensuing flap design changes (1). Here are the changes in flap architecture I have worked with over the years and believe to have made a big difference in my personal outcomes:

1. *Temporal hinged, elliptical shape*
Elliptical flaps, first developed in collaboration with IntraLase, are 4 to 10 percent longer in the horizontal than the vertical axis, honoring the inherent corneal shape. Elliptical shaped flaps can easily be accommodated by rotating the hinge to the most expansive (temporal) corneal quadrant. Because the pupil is always superonasal, a temporal quadrant-based hinge positions the hinge as far from the pupil center as possible. This spacing ensures a large exposed surface area so that the flap hinge does not interfere with the large-diameter optical zone ablation patterns required for wavefront-guided, topography-refined treatments. In addition to better visual acuity outcomes, we have also observed fewer complaints of early postoperative dysphotopsias since developing these flap patterns. The elliptical flap, coupled with a temporal hinge, also keeps any opaque bubble layer (OBL) farther



away from the pupil, preserves more of the temporal long ciliary nerves (especially when the “pocket” is also deleted), and provides for greater protection in collaboration with the facial bones – since the temporal quadrant is the only one without a surrounding bony prominence – in the unlikely event of perioperative blunt trauma.

2. *Wide hinge*

With the temporal hinge adoption, I have also gone from a 45° hinge angle to a much wider 65°–70° angle, which I believe diminishes dry eye (by preserving more of the ciliary nerve fibers) and also leads to a more tectonically stable flap. My personal experience has been that a more broadly anchored – widely-hinged – flap reduces the incidence of epithelial ingrowth, microstriae and slipped flaps, as it more securely fits back onto the bed with less misalignment that could result in early flap striae. Subtle misalignment could also compromise the benefits of the highly refined ablation pattern. In adopting such an approach, the flap in many cases doesn't even need to be fully reflected to the hinge margin in order to deliver the entire ablation to the exposed stromal bed (due to its horizontal elongation). In such cases, the effective hinge angle becomes even wider than 70°. In our experience, these much wider-hinged flaps have also diminished our observed incidence of dry eye, both subjective (patient-related experience) and objective (reduced epithelial superficial punctate staining or SPK).

3. *Thinner flaps*

Because there is less risk of flap

slippage with a wide hinge, surgeons can also feel more comfortable making thinner femtosecond laser flaps. I routinely make a 95- to 100- μ m flap, and believe that in time, with ever more refinement of femtosecond lasers, we may even challenge the widely held view that 95 μ m is the thinnest desirable flap limit. Thin flaps, if devoid of microstriae, may augment the visual benefits accompanying highly refined ablation patterns, whereas a thick flap can dampen the surface transmission of the exquisitely precise sculpting profile. A thin flap also ensures a thicker residual stromal bed, preserving corneal tectonic stability, reducing ectasia risk and increasing the likelihood of future enhancement candidacy.

Headed in the right direction

Better measurement capabilities and greater flap customization have combined to improve our patient experience. Increasingly, we are seeing patients achieve vision that is close to their true retinal potential. For example, I recently received a message from a Wimbledon champion/patient, exclaiming that his son (also a patient and a rising athlete), was tested at the National Health Center in Holland and observed to now have uncorrected acuity of 20/10 OD, 20/8 OS and 20/8 binocularly following his recent LASIK procedure. Not every patient will achieve 20/8 – or appreciate the titratable impact of vision on performance the way professional athletes do – but cases like this one highlight that we are finally delivering on a promise that for many years was aspirational.

Multiple studies have now shown that custom, wavefront-guided LASIK can frequently achieve even better uncorrected visual acuity after surgery than the best pair of glasses. In my practice, nearly 50 percent of patients are achieving

uncorrected acuity after surgery that is better than their best corrected visual acuity before surgery.

The entire industry may be starting to move in this direction. While the iDesign is still the only system with individualized wavefront analysis and data further refined by corneal surface topography, there are now other systems that inform the laser beyond simple refraction. While these others are primarily using corneal surface topography, some are adding limited population-averaged spherical aberration refinement. The trend for “smarter” lasers looks set to continue.

We also have new procedures such as small-incision lenticule extraction (SMILE). I'm optimistic about SMILE's potential, especially once the lenticules can be made thinner, more superficial and with shaping patterns for correcting all forms of refractive error – not just myopic astigmatism.

I am encouraged that corneal refractive surgery continues to evolve in new and exciting ways that increase the precision and sophistication of what we can offer patients. When new technologies come along, we are tempted to judge our results by our successes. Experienced surgeons, however, learn to judge their results based upon their failures. At present, LASIK as I've described it here is the only way to reliably reach the goal to which I aspire for my patients – not just to throw away their glasses and experience fast visual recovery, but to see significantly better following surgery than they could prior.

Kerry Assil is Medical Director and CEO of Assil Eye Institute in Beverly Hills and Santa Monica, CA, USA. He is a paid consultant to Johnson & Johnson Vision.

References

1. K Assil and T McCall, “Temporal hinge laser in situ keratomileusis: Maximizing treatable stromal bed area”, *J Cataract Refract Surg*, 31, 1139–44 (2005). PMID: 16039487.

SUBSCRIBE TO THE OISTV YOUTUBE CHANNEL

OIS: OPHTHALMOLOGY INNOVATION & INVESTMENT



IN YOUTUBE SEARCH
"OPHTHALMOLOGY INNOVATION"
AND SUBSCRIBE

BE SURE TO TAP THE BELL
FOR UPDATES

GET THE LATEST INTERVIEWS,
COMPANY SHOWCASES &
PANEL DISCUSSIONS

NEVER MISS ANOTHER OPHTHALMOLOGY INNOVATION UPDATE

NextGen

*Research advances
Experimental treatments
Drug/device pipelines*

42–43

Liquid Gold

CHLA researcher Jesse Berry explains how she uncovered a breakthrough biopsy method for retinoblastoma and why it will open the door to a more accurate treatment response

Liquid Gold

CHLA researchers uncover a breakthrough biopsy method for retinoblastoma

By Phoebe Harkin

For Jesse Berry, discovering the suitability of aqueous humor as a biopsy site for retinoblastoma, was “serendipity.” A chance decision led Berry, Associate Director of Ocular Oncology at Children’s Hospital Los Angeles, to analyze the liquid inside a patient’s eye, and find it contained crucial genetic tumor information. The hope? That the novel liquid biopsy could open the door to more accurate diagnosis, more detailed understanding of treatment response, and more reliable prognosis.

We speak to Berry to find out how she made the discovery and why she is, in her words, “forever grateful.”

How did you discover that aqueous humor made a good biopsy site?

There had previously been an agreement that no needle should enter an eye with active retinoblastoma. This is because retinoblastoma, unlike most cancers, cannot be biopsied for risk it can spread outside the eye. However, a safety-enhanced procedure for injecting chemotherapy into the vitreous was introduced in 2012. As part of this procedure, an initial paracentesis with extraction of aqueous humor is performed to lower the overall pressure in the eye. Initially, this biofluid was discarded, but then – while actually throwing it away – there was a moment when I wondered if there was anything in this fluid. Since that moment, there has been an exciting amount of work showing that the fluid harbors DNA, RNA and miRNA which is from the tumor.

How are samples taken?

The aforementioned paracentesis involves

inserting a 32 gauge needle through the cornea, and extracting some of the clear fluid in the front of the eye – fluid that will naturally replenish within one to two hours. So far, the majority of samples are taken during the injection of chemotherapy into the eye; however, given the exciting findings from this research, we can now extract or ‘biopsy’ the aqueous at the point of diagnosis and throughout therapy.

“For the first time ever, we can obtain tumor DNA from the aqueous in eyes that are undergoing treatment.

Previously, the only time tumor DNA was available was if the eye required enucleation.”

What are you hoping to find?

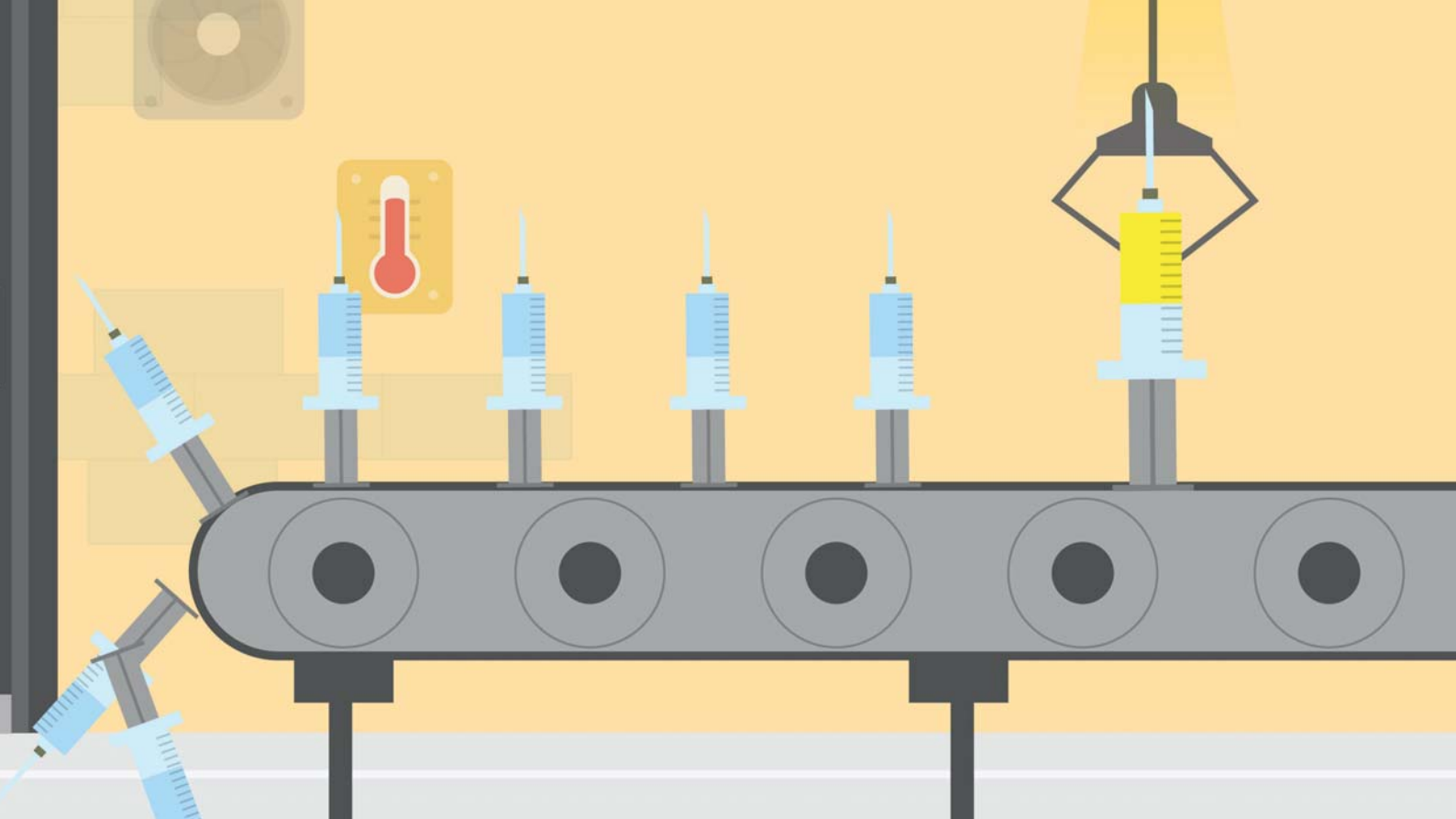
In general, the goal of any biopsy is to look at the tissue for diagnostic confirmation, and then look at molecular markers for prognostic information and, in some cases, treatment targets. Though there are no cells or tissues in the aqueous, we can still consider this a liquid biopsy. In the setting of a liquid biopsy for other cancers, a

biofluid (often blood) is used to look for circulating tumor derived cell-free DNA that can be used for diagnosis to measure treatment response, as a biomarker of relapse and prognosis. Mutations can also be identified for many cancers. We are looking to bring the diagnosis and prognosis of retinoblastoma to a similar molecular level by using the aqueous as our biofluid of choice for this liquid biopsy platform. Specifically, we are identifying RB1 mutations in the aqueous for diagnosis; measuring treatment response by evaluating tumor fractions in the aqueous and their response to therapy; and using cell-free DNA as a biomarker of poor prognosis by identifying gain of chromosome 6p in the aqueous.

What are the benefits and limitations of the aqueous biopsy method?

The main benefit is that – for the first time ever – we can obtain tumor DNA from the aqueous in eyes that are undergoing treatment. Previously, the only time tumor DNA was available was if the eye required enucleation because direct tissue biopsy is strictly contraindicated in retinoblastoma. Now that we can assay the DNA and other biomarkers from the aqueous in eyes undergoing therapy, we can consider using it for diagnosis and even more importantly – at least, to me – prognosis. The limitation, which was addressed in our paper, is that this is still an invasive procedure – much more so than a blood draw would be. It is arguably less invasive than a direct tumor biopsy would be, but it still involves extraction of fluid from the eye. Additionally, though we have not had any complications or issues of tumor spread, it should be stressed that using the aqueous as a liquid biopsy in retinoblastoma eyes remains experimental and should not yet be considered for clinical applications.

One of the main reasons for the blood versus aqueous study is that extraction of aqueous is more



invasive, so if we could as efficiently find the DNA in the blood then we would need to reconsider our goals. In the samples taken, we did not find tumor derived DNA (with a sensitivity of 5 percent tumor fraction) in the blood. However, even if we could find tumor DNA at lower fractions in the blood, there is still a huge benefit to using aqueous: this particular biofluid is specific to each eye. About one third of retinoblastoma patients have tumors in both eyes; thus, if you found biomarkers in the blood you would not know to which eye it applied. Certainly, that question is not a big deal when it comes to diagnosis, but it's extremely relevant when you discuss prognosis, which should be for each eye.

Can the aqueous humor predict treatment success?

We identified a novel biomarker in the aqueous which is an increased copy number of a part of chromosome 6 – “gain of 6p.” Though this chromosomal alteration was known to occur in retinoblastoma, all previous studies on gain of 6p were from tumor tissue of eyes that had been enucleated (as there was no other way to

obtain tumor DNA in vivo). However, we can now look at the DNA and the chromosome profiles from eyes actively undergoing therapy – and from eyes that have been enucleated. What we found is that if increased copies of 6p were found in the aqueous, there was a much higher risk of that eye responding poorly to therapy and ultimately requiring enucleation (2).

Could the aqueous humor be used to identify other illnesses?

Yes – and I think the list will grow. Aqueous is already “biopsied” in the setting of certain infections, and PCR can be done on the fluid to identify viruses, such as HSV. It may be possible to use the aqueous instead of direct or vitreous biopsy for other cancers or to evaluate genetic diseases in the eye in time. There is a great deal of potential here – but, aside from infections, nothing used clinically right now.

How does the aqueous humor differ from eye to eye?

Some of this detail will be in a future publication, but one fascinating discovery

comes from our evaluation of aqueous from children who have retinoblastoma in both eyes. These children have the same initiating retinoblastoma tumor suppressor mutation; however, the pattern of chromosomal changes in each eye is different. And that's because the tumors (presumably) progress through tumorigenesis independently in each eye. We hypothesize that is also why children with bilateral disease sometimes respond very well to treatment in one eye and not in the other. The reason for this disparity is likely at the molecular level. Hopefully, our 6p data will show that we can prognosticate between eyes of the same child using the aqueous as well.

References

1. J Berry et al., “Aqueous Humor is Superior to Blood as a Liquid Biopsy for Retinoblastoma”, *Ophthalmol*, 127, 552-554 (2020). PMID: 31767439
2. J Berry et al., “Genomic cfDNA Analysis of Aqueous Humor in Retinoblastoma Predicts Eye Salvage: The Surrogate Tumor Biopsy for Retinoblastoma”, *Molecular Cancer Research*, 16, 1701-1712 (2018). PMID: 30061186

the Ophthalmologist™

Bringing intelligent journalism
to eye care

Register
For Free
Today!



Register for free at
www.theophthalmologist.com/register

Print | Website | Mobile | Social



Profession

Your career
Your business
Your life



46–47

From Necessity Comes Invention
For Rishi Singh, COVID-19 is an opportunity for creativity. From virtual visits to home testing, there are plenty of ways to continue caring for patients – if you are able to try

From Necessity Comes Invention

Virtual visits, home testing, revised protocols – there are plenty of creative ways you can continue caring for patients

By Rishi Singh

COVID-19 is a rapidly evolving situation – and our practices are having to evolve with it. Initially, when recommendations were first presented, we thought we'd have to reduce our clinical volume and maybe defer some appointments. Then the American Academy of Ophthalmology released a statement asking us to defer elective surgery all together to conserve personal protective equipment. The only service still operating is glaucoma and retina. We are seeing patients with retinal detachments, proliferative diabetics, glaucoma patients who are uncontrolled and can't be managed, patients with neovascular AMD or retinal vein occlusion where vision loss is pretty significant, but little beyond that. All other services have been shelved.

The Cleveland Clinic is a tertiary care referral center, which means we're still operating pretty frequently as we receive patients from other ophthalmology offices that have had to close. In terms of retina, clinic volume is down, as is our surgical volume, but not by as much as I would have imagined – in part due to the nature of our practice, but also the nature of the providers in our region.

Unusual precautions

Any patient who is sent to us for surgery is triaged for COVID-19 symptoms – fever, cough, respiratory illness, fever, temperature or any kind of GI dysentery – and has their temperature taken before they enter the clinic. Unfortunately, Chinese

literature has shown that one third of patients are asymptomatic, which is why we also offer masks. The proximity between ophthalmologist and patient is really quite intimate so risk of transmission is high. We invested in slit lamp guard shields when the pandemic started and we wear face masks, hats, and goggles in the clinic. Of course, my concern is not only for my practice, but also for my family. My wife is an internist and has treated – and will continue to treat – patients with the virus. On top of that, we have three elderly people living with us – my parents and mother-in-law. We haven't had any major issues so far, but I take precautions. I change my clothes before I come home, wash my hands multiple times a day and have hand sanitizer on me at all times.

Fortunately, our non-essential patients understand the limitations of what we can do right now, given our current status. They also are fearful of getting infected or infecting their loved ones, and are generally happy to defer surgery. Truth be told, it is called elective for a reason. Studies have shown that an epiretinal membrane can be peeled three months later without any significant detriment to vision. In fact, even in the anti-VEGF era, we know that deferring treatment for three months causes no significant detriment to visual acuity.

Virtual reality

With this in mind, we've focused our attention on retooling the practice and we now offer virtual appointments. These typically fall into two categories. The first is more of a routine check up to see if we could possibly defer the appointment for two to three months' time; this is mostly for patients with intermediate AMD or patients with mild, moderate or severe PDR approaching their six-month check-up. During the video conversation, I ask the patient:

how is your vision doing? Have you noticed any visual field changes? If everything looks okay, we defer the appointment. The second category is follow-up cases, typically ones that have been referred to us. I'm able to see the patient's electronic medical records – sent by my provider 50 miles away – review them and talk to the patient sensitively about what images have shown. I then discuss the surgical procedure in a preliminary fashion, with written consent to come later. The nice thing is that we're able to have this discussion on the phone in a more private setting.

We typically use Amwell [telemedicine platform] for these appointments, but with the relaxation of professional guidelines, most patients prefer to use FaceTime or Google Duo. So far, everyone seems happy with this system. In fact, I was actually impressed at how receptive patients have



been – even our older population is willing to try and interact with us in a virtual manner.

We don't have a lot of tools available to us right now, but we're looking to expand some of our capabilities in the future, including home OCT.

Changing protocols

Times may be hard but they are also interesting for physicians, in that we are having to rethink the way we deliver care. In my mind, we're going to be better physicians – and a better society – because of it. The pandemic has given us a unique opportunity to explore new technologies and evaluate patients in ways we once believed were not possible. This is our time to test the boundaries of medicine – so let's be creative. Trial new ways of seeing your patients that aren't totally virtual. One of our pediatric providers is providing certain instructions as far

as how pediatric patients might check their vision at home – a home chart for example – and testing them over the phone. These remote appointments could be applicable to other areas of the practice, too. Many of the complaints we receive at our ophthalmology office are not necessarily related to us at all. I get a lot of patients who come in with external post-operative issues, such as red eyes or irritation, which could easily be converted to virtual visits. I've seen 15–20 percent of my patients this way since the pandemic started. Two weeks ago, that number was essentially zero.

My only hope is we carry on with these practices once the pandemic subsides, as it is already proving to be an effective way of rapidly delivering care. Obviously, the issue is that there is no evidence base to support that yet, but I don't know if there needs to be. The problem with much of Western medicine has been the need to test and retest things across large populations. While this is generally done for good reason, it is something

that requires significant time, effort and money – things we just don't have right now. A great deal of data might come from this pandemic that confirms we did really well with these virtual visits, with no patients suffering a significant visual detriment or loss as a result.

So where does that leave us? I am hopeful that while this is a trying time, it is also a time for us to be innovative in how we serve our patients. If anything, we're going to sit back 10 or 15 years from now and be able to see what worked well, so that we can apply it to real clinical practice in the future. We will get through this pandemic – but only by doing something about it, not by sitting on the sidelines.

Rishi Singh is a staff surgeon at the Cole Eye Institute, Cleveland Clinic and Associate Professor of Ophthalmology at the Lerner College of Medicine in Cleveland, OH, USA. He also currently serves as the medical director of informatics at the Cleveland Clinic.

British-Made Innovation

Sitting Down With... Tim Clover,
CEO of Rayner



What route did you take to become CEO of Rayner?

I began my career in R&D but, at that time, I wasn't sure if it was for me. Now, in the middle of my career, R&D is one of my passions within the company. Nevertheless, I switched from a PhD to an MBA and went up through the commercial company ranks. I was involved in Zeiss' acquisition of Humphrey Instruments from Allergan and, by virtue of that, I found my way into Allergan. There, I was lucky enough to work with Jim Mazzo and some other interesting industry figures. I then became one of the early members of AMO (Advanced Medical Optics), when it spun off from Allergan – in fact, I worked on that transition.

At that point, my career took a slightly more entrepreneurial turn. I span a company out of Oxford University, and it ended up being quite successful, so I found myself in Fidelity, running a private equity fund. As part of that role I purchased a group of eye hospitals and turned them into Optegra – a leading worldwide provider of eye surgery centers operating from 23 specialist eye hospitals across Europe. In 2014 I became a non-executive director of Rayner with a brief to develop a strategic growth plan for the company which led to me being appointed CEO in 2015.

How has Rayner changed during your time at the company?

It is a fascinating company with a long history, but it had some real problems at the time when I started to get involved, such as a lack of product innovation. We had a large opticians' business with 200 shops, which was, frankly, unable to compete with the large high street chains and the impact of the internet. In the end we sold the opticians aspect of the business, and decided to bring the focus to high-tech IOL manufacturing.

We've now built a state-of-the-art

manufacturing center in the UK, with a capacity for three million IOLs per year. I also wanted to strengthen and build the R&D team, and to foster collaborations with clinicians and entrepreneurs to drive the introduction of products to fill the immediate gap in our business, and to return Rayner to its heritage as a product innovator. At the same time, I knew we needed to develop the next range of more transformative products for the future. In fact, I want Rayner to be the partner of choice for surgeons and innovators, being small enough to really care about new product development, large enough to launch a product globally, but open enough to collaborate jointly on projects with inventors – quite a different approach to some of our larger competitors.

We're now launching the Rayner "patient journey," which secures our position as a company that is fully focused on patients' visual outcomes. From AEON for the tear film pre- and post-surgery to a comprehensive range of IOLs, and RayPRO to collect three-year outcome data. Visual outcomes is our sole focus – and we want to do it better than anybody else in the industry!

What latest innovations are you most excited by?

We've recently introduced RayPRO – an app-based system for the collection of three years of patient follow-up data on every single Rayner lens that is implanted. It truly amazed me to think that there are apps out there offering users a wealth of data on everyday activities, such as running or cycling, and yet, many surgeons still have no data on patients, even one month after surgery. I think there is really exciting potential for ophthalmology to start engaging not just with clinical trials of 50 or 60 patients, but to have insights from datasets of more than 500,000 patients. This is exactly what we aspire to be able to do with RayPRO within five years.

"I want Rayner to be the partner of choice for surgeons and innovators, being small enough to really care about new product development, large enough to launch a product globally, but open enough to collaborate jointly on projects with inventors."

Where is RayPRO right now – and how do you see it developing over the coming years?

We launched RayPRO at ASCRS in 2019, and the product is now available worldwide. We originally set ourselves some quite conservative targets for the first year – and so, within the first two months, we had more than doubled our targets for the whole year. We're really happy about the way it is rolling out.

I think the biggest surprise is where it is rolling out; we're seeing real enthusiasm in countries that were not even in our forecasts. Conversely, in the countries where we thought it would be adopted more aggressively, for example, the UK, there appears to



be more conservatism when it comes to sharing data in this way. It is too early to tell whether the app is an overwhelming success yet, but it is something that I am passionate about, and I would love to see it develop as part of our range. When you're setting investment priorities for R&D, having robust, high-quality data is really important.

Any other product launches of note?
We also launched our RayOne Trifocal

Toric at ESCRS 2019 – the last piece of the jigsaw for us in terms of trifocality. It's a very complicated product to manufacture, and although we actually had the final product much earlier on in the year, we were waiting on a multicenter study in the UK, Germany, Spain and Japan which gave outstanding results.

We've also developed a new range of eye drops, AEON, making us the only company in the world with an eye drop that has a labeling claim for before and

after eye surgery. Studies show that up to 75 percent of patients get dry eye after cataract surgery – a condition that directly impacts their visual outcomes – we think that it is a really important and possibly overlooked area of our industry.

How do you see your career progressing in the future?

I've been in the ophthalmic world for more than 30 years now, and Rayner for me is an absolutely unique opportunity; after all,

it is the company that made the world's first intraocular lens in 1949. In reality, we should be the world's biggest IOL company; our history is full of innovation and entrepreneurship, including the world's first ever multifocal toric, the first lens ever approved by the FDA... a whole series of firsts. I see my job as reclaiming and retaining our leadership position in ophthalmology – and I am personally driven to achieve that goal; it's a company I've known for 30 years and I would love to be the architect of its success for the next 30 years – and beyond!

"In my opinion, companies need R&D and product focused chief executives for certain periods in their life, and Rayner needed a period of energy, entrepreneurship and innovation. I certainly see these very much as my own strengths."

What's your management style? And does your background in R&D help?

I'd like to think it does. But perhaps I'm just someone who interferes – you'd have to ask the head of R&D whether I help or hinder! Seriously, in my opinion, companies need R&D and product focused chief executives for certain periods in their life, and Rayner needed a period of energy, entrepreneurship and innovation. I certainly see these very much as my own strengths.

But very clearly, the success of Rayner is not solely down to me; it is the result of a great group of people that we've been able to bring together within the company. Maybe at a "giant" company, where the world revolves around corporate governance and bureaucracy, I might not be the right leader. But right now I find myself with acres of opportunity, which is both rewarding and stimulating. I'm hoping to be here for a long time to come.

Dextenza®

(dexamethasone ophthalmic insert) 0.4 mg
for intracanalicular use

BRIEF SUMMARY: Please see the DEXTENZA Package Insert for full prescribing information for DEXTENZA (06/2019)

1 INDICATIONS AND USAGE

DEXTENZA® (dexamethasone ophthalmic insert) is a corticosteroid indicated for the treatment of ocular inflammation and pain following ophthalmic surgery.

4 CONTRAINDICATIONS

DEXTENZA is contraindicated in patients with active corneal, conjunctival or canalicular infections, including epithelial herpes simplex keratitis (dendritic keratitis), vaccinia, varicella; mycobacterial infections; fungal diseases of the eye, and dacryocystitis.

5 WARNINGS AND PRECAUTIONS

5.1 Intraocular Pressure Increase

Prolonged use of corticosteroids may result in glaucoma with damage to the optic nerve, defects in visual acuity and fields of vision. Steroids should be used with caution in the presence of glaucoma. Intraocular pressure should be monitored during the course of the treatment.

5.2 Bacterial Infection

Corticosteroids may suppress the host response and thus increase the hazard for secondary ocular infections. In acute purulent conditions, steroids may mask infection and enhance existing infection [see Contraindications (4)].

5.3 Viral Infections

Use of ocular steroids may prolong the course and may exacerbate the severity of many viral infections of the eye (including herpes simplex) [see Contraindications (4)].

5.4 Fungal Infections

Fungus invasion must be considered in any persistent corneal ulceration where a steroid has been used or is in use. Fungal culture should be taken when appropriate [see Contraindications (4)].

5.5 Delayed Healing

The use of steroids after cataract surgery may delay healing and increase the incidence of bleb formation.

6 ADVERSE REACTIONS

The following serious adverse reactions are described elsewhere in the labeling:

- Intraocular Pressure Increase [see Warnings and Precautions (5.1)]
- Bacterial Infection [see Warnings and Precautions (5.2)]
- Viral Infection [see Warnings and Precautions (5.3)]
- Fungal Infection [see Warnings and Precautions (5.4)]
- Delayed Healing [see Warnings and Precautions (5.5)]

6.1 Clinical Trials Experience

Because clinical trials are conducted under widely varying conditions, adverse reaction rates observed in the clinical trials of a drug cannot be directly compared to rates in the clinical trials of another drug and may not reflect the rates observed in practice. Adverse reactions associated with ophthalmic steroids include elevated intraocular pressure, which may be associated with optic nerve damage, visual acuity and field defects, posterior subcapsular cataract formation; delayed wound healing; secondary ocular infection from pathogens including herpes simplex, and perforation of the globe where there is thinning of the cornea or sclera [see Warnings and Precautions (5)].

DEXTENZA was studied in four randomized, vehicle-controlled studies (n = 567). The mean age of the population was 68 years (range 35 to 87 years), 59% were female, and 83% were white. Forty-seven percent had brown iris color and 30% had blue iris color. The most common ocular adverse reactions that occurred in patients treated with DEXTENZA were: anterior chamber inflammation including iritis and iridocyclitis (10%); intraocular pressure increased (6%); visual acuity reduced (2%); cystoid macular edema (1%); corneal edema (1%); eye pain (1%) and conjunctival hyperemia (1%).

The most common non-ocular adverse reaction that occurred in patients treated with DEXTENZA was headache (1%).

8 USE IN SPECIFIC POPULATIONS

8.1 Pregnancy

Risk Summary

There are no adequate or well-controlled studies with DEXTENZA in pregnant women to inform a drug-associated risk for major birth defects and miscarriage. In animal reproduction studies, administration of topical ocular dexamethasone to pregnant mice and rabbits during organogenesis produced embryofetal lethality, cleft palate and multiple visceral malformations [see Animal Data].

Data

Animal Data

Topical ocular administration of 0.15% dexamethasone (0.75 mg/kg/day) on gestational days 10 to 13 produced embryofetal lethality and a high incidence of cleft palate in a mouse study. A daily dose of 0.75 mg/kg/day in the mouse is approximately 5 times the entire dose of dexamethasone in the DEXTENZA product, on a mg/m² basis. In a rabbit study, topical ocular administration of 0.1% dexamethasone throughout organogenesis (0.36 mg /day, on gestational day 6 followed by 0.24 mg/day on gestational days 7-18) produced intestinal anomalies, intestinal aplasia, gastroschisis and hypoplastic kidneys. A daily dose of 0.24 mg/day is approximately 6 times the entire dose of dexamethasone in the DEXTENZA product, on a mg/m² basis.

8.2 Lactation

Systemically administered corticosteroids appear in human milk and could suppress growth and interfere with endogenous corticosteroid production; however the systemic concentration of dexamethasone following administration of DEXTENZA is low [see Clinical Pharmacology (12.3)]. There is no information regarding the presence of DEXTENZA in human milk, the effects of the drug on the breastfed infant or the effects of the drug on milk production to inform risk of DEXTENZA to an infant during lactation. The developmental and health benefits of breastfeeding should be considered along with the mother's clinical need for DEXTENZA and any potential adverse effects on the breastfed child from DEXTENZA.

8.4 Pediatric Use

Safety and effectiveness in pediatric patients have not been established.

8.5 Geriatric Use

No overall differences in safety or effectiveness have been observed between elderly and younger patients.

17 PATIENT COUNSELING INFORMATION

Advise patients to consult their surgeon if pain, redness, or itching develops.

Ocular
Therapeutix™

MANUFACTURED FOR:

Ocular Therapeutix, Inc.
Bedford, MA 01730 USA
PP-US-DX-0072-V2

BIG TIME INNOVATION¹

The first and only ophthalmic steroid insert approved for the treatment of inflammation and pain following ophthalmic surgery

DEXTENZA IS AN ADVANCEMENT IN STEROID TREATMENT

- Designed to deliver a tapered dose¹
- Contains fluorescein for visualization²
- No additional components or assembly required²
- Resorbable, so no need for removal²
- Insert can be removed via saline irrigation or manual expression, if necessary²
- Physicians rated DEXTENZA as easy to insert^{3,4*}

LEARN MORE AT DEXTENZA.COM

INDICATION

DEXTENZA is a corticosteroid indicated for the treatment of ocular inflammation and pain following ophthalmic surgery.

IMPORTANT SAFETY INFORMATION

CONTRAINDICATIONS

DEXTENZA is contraindicated in patients with active corneal, conjunctival or canalicular infections, including epithelial herpes simplex keratitis (dendritic keratitis), vaccinia, varicella; mycobacterial infections; fungal diseases of the eye, and dacryocystitis.

WARNINGS AND PRECAUTIONS

Prolonged use of corticosteroids may result in glaucoma with damage to the optic nerve, defects in visual acuity and fields of vision. Steroids should be used with caution in the presence of glaucoma. Intraocular pressure should be monitored during treatment.

Corticosteroids may suppress the host response and thus increase the hazard for secondary ocular infections. In acute purulent conditions, steroids may mask infection and enhance existing infection.

*73.6% of physicians in Study 1, 76.4% in Study 2, and 79.6% in Study 3 rated DEXTENZA as easy to insert.

References: **1.** Sawhney AS et al, inventors; Incept LLC, assignee. US patent 8,409,606 B2. April 2, 2013. **2.** DEXTENZA [package insert]. Bedford, MA: Ocular Therapeutix, Inc; 2019. **3.** Walters T et al. *J Clin Exp Ophthalmol*. 2016;7(4):1-11. **4.** Tyson SL et al. *J Cataract Refract Surg*. 2019;45(2):204-212.

© 2020 Ocular Therapeutix, Inc. All rights reserved.
DEXTENZA is a registered trademark of Ocular Therapeutix, Inc. PP-US-DX-0193

Use of ocular steroids may prolong the course and may exacerbate the severity of many viral infections of the eye (including herpes simplex).

Fungus invasion must be considered in any persistent corneal ulceration where a steroid has been used or is in use. Fungal culture should be taken when appropriate.

Use of steroids after cataract surgery may delay healing and increase the incidence of bleb formation.

ADVERSE REACTIONS

The most common ocular adverse reactions that occurred in patients treated with DEXTENZA were: anterior chamber inflammation including iritis and iridocyclitis (10%); intraocular pressure increased (6%); visual acuity reduced (2%); cystoid macular edema (1%); corneal edema (1%); eye pain (1%) and conjunctival hyperemia (1%).

The most common non-ocular adverse reaction that occurred in patients treated with DEXTENZA was headache (1%).

Please see brief summary of full Prescribing Information on adjacent page.