JUNE 2015 # 20

the Ophthalmologist

Images of Ophthalmology

The artistic side of ophthalmology: images that capture what vision means to you

A **NEW** ERA HAS BEGUN, AND IT LOOKS AMAZING.

Introducing **TECNIS®** Symfony IOL, the first and only presbyopia-correcting Extended Range of Vision IOL.

TECNIS®
Symfony
Extended Range of Vision IOL

At last, your patients can enjoy increased spectacle independence with a true extended range of vision.[1]

- A full range of continuous, high-quality vision in all light conditions[2]
- Incidence of halo and glare comparable to a monofocal IOL[1]
- **TECNIS®** Symfony Toric IOL also available

The world will never look the same.

For more information, contact your Abbott Medical Optics sales representative.

1. 166 Data on File_Extended Range of Vision IOL 3-Month Study Results (NZ).
2. TECNIS® Symfony DFU

TECNIS® Symfony Extended Range of Vision Lenses are indicated for primary implantation for the visual correction of aphakia and preexisting corneal astigmatism in adult patients with and without presbyopia in whom a cataractous lens has been removed by extracapsular cataract extraction, and aphakia following refractive lensectomy in presbyopic adults, who desire useful vision over a continuous range of distances including far, intermediate and near, a reduction of residual refractive cylinder, and increased spectacle independence. These devices are intended to be placed in the capsular bag. For a complete listing of precautions, warnings, and adverse events, refer to the package insert.

Abbott
A Promise for Life

Online this Month

The Ophthalmologist on Twitter

What got you tweeting this month? Here are some of our most popular tweets…

Top Tweet

The Ophthalmologist @OphthoMag
#RCOphthCongress2015 Here's our Editor attempting to perform a rhexis on an artificial eye at @MalosaMedical's booth.
11:38 AM – 20 May 2015

The Ophthalmologist @OphthoMag
FDA has stated it will accept "valid" foreign clinical trial data in support of premarket submissions for MDs: http://bit.ly/1ExpHbO
8:00 AM – 28 May 2015

Wendell J. Scott: The Scott Femto Chop

In this issue, Wendell J. Scott tells us how the Venturi pump can allow surgeons to take full advantage of the fragmentation capabilities of their femtosecond lasers during cataract surgery. He describes his technique to exploit the benefits of laser treatment and take advantage of maximal Venturi vacuum to minimize the need for ultrasound energy.

To view the video of the Scott Femto Chop technique, head on over to: top.txp.to/0615/femto-chop

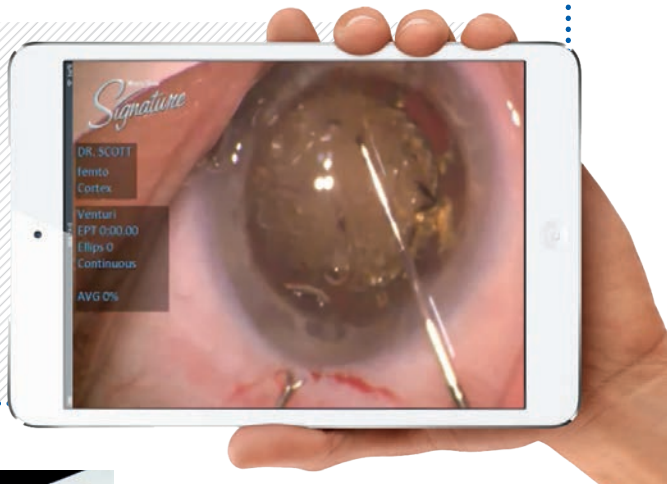



The Ophthalmologist @OphthoMag
Final #ARVO2015 keynote: Ian Crozier. Ebola survivor. Impact on West Africa; heartbreaking. His story: terrifying
11:09 PM – 7 May 2015

The Ophthalmologist @OphthoMag
An illuminated sleep mask exploiting the Troxler effect might help treatment of diabetic retinopathy. @ppxrichardkirk http://ow.ly/N7Wbp
11:30 AM – 25 May 2015

Follow us on twitter: @OphthoMag

Contents

16

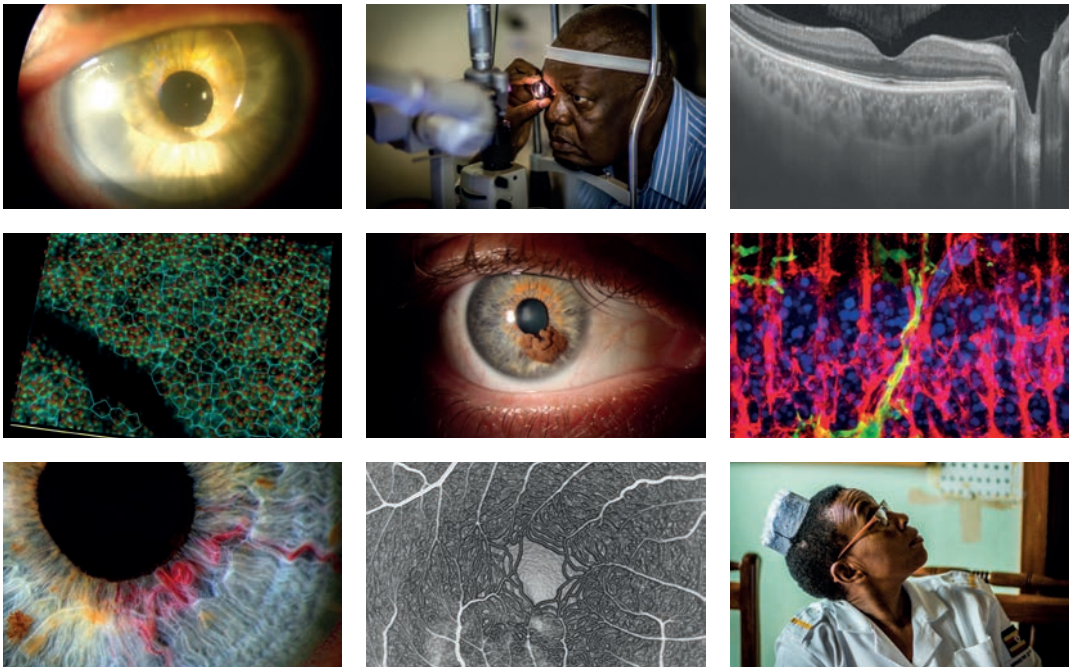

On The Cover

"Eyes" by Cecil Riley, 2008, oil on paper. Cecil Riley has age related macular degeneration. Now in his nineties, Cecil began having visions of eyes and gargoyle faces appearing in front of him. Following advice from the Macular Society, he discovered that they are caused by Charles Bonnet Syndrome, and has been able to make more sense of the visions. Cecil says: "A positive attitude to the visions is healthy and constructive. For me it's been like a rebirth; the visions have opened my eyes to a whole new way of painting."

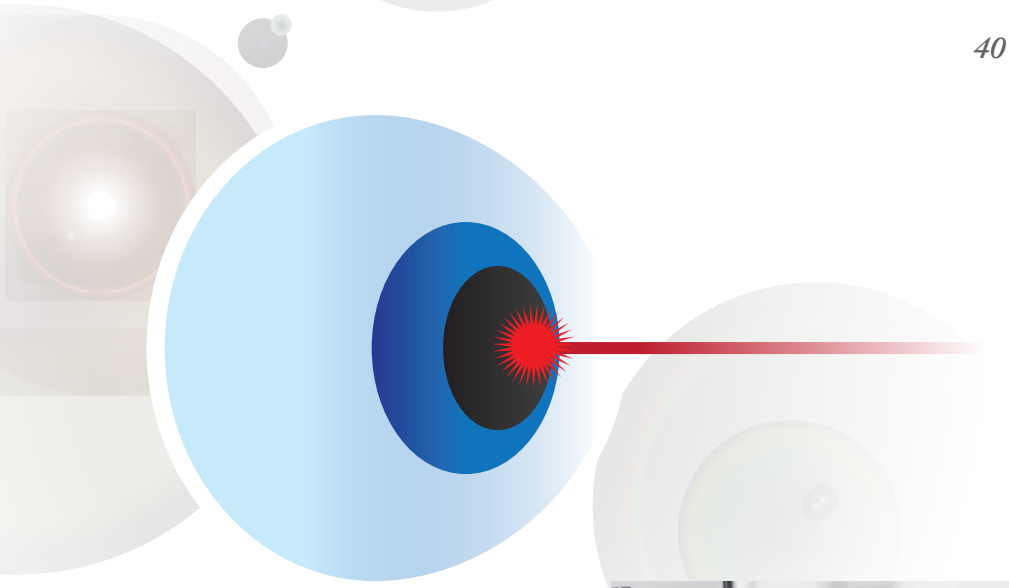

In Practice

Profession

Sitting Down With

the Ophthalmologist

ISSUE 20 - JUNE 2015

Published by
Texere Publishing Limited,
Booths Hall, Booths Park, Chelford Road,
Knutsford, Cheshire, WA16 8GS, UK

General enquiries:
www.texerepublishing.com
info@texerepublishing.com
+44 (0) 1565 752883
sales@texerepublishing.com

Distribution:
The Ophthalmologist distributes 17,934 printed copies and 7,295 electronic copies to a targeted European list of industry professionals.
ISSN 2051-4093

Available on the App Store

texere publishing ltd

It's Never as Simple as it Seems

A simple, clean and elegant gene editing technique might not be that simple, clean or elegant.

As always, the annual ARVO congress had a number of hot topics. Imaging – particularly multiphoton and OCT angiography – garnered a lot of attention from delegates. One of the most oversubscribed sessions was a review of the ocular problems caused by spaceflight (1) and judging by the #ARVO2015 hashtag on Twitter, the big blue bear statue outside the Colorado Convention Center was particularly popular. As always, gene and stem cell therapies were red hot because of their huge therapeutic potential, and the results of some experiments using the whitest hot gene technology of them all, CRISPR/Cas9, was presented at the congress. Zebrafish, human cell lines, even rats *in vivo*, all had their genomes tweaked with this simple and readily available gene editing technique.

Of course, it's one thing being able to achieve something pre-clinically; it's another successfully transferring it into the clinic. And so, a fortnight before ARVO, a pretty controversial CRISPR/Cas9 paper was published (2) that highlighted just how difficult it might be to successfully deploy the technique in the clinic. A team of researchers at Sun Yat-sen University in China performed a world first: they edited the genomes of (nonviable) human embryos with CRISPR/Cas9. If we set aside the ethical debates over whether such germline-modifying procedures should be performed on embryos (notably, Nature and Science rejected the paper because of these concerns [3]), there was one thing that should dampen the gene editing technique's luster: it didn't work very well.

The researchers were trying to use CRISPR/Cas9 to edit the gene that encodes hemoglobin B protein (HBB). They injected 86 embryos, waited 48 hours (long enough for gene editing to occur and the embryos to grow to the eight-cell stage). Seventy-one survived; 54 were tested; only four were successfully and correctly edited – and these embryos were mosaic, meaning that only some of the eight cells were edited. Further, whole exome sequencing of these cells demonstrated a number of off-target mutations, suggesting that the CRISPR/Cas9 complex was acting on other parts of the genome too. This might not be a killer blow for germline gene editing (ethics permitting) – the embryos weren't "normal"; conditions can be optimized, enzymes tweaked, and there are harder-to-use but more specific alternatives to CRISPR/Cas9 like TALENs that are believed to cause fewer unintended mutations. But it is a reminder of how immature these technologies are, and how almost everything in research is more complicated than it may seem.

Mark Hillen
Editor

Reference

1. *M Hillen, "VIIP: A Space Odyssey", The Ophthalmologist, 8, 30–34 (2014). Available at: http://bit.ly/VIIPspace, accessed May 26, 2015.*
2. *P Liang, et al., "CRISPR/Cas9-mediated gene editing in human tripronuclear zygotes", Protein Cell, 6, 363–372 (2015). PMID: 25894090.*
3. *D Cyranoski, S Reardon, "Chinese scientists genetically modify human embryos", Nature News, (2015). Available at: http://bit.ly/chinesecrispr, accessed May 26, 2015.*

Carl Glittenberg

A practicing ophthalmologist at the Medical Retina Unit of the Rudolf Foundation Hospital, Vienna, Carl Glittenberg is a very prominent name in the world of ophthalmic imaging. Glittenberg also holds the roles of vice chairman of the Karl Landsteiner Institute for Retina Research and Imaging, and CEO of Glittenberg Medical Visualization.

See Carl's contributions to the Images of Ophthalmology feature on pages 24-25.

Wendell J. Scott

Wendell J. Scott is a hugely experienced cataract/refractive surgeon at Mercy Eye Specialists in Springfield, MO, USA, and has been a practicing ophthalmologist for over a quarter of a century. Over that period, Scott has published numerous peer-reviewed journal articles on topics ranging from femtosecond laser-assisted cataract surgery to ophthalmic antisepsis.

Wendell shares some of his considerable experience on pages 40–42 – providing pearls on using Venturi pumps for lens aspiration during cataract surgery.

Bohdan Kousal

Bohdan Kousal is a Prague-based medical retina specialist, practicing at both the Department of Ophthalmology in the First Faculty of Medicine at Charles University and Prague's General University Hospital. Kousal is a co-founder of the Ophthalmic Genetic Centre at Charles University, and outside of ophthalmology, he plays the horn in Prague's University of Economics Orchestra.

Bohdan's contribution to the Images of Ophthalmology feature can be found on page 35.

Szilard Kiss

A member of our 2015 Power List, Kiss is an assistant professor of ophthalmology at Weill Cornell Medical College and an assistant attending physician at the New York Presbyterian Hospital. His clinical and translational research focuses on retinal imaging, ocular gene therapy, novel therapeutic targets for ocular neovascularization, and genetic markers for retinal diseases.

Szilard's images of proliferative diabetic retinopathy can be found on page 27.

Upfront

Reporting on the innovations in medicine and surgery, the research policies and personalities that shape ophthalmology practice.

We welcome suggestions on anything that's impactful on ophthalmology; please email
mark.hillen@texerepublishing.com



"Painting" on Presbyopia Correction

Could femtosecond laser-assisted keratopigmentation represent a new way of correcting presbyopia?

One method of surgically correcting presbyopia is to insert a small aperture opaque inlay into the corneal stroma of the non-dominant eye; the pinhole optics it produces improve near vision by increasing the implanted eye's depth of focus, and these days, the procedure involves creating a flap in the cornea by femtosecond laser, and placing the inlay underneath. But what if you could just "paint" a presbyopia-correcting ring on the cornea with the laser instead?

Abbott Medical Optics' (AMO) Vladimir Lemberg, Jim Hill and Hong Fu believe they've found a way to do it… using femtosecond laser-assisted keratopigmentation – or corneal tattooing (1). Simply put, they used an AMO iFS femtosecond laser to create a 200 µm deep intracorneal ring, cut at a range of aperture sizes, in 12 freshly harvested porcine corneas. They then manipulated the corneal incision with a spatula to open the anterior side of it, and filled the channels with a biocompatible opaque ink (Figure 1). They conducted theoretical analyses of the blur and image quality as a function of defocus and pupil size.

What they found was that in all cases, the laser produced complete, precisely centered ring cuts on the corneas; that the injected dye spread to cover the annulus of the ring cut and formed an aperture; and that the dye spreading resulted in a tendril-type pattern at the inner and outer edges of the cuts (Figure 2). The theoretical analyses showed that up to 3 diopters' depth of focus can be achieved with reasonable aperture sizes.

Could the results of this study signal the introduction of a new, unique approach to presbyopia correction? Not just yet. While the authors believe that this technique should have "several advantages over a ring-like inlay, such as the absence of foreign body sensation, elimination of displacement danger, and improved nutrient flow" they confirm that "further research is required to confirm the findings from this preliminary study." *MH*

References

1. *V Lemberg, et al., "Femtosecond Laser Assisted Keratopigmentation for Presbyopia Correction" IOVS, 56, ARVO E-Abstract 3939 (2015).*

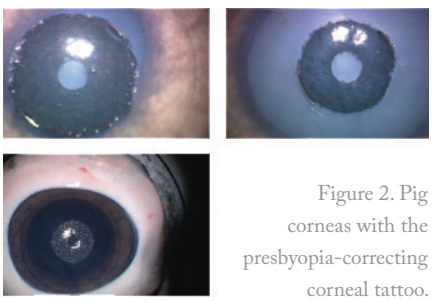

Figure 2. Pig corneas with the presbyopia-correcting corneal tattoo.

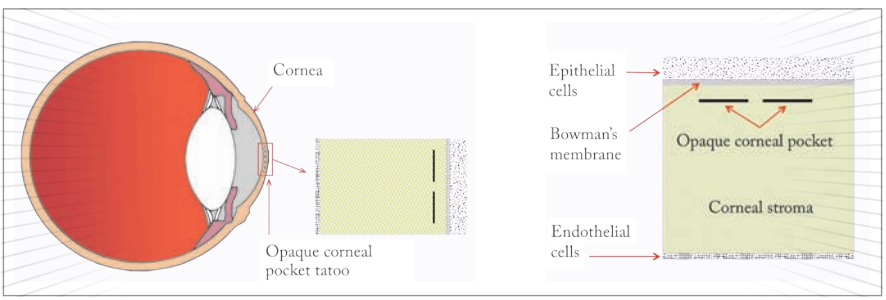

Figure 1. Location of intracorneal channels filled with a biocompatible, opaque ink used in corneal tattooing.

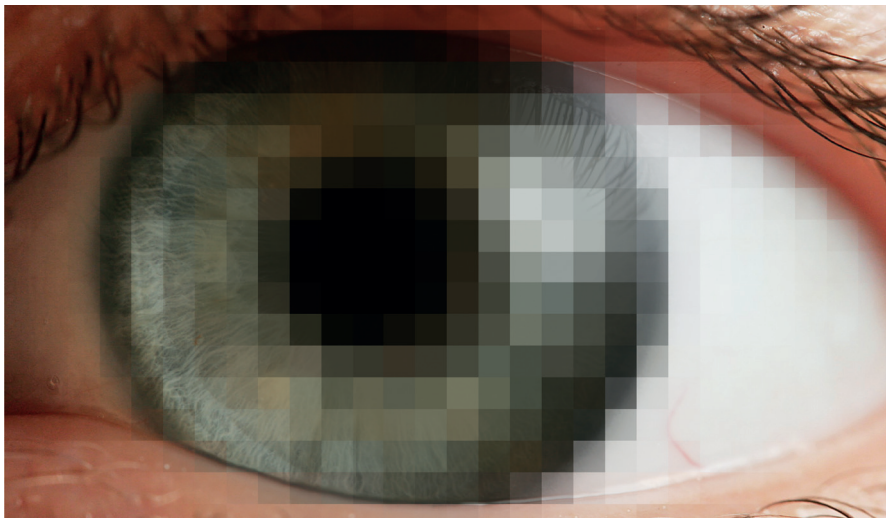

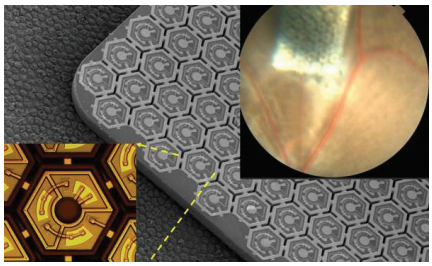

Figure 1. From right to left: Photovoltaic implant subretinally implanted in a rat; the array composed of 70 µm-wide pixels separated by 5 µm trenches arranged in a 1 mm-wide hexagonal pattern; and a high-resolution image of a single pixel.

The Sharper Image

Photovoltaic pixels could help create a wireless retinal prosthesis with a much better spatial resolution than current offerings

Most patients with retinal degeneration lose sight because of a gradual loss of photoreceptors, with the rest of the retina remaining largely functional. This fact is what enables retinal prostheses to work – they provide electrical stimulation of the surviving neurons and enable information to enter the visual system once more. There are two ways of stimulating the surviving neurons with retinal prostheses: epiretinally, targeting the retinal ganglion cells (the approach taken with Second Sight's Argus II), or subretinally, targeting the inner retinal neurons (as per Retina Implant's Alpha IMS). However, irrespective of the approach, the fact remains that the implantation of these prostheses and their transscleral cables is a long and challenging surgical procedure, and even after a successful procedure, visual acuity remains below 20/1,000 in most cases (1,2).

Now, a group of researchers have devised an alternative retinal prosthetic that they hope will overcome some of the alternatives' shortcomings (3). The implant consists of 70 µm wide photovoltaic pixels (Figure 1). Those pixels receive bright pulsed light from image-projecting video goggles and convert it into electrical signals that stimulate the retinal neurons – entirely without wires. This translates to a far simpler surgical procedure, as each hexagonal pixel array is only 1–2 µm wide and can be placed through a small retinotomy, allowing the ophthalmologist to tile a large visual field with minimal impact on the patient. Upon testing their photovoltaic implants in rats, the researchers found that they elicited retinal responses with a spatial resolution of 64 ± 11 µm – slightly under half the visual acuity of healthy rats (27 ± 9 µm).

The current generation of retinal prostheses have a cortical activation threshold of 0.55 mW/mm^2, about four times lower than that of the previous generation. Lower stimulation thresholds allow the development of better video goggles to be used with the prosthesis, and also permit a reduction in pixel size (in this case, by approximately a factor of two), meaning that – as pixel size is the resolution-limiting factor in this type of implant – spatial resolution can be correspondingly increased.

Following the success observed in animal models, the implant is set to enter clinical trials in France in 2016. "The performance we're observing at the moment is very encouraging," says the study's corresponding author, Georges Goetz. "Based on our current results, we hope that human recipients of this implant will be able to recognize objects and move about." The project's joint supervisor, Daniel Palanker, adds, "Eventually, we hope this technology will restore vision of 20/120, and if it works that well, it will become relevant to patients with age-related macular degeneration." *MS/RM*

References

1. *MS Humayun, et al., "Interim results from the international trial of Second Sight's visual prosthesis", Ophthalmology, 119, 779–788 (2012). PMID: 22244176.*
2. *K Stingl, et al., "Artificial vision with wirelessly powered subretinal electronic implant alpha-IMS", Proc Biol Sci, 280, 20130077 (2013). PMID: 23427175.*
3. *H Lorach, et al., "Photovoltaic restoration of sight with high visual acuity", Nat Med, 21, 476–482 (2015). PMID: 25915832.*

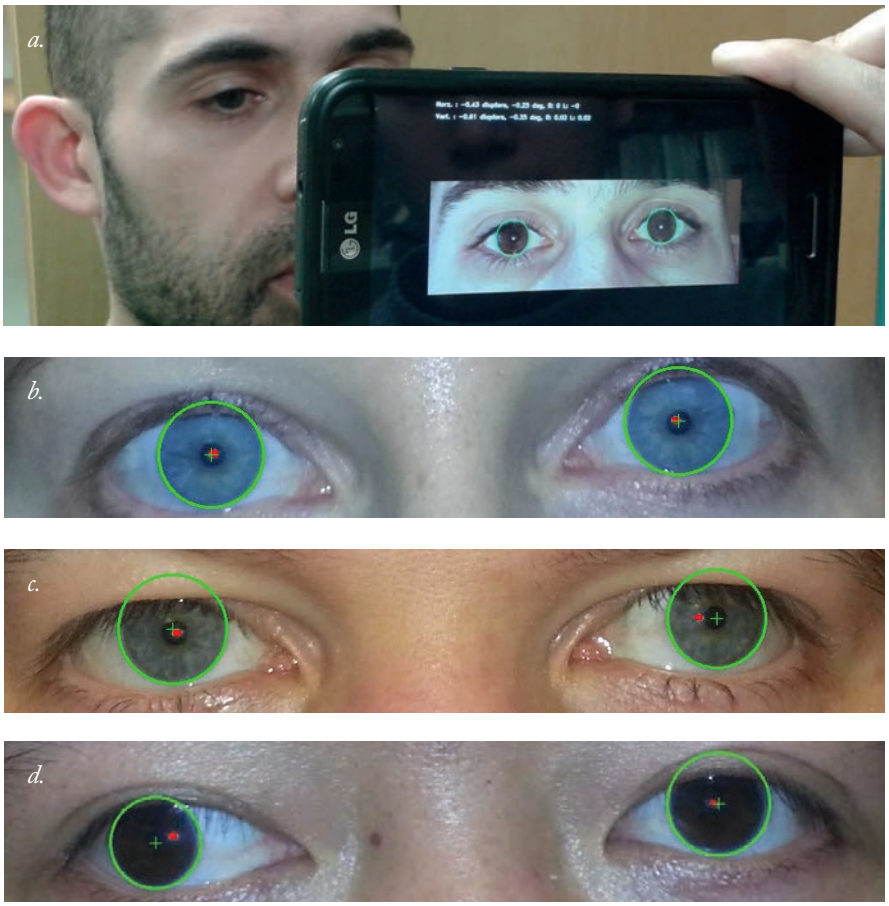

Figure 1. The smartphone app (a), and examples of (b) a patient without strabismus (<1 PD); (c) left exotropia (35 PD); (d) right exotropia (34 PD). PD, prism diopter.

Strabismus Screening – Now There's an App for That

A smartphone app could simplify strabismus screening and pave the way for telemedicine

The importance of early strabismus detection cannot be emphasized enough. Strabismus may cause double vision and lead to amblyopia in children, and early detection drastically improves the chances of successful treatment. However, detection in people of any age can be rather challenging: small (and intermittent) deviations can go undetected, and it's harder to screen people who are unable to speak – such as infants and adults with brain injury.

Shrinivas Pundlik and his colleagues Matteo Tomasi, Kevin Houston and Gang Luo at the Schepens Eye Research Institute in Boston, MA, decided to address the issue by developing an accessible, accurate tool for strabismus screening via a smartphone app (1). "The ubiquitous nature of smartphones and their increasingly powerful hardware provides an ideal platform for performing strabismus measurement, photo-documentation, and remote monitoring," explains Pundlik. "We felt that there was a need for an easy to use, accessible, and inexpensive tool for strabismus screening that could potentially be used in a variety of settings such as primary care clinics, community level screening programs, as well as at home," he adds.

How does the app work? It measures a corneal light reflex decentration, and using it is simple – launch the app, point the rear camera of the smartphone at the patient, and align their eyes with the detection box on-screen (Figure 1a). The user then takes a photograph using the flash, and the app automatically computes the deviation between the two eyes based on the established Hirschberg ratio. Currently, the app delivers the results by overlaying the detection of the limbus boundary and the corneal reflection on the captured image, to allow the user to check the accuracy of the localization. The deviations in horizontal and vertical directions are displayed in prism diopters (Figures 1b–d).

What's next? The team have two versions of the app planned, explains Pundlik: one for clinical use, and one for home. The clinical app would provide clinicians with detailed strabismus measurement parameters and photo-documentation options, in order to provide a quick screening tool for use alongside other tests, and also to provide photographic evidence for monitoring the condition. The home use version would provide a simple "yes/no" answer to the user with the option of securely sending the captured data to a doctor for further evaluation. *RM*

Reference

1. *S Pundlik, et al., "Preliminary Evaluation of a Mobile App for Strabismus Screening", IOVS, 56, ARVO E-Abstract 5212 (2015).*

Target Practice

A light box and a 35 mm slide could be all you need for therapeutic laser target practice

Figure 1. 35mm retinal slide on a lightbox.

How do you train an ophthalmologist to use a laser for the first time? If you don't have access to a computer-based simulator, there are some imaginative alternatives. Take laser photocoagulation on a "simulated fundus" as an example (1) – a piece of paper that has been photocopied black on one side, and some basic retinal vasculature drawn on in pen on the white side, is taped to the laser headpiece, and suffices as an extremely inexpensive practice medium – it's okay, but it's certainly something that can be improved upon.

That's exactly what UK-based ophthalmologist Seema Arora and Leadership Fellow in Simulation, Polly Dickerson, decided to do (2). Instead of attaching paper to a retinal laser's headpiece, they attached 35 mm photographic slides depicting retinal pathologies and a small battery-operated lightbox (Figure 1) to the laser machine's forehead rest. How does it work? Trainees apply the laser beam directly to the slides without the need for a contact lens; they can try out different pulse durations and investigate treatment options for various procedures. Images can be projected to multiple viewers before and after treatment, which supports group training and discussion – and Arora and Dickerson have developed a "recipe book" of faculty requirements and debriefing discussions in their training materials to maximize the benefits of the slides. Slides can also be printed with photographs of the angle structure – ideal for practicing selective laser trabeculoplasty.

Although the 35 mm slides are both inexpensive and easy to use, there is one big drawback; laser burn intensity cannot be titrated on them. Nevertheless, Arora and Dickerson view the slides as "a cost-effective and widely available tool that has the potential to democratize access to simulated laser training." *MS/MH*

References

1. *AW Cohen, et al., "Learning to use the PASCAL laser system; a part of on-going professional development" (2009). Available at: http://bit.ly/1PLdiNh. Accessed May 26, 2015.*
2. *S Arora, P Dickerson, "35 mm slides – a novel target to simulate laser treatment". Poster presented at the Royal College of Ophthalmologists Annual Congress; May 19–21, 2015; Liverpool, United Kingdom. Available at: http://bit.ly/1Ey1rpQ. Accessed May 26, 2015.*

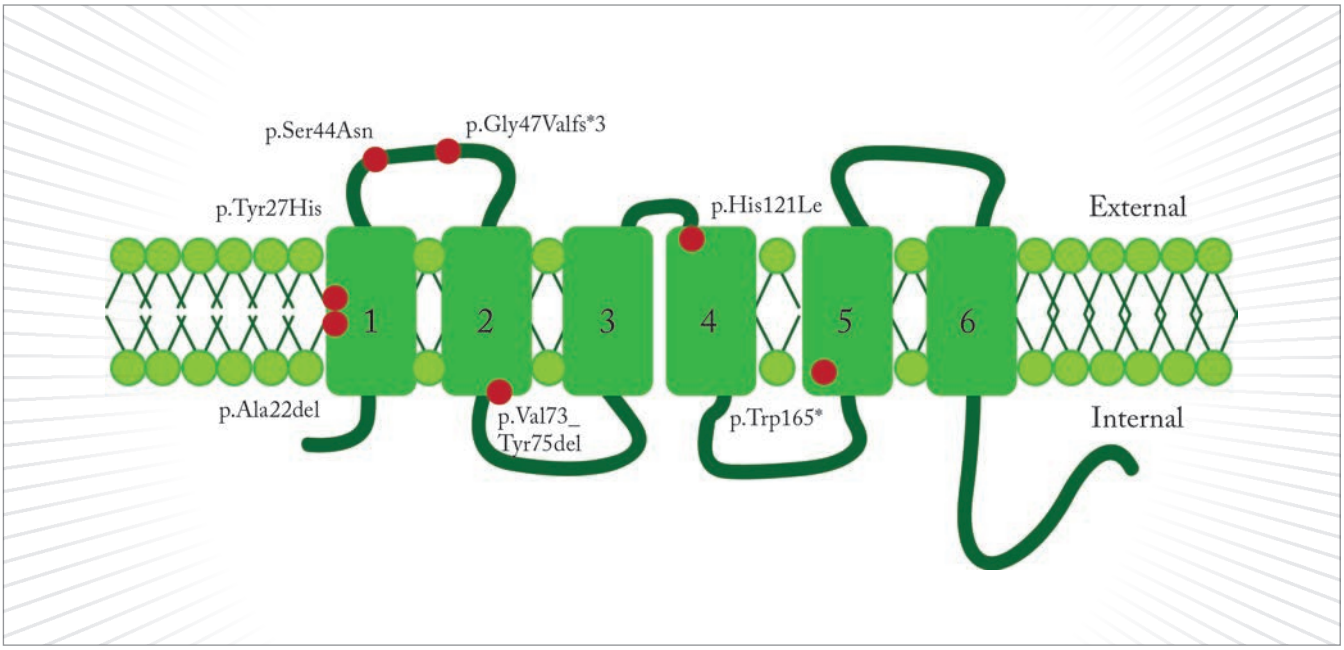

Figure 1. Schematic diagram of DRAM2 showing the location of the identified amino acids within the protein domains.

A DRAMatic Result

A protein involved in autophagy, DRAM2, appears to be essential for photoreceptor survival

Autophagy – an intracellular degradation system that delivers cytoplasmic contents to the lysosome for breakdown and recycling – is one of those simple processes in cell biology that actually plays a wide variety of physiological and pathophysiological roles (1). And it turns out that mutations in an autophagy-related gene expressed in the retinal pigment epithelium (RPE) are the cause of a newly identified type of adult-onset retinal dystrophy with early macular involvement.

Results published in the American Journal of Human Genetics (2) describe people from five families with a variety of *DRAM2* mutations (Figure 1), all of which led to the loss of central vision from the ages of ~30–40 years onwards, and also the loss of peripheral vision in older individuals. *DRAM2*, or to give it its full name, DNA damage-regulated autophagy modulator protein 2, encodes a transmembrane lysosomal protein that plays a role in initiating autophagy, and is expressed in both photoreceptors and the surface of RPE cells.

One of the paper's co-authors and leader of the team that made the initial discovery, Manir Ali, noted that, "a high level of autophagy takes place in RPE due to the need for constant renewal of the photoreceptor outer segments following daily light-induced damage", explaining that "it is therefore likely that, in the absence of correctly functioning DRAM2 protein, autophagy and photoreceptor renewal is reduced, leading to thinning of the photoreceptor cell layer. Our findings suggest that DRAM2 is essential for photoreceptor survival." *RM/MH*



References

1. *N Mizushima, "Autophagy: Process and Function", Genes & Dev, 21, 2861–2873 (2000). PMID: 18006683.*
2. *ME El-Asrag, et al., "Biallelic mutations in the autophagy regulator DRAM2 cause retinal dystrophy with early macular involvement", Am J Hum Genet, 96, 695–708 (2015). PMID: 25983245.*

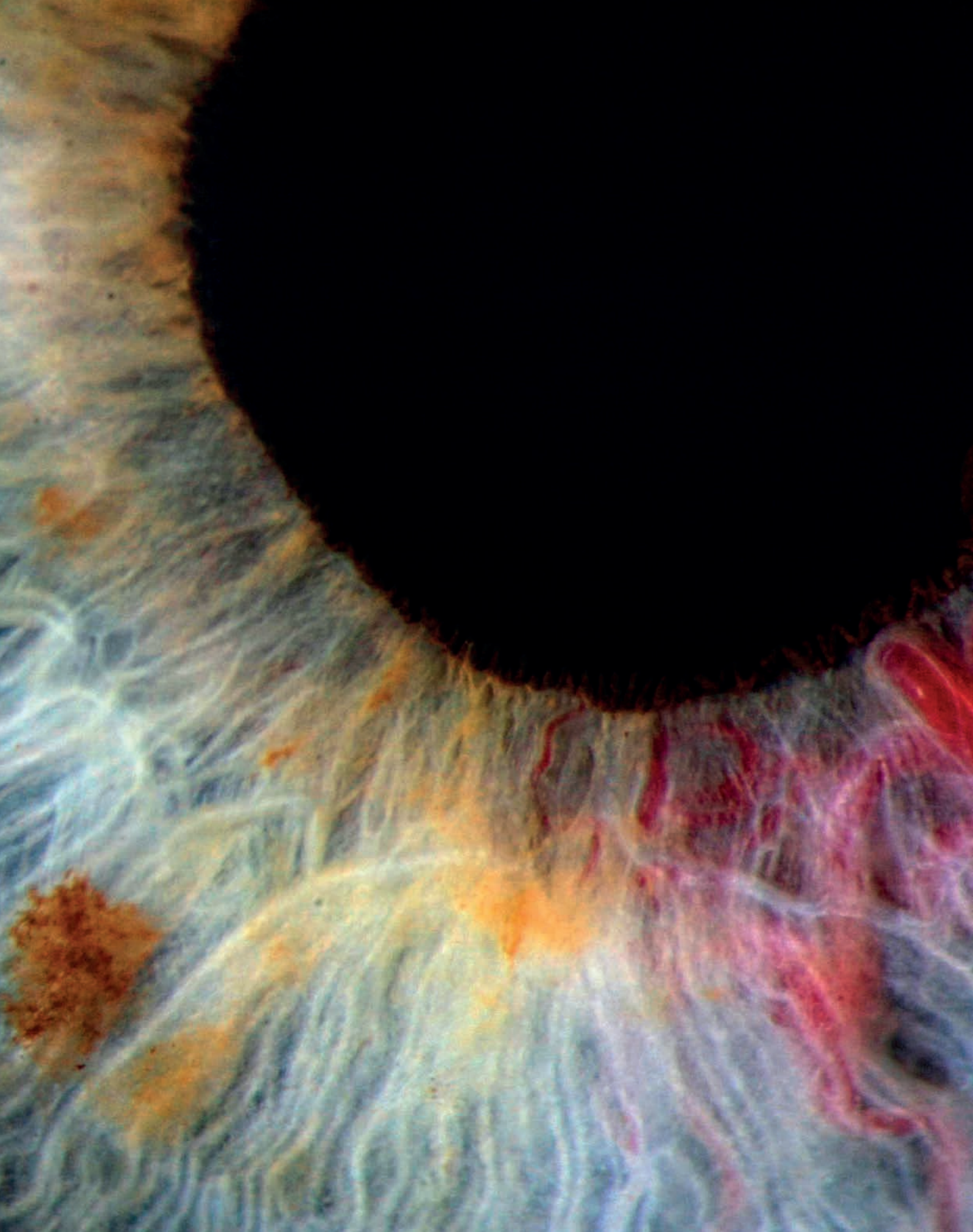

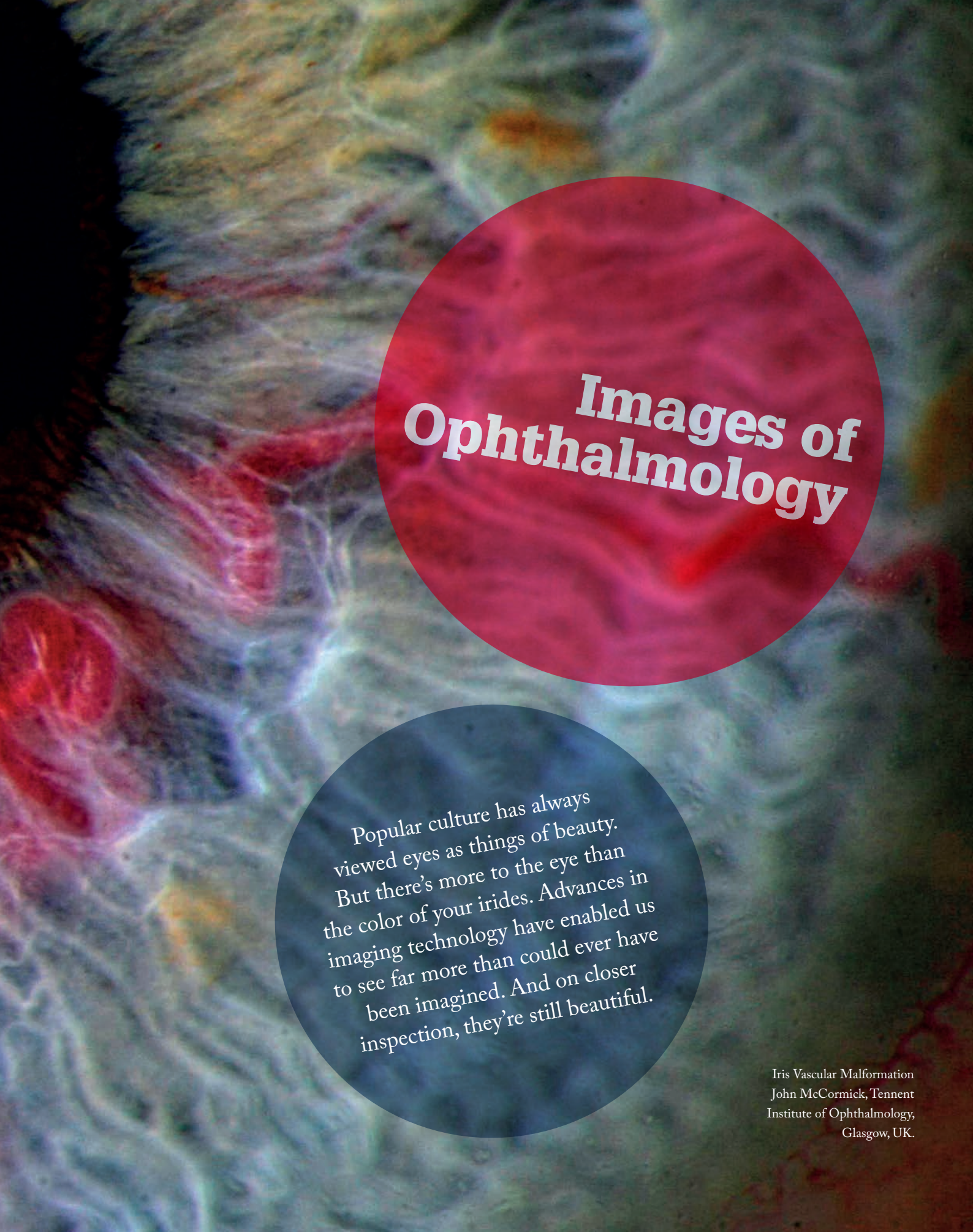

Images of Ophthalmology

Popular culture has always viewed eyes as things of beauty. But there's more to the eye than the color of your irides. Advances in imaging technology have enabled us to see far more than could ever have been imagined. And on closer inspection, they're still beautiful.

Iris Vascular Malformation
John McCormick, Tennent Institute of Ophthalmology, Glasgow, UK.

» From the leader
in Slit Lamp Imaging «

IMAGING SOLUTIONS
Professional photography

Excellent Optics – more details.
Haag-Streit imaging slit lamps combine the latest imaging technology with the proven versatility, optical brilliance and mechanical quality of the Haag-Streit tradition.

Easy Capturing – efficient workflow
With the History Trigger, Freeze Technology and the Easy Touch Release Module, Haag-Streit Slit Lamp imaging equipment provides ergonomic handling and easy picture acquisition.

Perfect Integration – best information sharing
With EyeSuite software, Haag-Streit imaging solutions are fully networkable and allow full real-time access to all data in a practice.

www.haag-streit.com

HAAG-STREIT DIAGNOSTICS

Anterior Segment

Supported by

HAAG-STREIT DIAGNOSTICS

Anterior Uveitis

By John McCormick, photographed with the Haag-Streit BX 900 Slit Lamp.

Ophthalmic Diagnostic & Clinical Imaging,
Tennent Institute of Ophthalmology
Gartnavel General Hospital, Glasgow, Scotland.

Missed Appointments

This patient was first diagnosed with a choroidal melanocytoma. The patient did not return to the clinic for three years until one month when he lost vision on and off several times a day. The flat melanocytoma had progressed to a large, mushroom-shaped tumor. The tumor's location meant that radiotherapy was contraindicated. Enucleation was performed, and the tumor was confirmed to be uveal melanoma.

Matt Poe is a certified ophthalmic assistant working towards certification in retinal angiography. He runs the ophthalmic imaging site www.ophthalmicphotography.info.

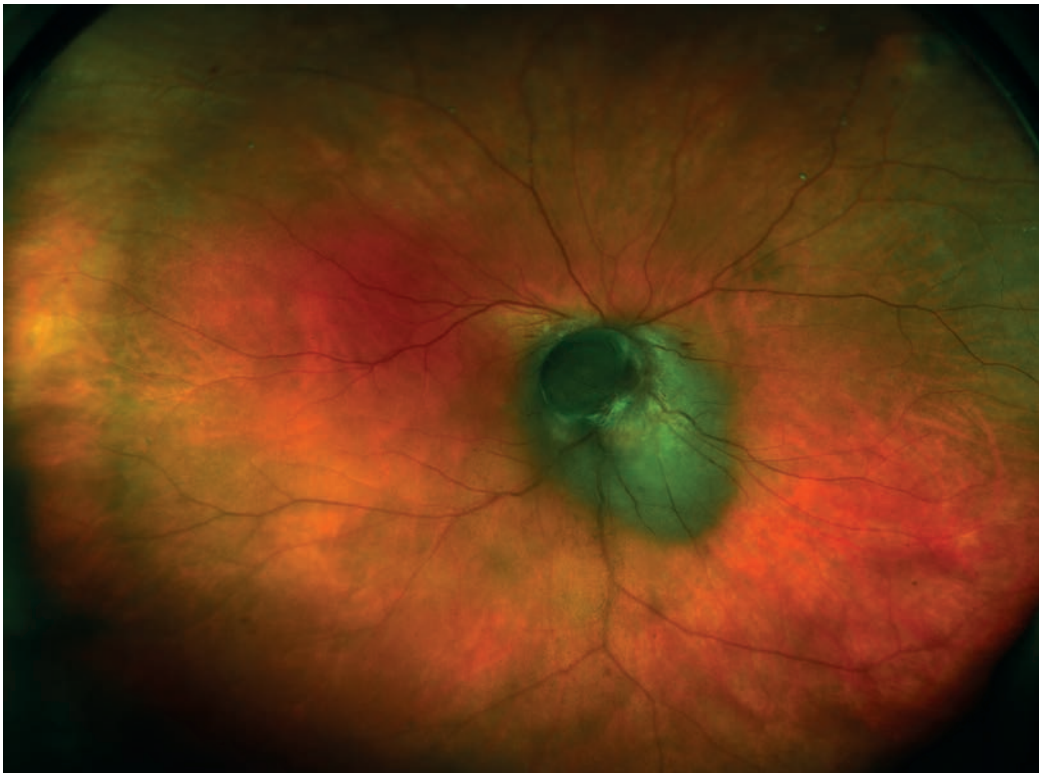

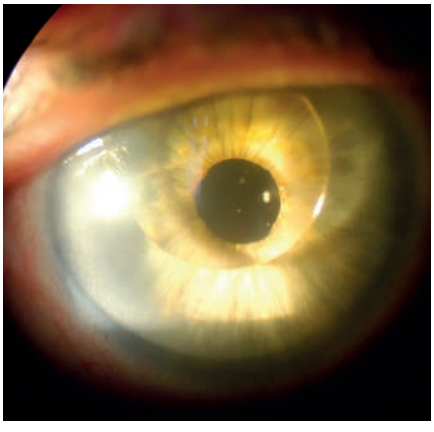

Magnification by oil

Bubble of silicon in the anterior chamber.

Amra Nadarevic Vodencarevic, Resident Ophthalmologist, University Clinic Center Tuzla, Bosnia and Herzegovina.

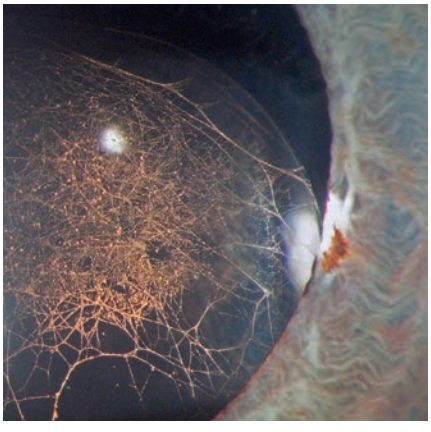

A Spider's Web?

Fibrin web formation with pigment deposition on a decentered posterior chamber lens implant.

Angela Chappell is an ophthalmic photographer at Flinders Medical Centre, Adelaide, South Australia. Images copyright: Flinders Centre of Ophthalmology.

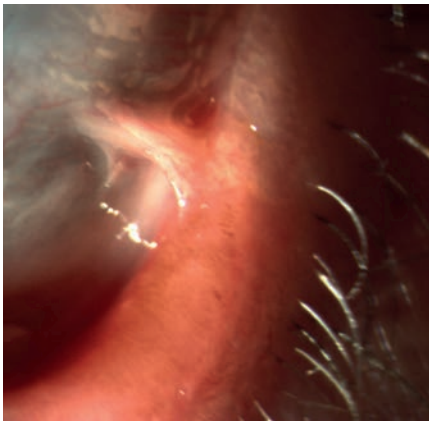

Dangerous Liaisons

Simblepharon in a Lyell syndrome case: lower eyelid and inferior bulbar conjunctival adhesion.

Helena Prior Filipe is a consultant ophthalmologist at the Instituto Dr Gama Pinto, Lisbon, Portugal

The Shard (right)

Anterior segment OCT of glass penetrating the anterior chamber.

Tarun Arora, senior resident, the Rajendra Prasad Centre for Ophthalmic Sciences, All India Institute of Medical Sciences, New Delhi, India.



Dust Clouds From Above (below)

This patient presented to our clinic after a routine exam with a shopping center optometrist. The patient explained that the growth had been present since he was an infant and had changed very little throughout his life. The diagnosis was a non-malignant congenital anomaly of the iris and will be monitored every 6 months.

Carrie A. Cooke is an ophthalmic photographer with the University of Texas Health Science Center San Antonio, Medical Arts and Research Center, Department of Ophthalmology.

California

Optos introduces its latest ultra-widefield (UWF™) imaging device, California which is specifically designed for vitreo-retinal specialists and ophthalmologists. California includes a new UWF optomap® imaging modality, Indocyanine Green angiography (*icg*) while retaining composite colour, red-free, autofluorescence (*af*) and Fluorescein angiography (*fa*).

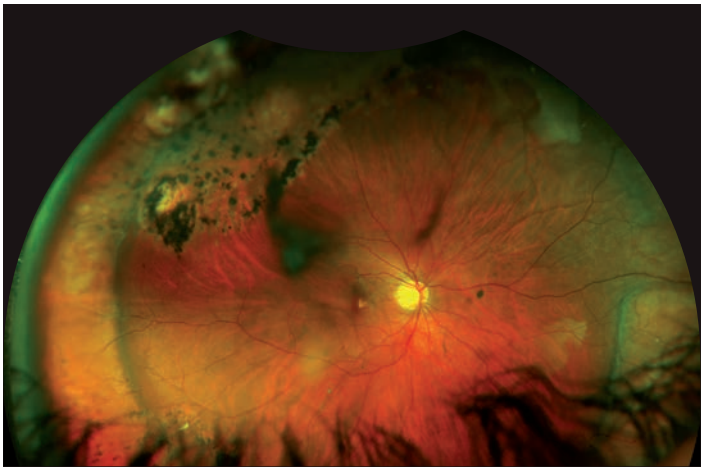

optomap *plus*

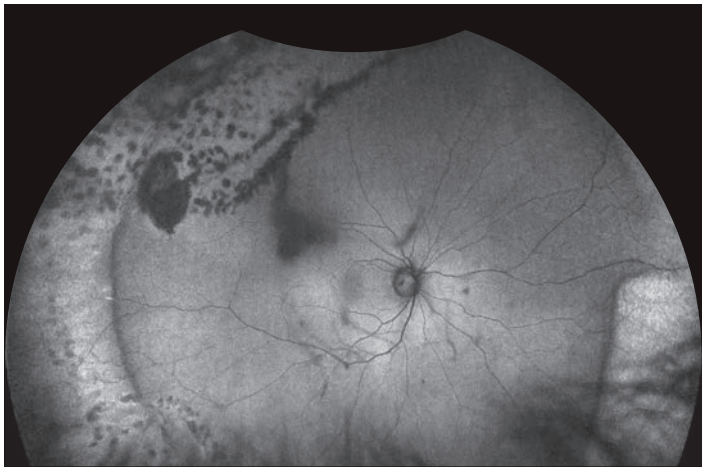

optomap *af*

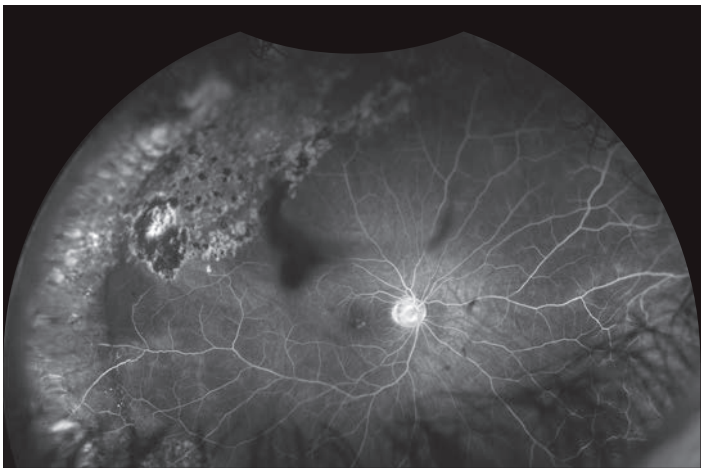

optomap *fa*

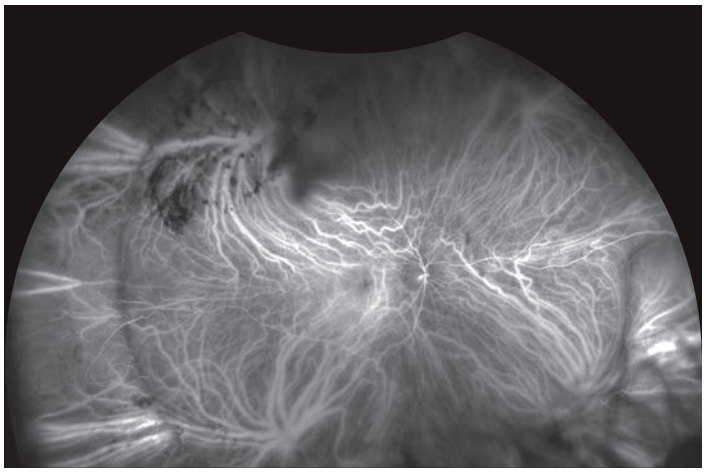

optomap *icg*

Images courtesy of SriniVas Sadda, MD
Doheny Eye Institute

California was designed as a compact, table-top model to reduce space requirements. Further, the new design leads to ease of use and faster image capture.

Non-mydriatic high resolution imaging through many cataracts and/or 2mm pupils saves time in busy practices.

Comprehensive retinal analysis through multiple wavelengths and image modalities, all in UWF (views of 200 degrees or up to 82% of the retina in one single capture).

www.optos.com

optos® Ophthalmology

Building *The* Retina Company

Images of the Posterior Segment

Supported by

optos®
Building The Retina Company

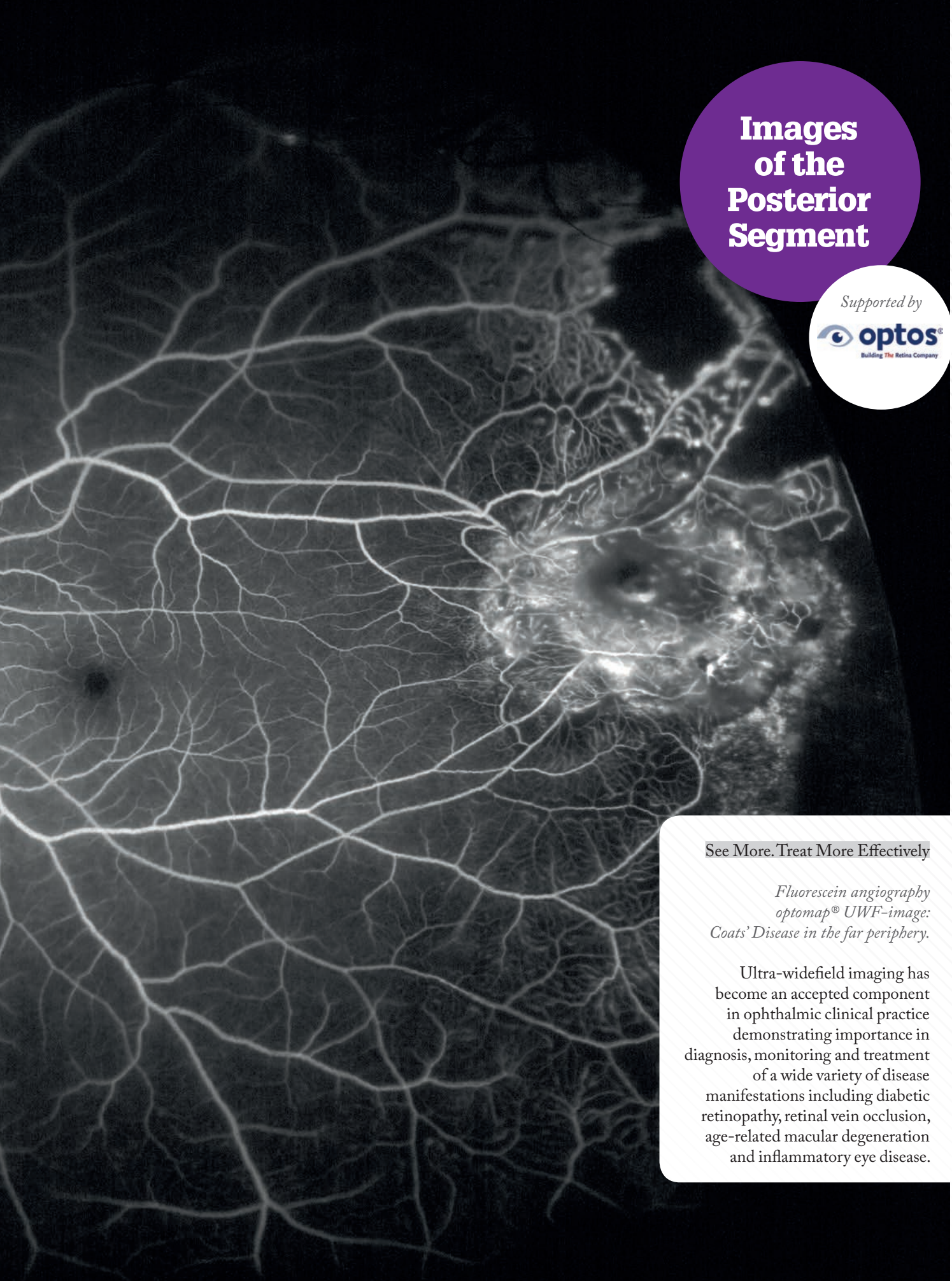

See More. Treat More Effectively

Fluorescein angiography optomap® UWF-image: Coats' Disease in the far periphery.

Ultra-widefield imaging has become an accepted component in ophthalmic clinical practice demonstrating importance in diagnosis, monitoring and treatment of a wide variety of disease manifestations including diabetic retinopathy, retinal vein occlusion, age-related macular degeneration and inflammatory eye disease.

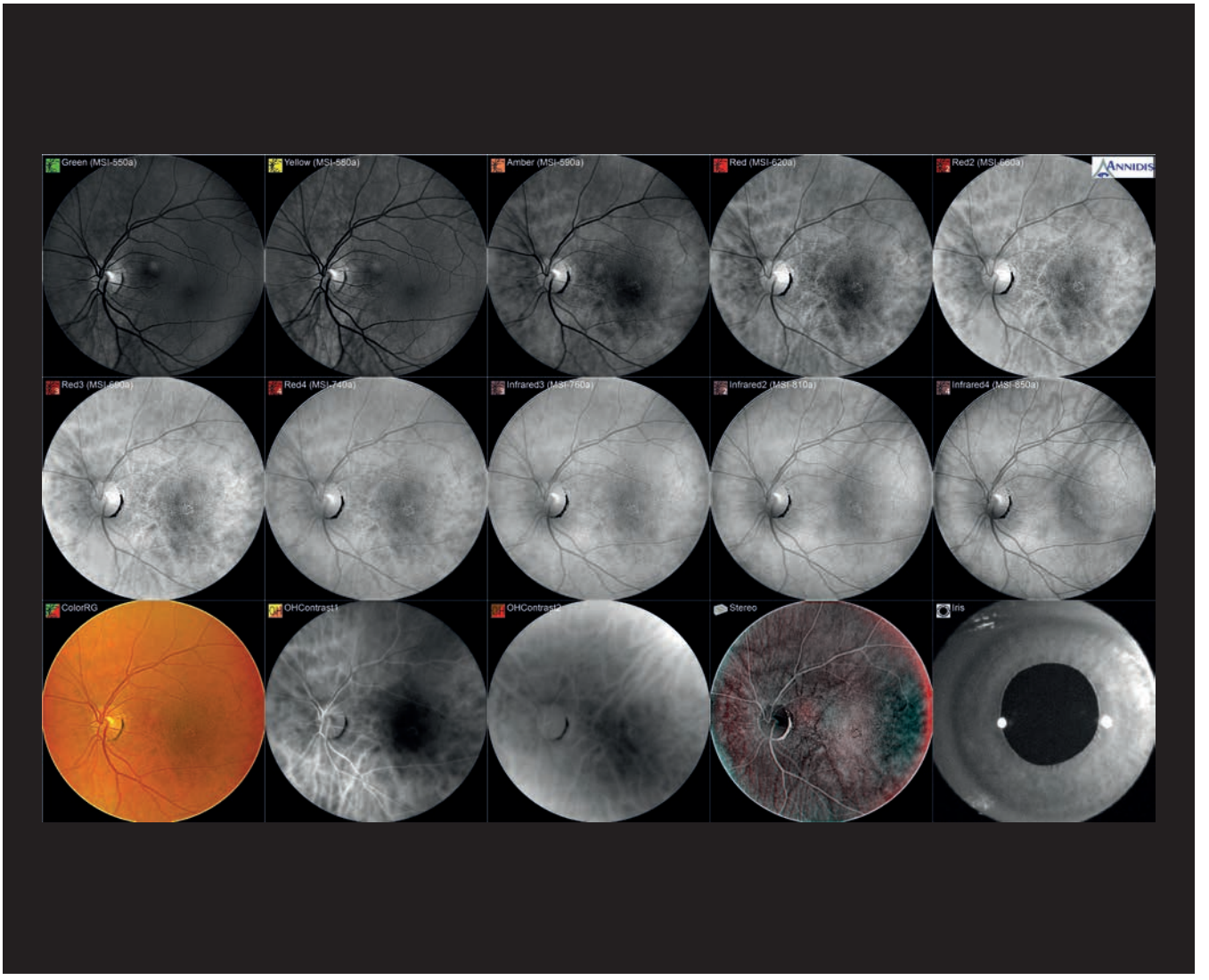

Revealing All

Multispectral imaging (MSI) can reveal more information about a patient's retina than fundus cameras or scanning laser ophthalmoscopes. This MSI image set (Annidis RHA) shows the changing absorption spectra and spectral sensitivity of retinal structures, as observed in the image sequence of a patient with early RPE disease. The wavelengths beyond 600 nm enhance the visualization of RPE retinal structure and melanin is the dominant retinal pigment. With longer wavelengths, 620 nm to 740 nm (red and deep reds), we can observe window defects within the RPE with a maximum visibility of melanin stacking (dark spots) at 620 nm for this patient without observation of any drusen. The Annidis RHA is a multispectral imaging instrument that utilizes safe light emitting diodes with a wavelength emission range of 500 nm to 850 nm in order to progressively examine the different layers of the retina from the internal limiting membrane to the choroid.

Carl Glittenberg, CEO of Glittenberg Medical Visualization.

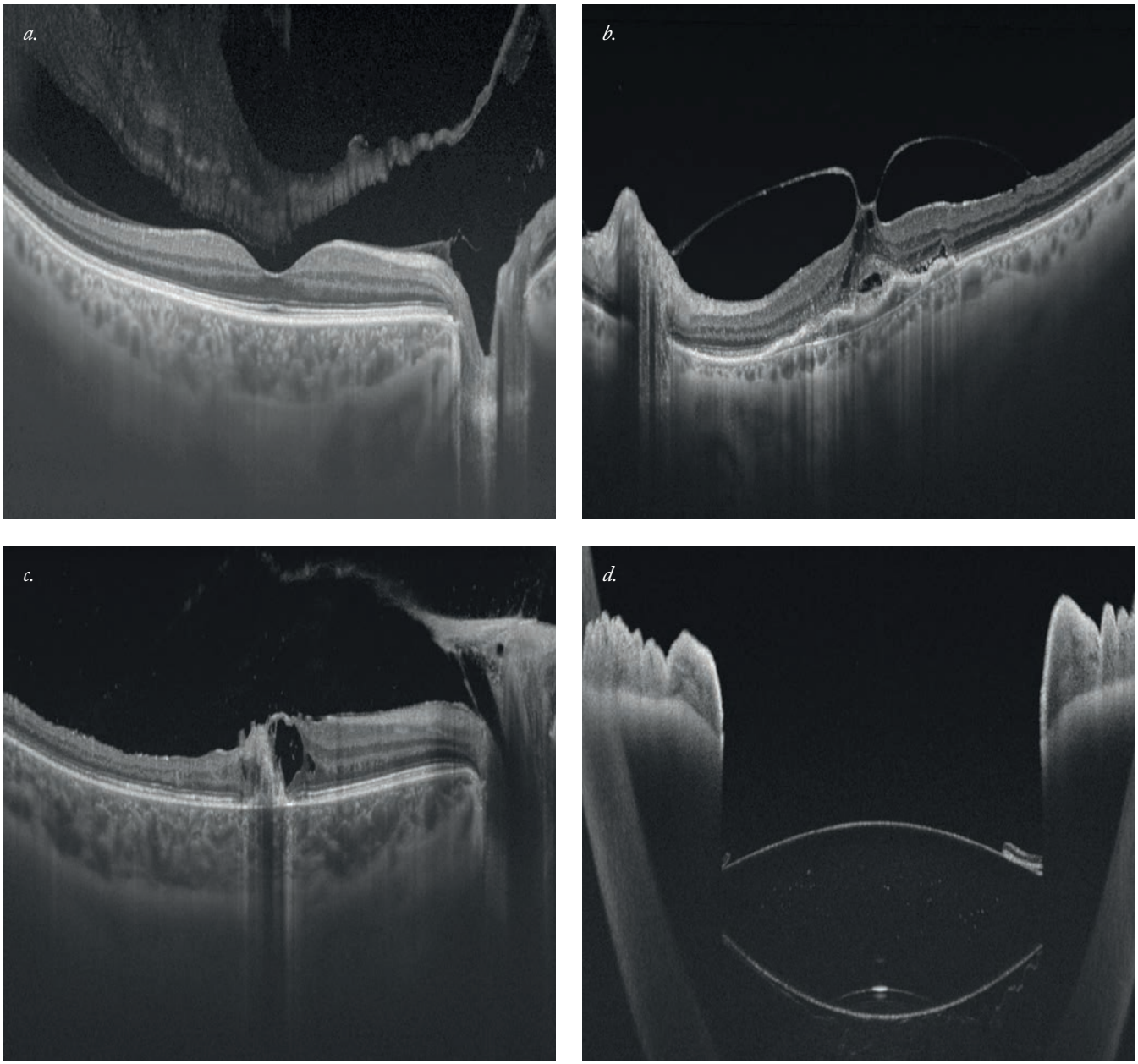

From the Vitreous to the Choroid

Swept source OCT images (Topcon DRI Atlantis). a. Healthy patient with a visible bursa premacularis in the vitreous above the macula, displaying clear definition of both the choroid and vitreous in one image. b. Vitreomacular traction syndrome (VMTS). Full extent of the VMTS is visible due to large scan width (12 mm). c. Vitreoretinal traction in a patient with posterior uveitis, with clear definition of the choroid and vitreous in one image. Again, the large scan width (12 mm) enabled the full extent of the lesion to be visualized. d. Iris and multifocal IOL: the swept source technology permits the large scan depth visualized.

Tim Cole (a); Carl Glittenberg (b–d).

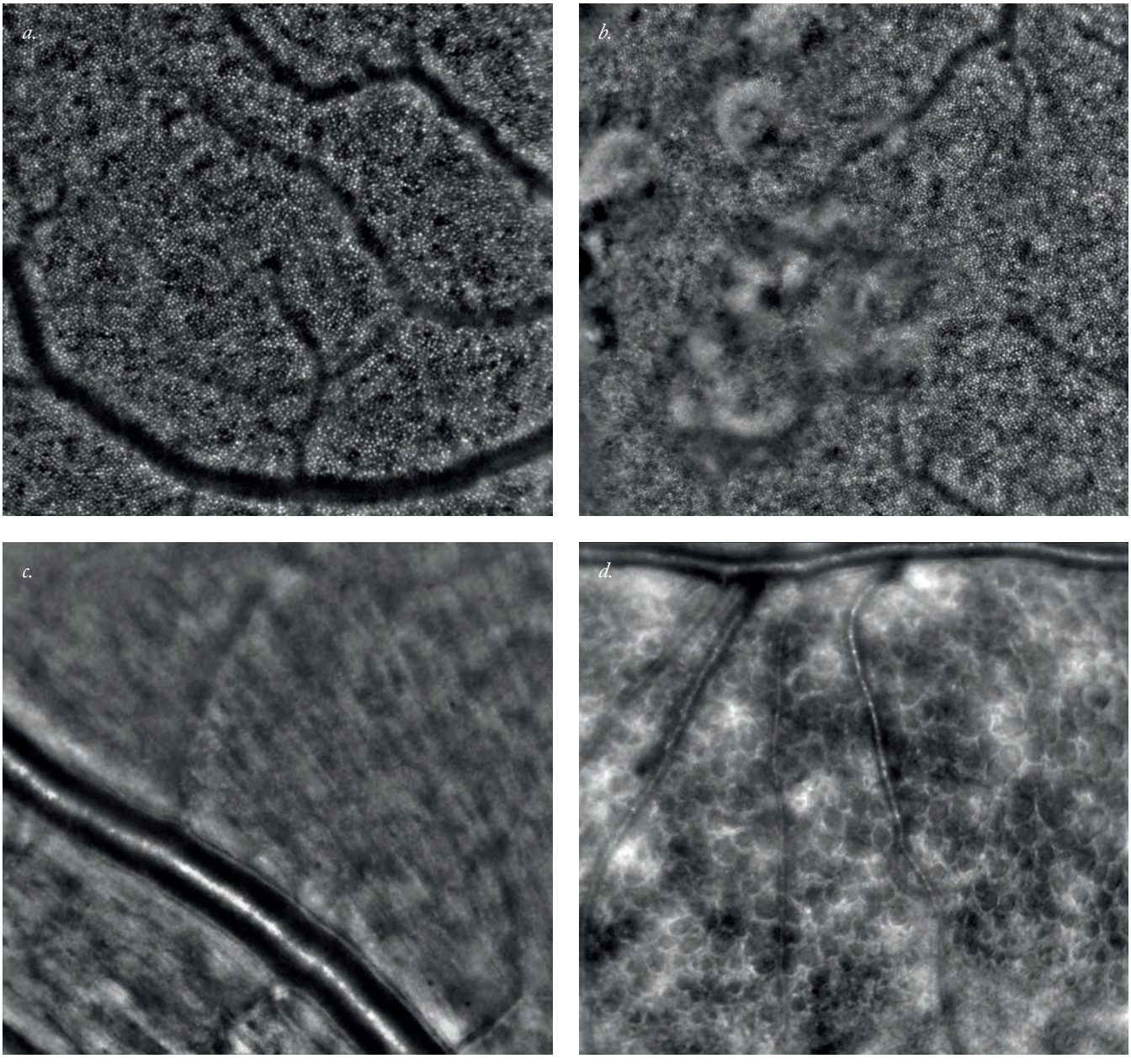

An Adaptive Optics Adventure (Part 1)

Fundus adaptive optics retinal camera images. a. Cone photoreceptors; b. Reticular drusen; c. Retinal arterioles; d. Microcystic macular edema in a case of autosomal dominant optic atrophy (ADOA).

a. Imagine Eyes; b. K . Gocho, V. Sarda, S. Falah, J.A. Sahel, M. Benchaboune, M. Ullern, and M. Paques, Quinze-Vingts National Eye Hospital, Paris, France; c. and d. Dr Kiyoko Gocho, Nippon Medical School Hokusoh Hospital, Chiba, Japan.
Imagine Eyes.

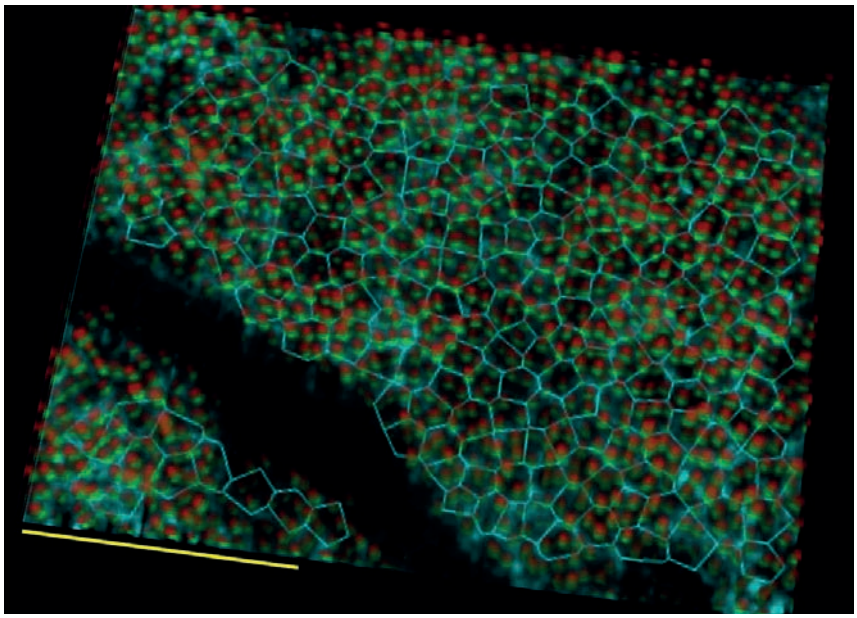

An Adaptive Optics Adventure (Part 2)

3D cellular resolution imaging of the photoreceptor-RPE complex in parafovea of a 48 year old subject, using OCT equipped with adaptive optics. Red and green spots denote reflections from opposing ends of individual cone photoreceptor outer segments. A Voronoi map of the underlying RPE cells (cyan) is superimposed and enables the number of cones per RPE cell to be computed.
Scale bar is 100 microns.

Zhuolin Liu, Omer P. Kocaoglu, Tim L. Turner, and Donald T. Miller, School of Optometry, Indiana University, Bloomington, IN, USA.

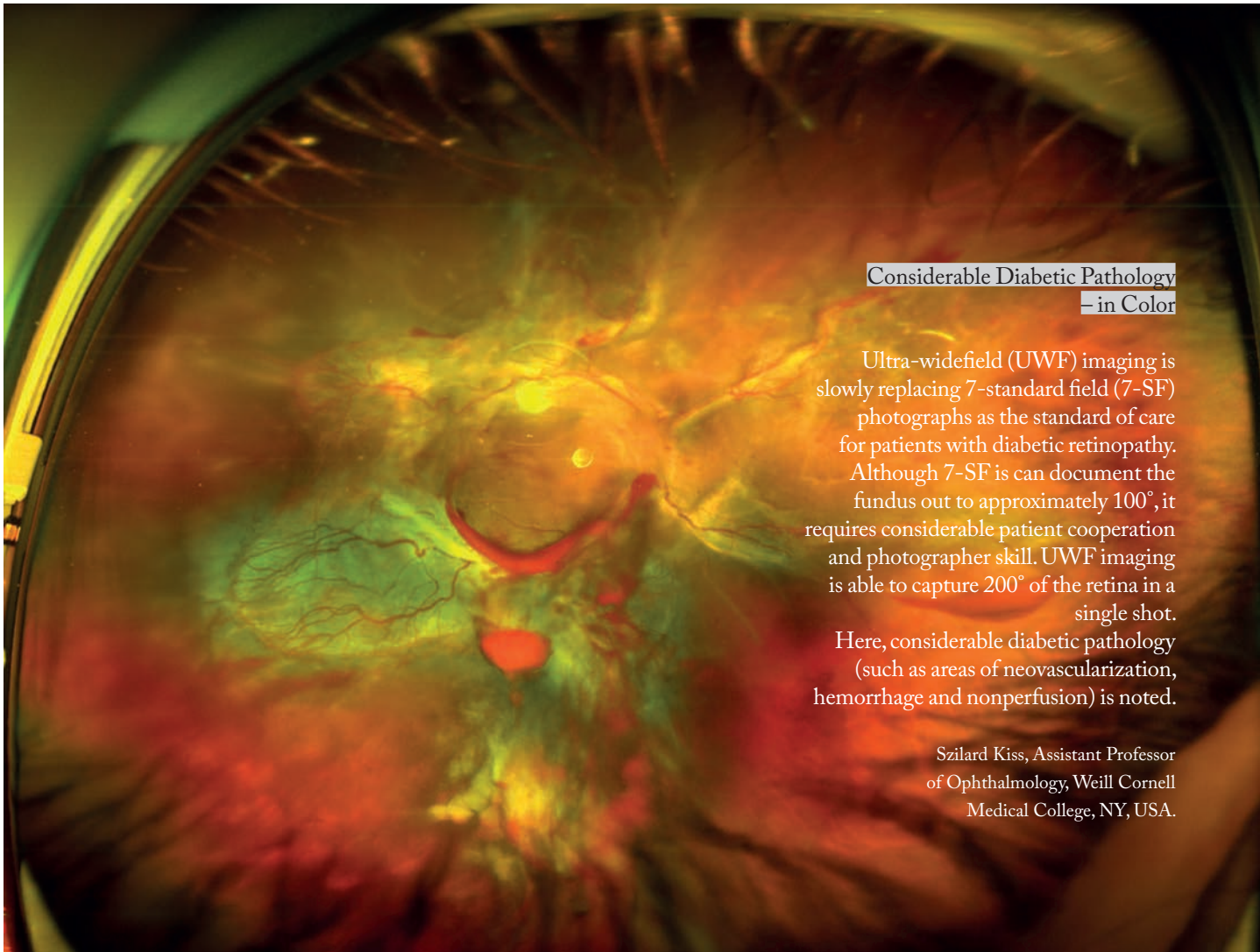

Considerable Diabetic Pathology – in Color

Ultra-widefield (UWF) imaging is slowly replacing 7-standard field (7-SF) photographs as the standard of care for patients with diabetic retinopathy. Although 7-SF is can document the fundus out to approximately 100°, it requires considerable patient cooperation and photographer skill. UWF imaging is able to capture 200° of the retina in a single shot.
Here, considerable diabetic pathology (such as areas of neovascularization, hemorrhage and nonperfusion) is noted.

Szilard Kiss, Assistant Professor of Ophthalmology, Weill Cornell Medical College, NY, USA.

A Filtered FA

A fluorescein angiogram of the right eye in a patient with central serous chorioretinopathy showing leakage. It is very unusual to see the perifoveal network in such fine detail. I have added a Photoshop filter to enhance the retinal vessels (this is not normal practice, but does give a nice effect).

Photographer: Richard Hancock, Assistant Hon. Treasurer of the Ophthalmic Imaging Society, Clinical Sciences, University Hospital Aintree, Liverpool, UK.

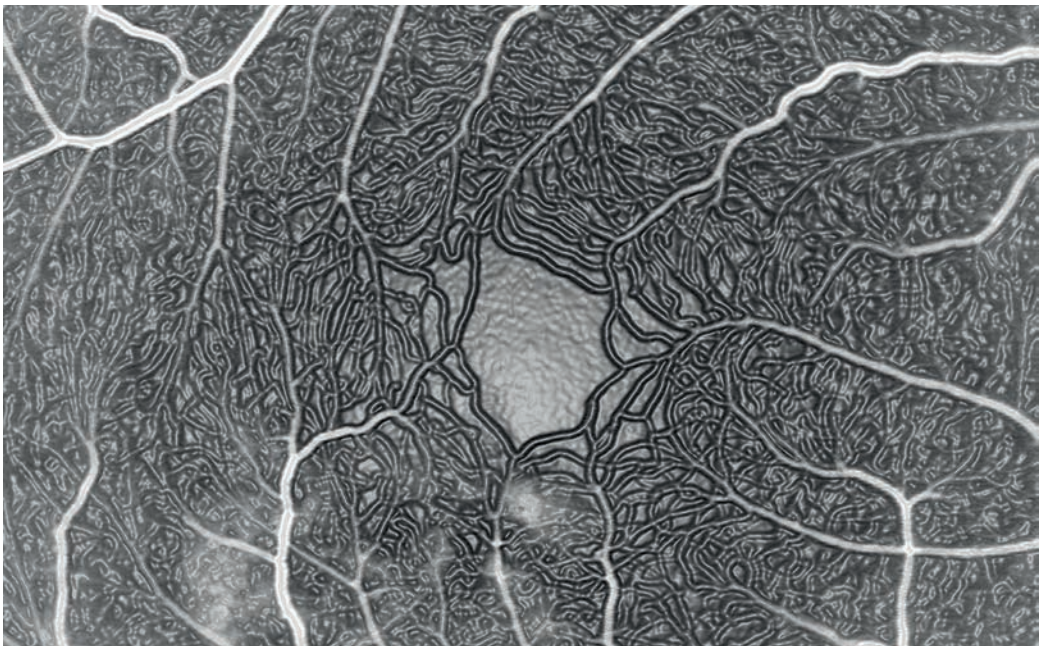

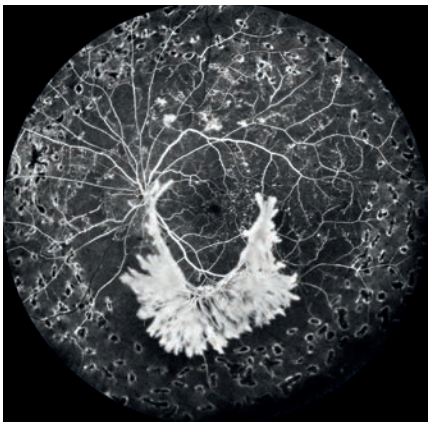

Proliferative Diabetic Retinopathy

Widefield fluorescein angiography is ideal for documenting the complexities of proliferative diabetic retinopathy. It offers the practitioner views into the far peripheral retina where capillary nonperfusion, hemorrhages and neovascularization are often present.

Photographer: Joseph G. Territo, Ophthalmic Imaging Center, Retina Associates of Western New York, Rochester, NY, USA.

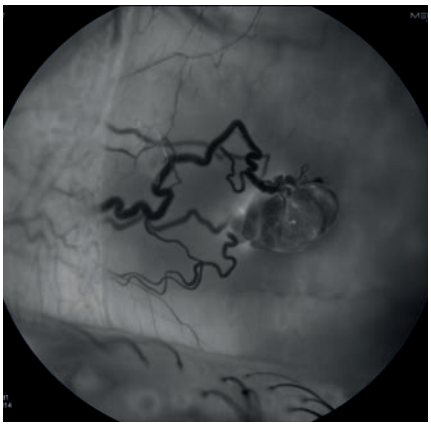

Pyogenic granuloma FA

Fluorescein angiogram of a pyogenic granuloma at 5 minutes, 40 seconds on a 30-year-old male with a complaint of left eye irritation with no vision loss. The conjunctival hemangioma was 1 mm from plica and 5 mm from the limbus (nasal). The conjunctival lesion was later removed during surgery (excisional biopsy and cryo) and the patient made a full recovery.

Photographer: Tara Farmer, Imaging Supervisor, Tennessee Retina, Nashville, TN, USA.

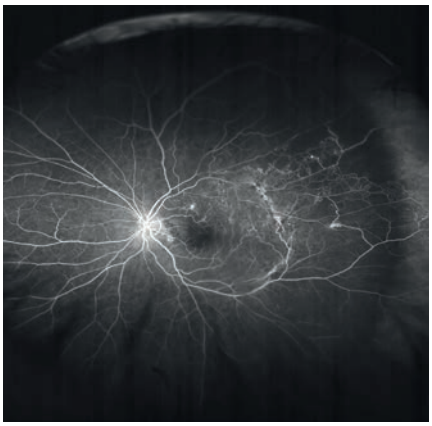

An UWF RVO

Ultra-widefield fluorescein angiography image demonstrating extensive peripheral changes associated with a retinal vein occlusion including neovascularization, nonperfusion and far peripheral leakage.

Photographer: Michael Singer, Medical Center Ophthalmology Associates, San Antonio, TX, USA.

The Art of Arterioles

Top. Noninvasive adaptive optics imaging of the retinal arteriole and venule in healthy subjects without the use of an exogenous contrast agent. a. Adaptive optics image of a 50 µm arteriole located at 5° superior retina. Vascular wall fine structure is readily seen. b. Corresponding motion contrast image indicates the perfused blood vessels. c. Superimposition of A and B. d. Adaptive optics image of a 20 µm venule located at 5° superior retina. e. Corresponding motion contrast image. f. Superimposition of D & E.

Below. Noninvasive adaptive optics imaging of a retinal microaneurysm (arrows) located at 8° superior retina in a 49-year-old nonproliferative diabetic retinopathy patient. Scale bars, 50 µm.

Richard Rosen and Toco Chui, Adaptive Optics Imaging Laboratory, New York Eye and Ear Infirmary of Mount Sinai, New York, NY, USA.

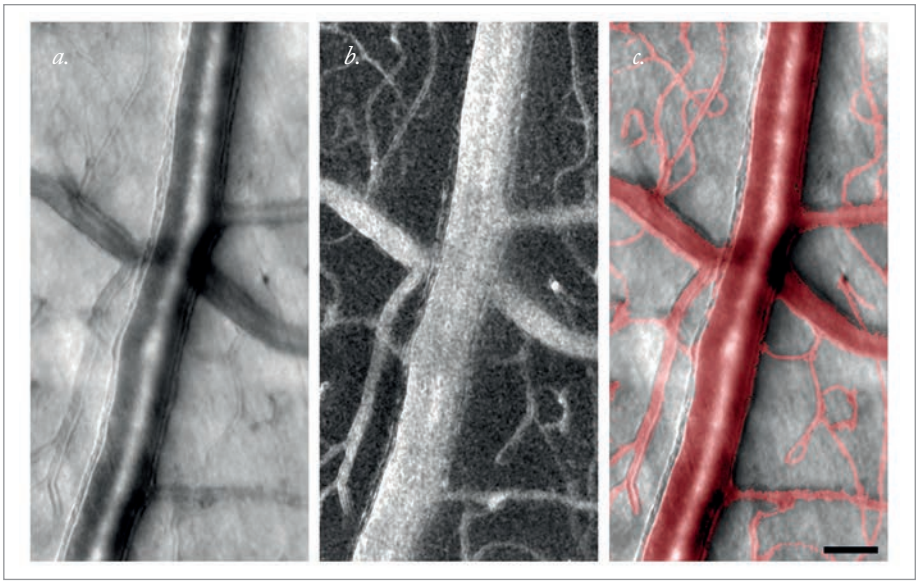

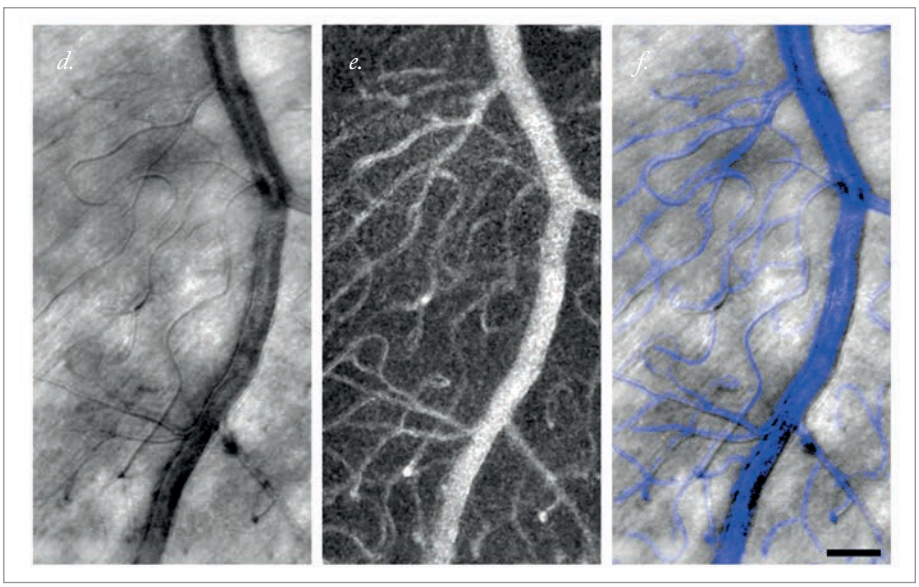

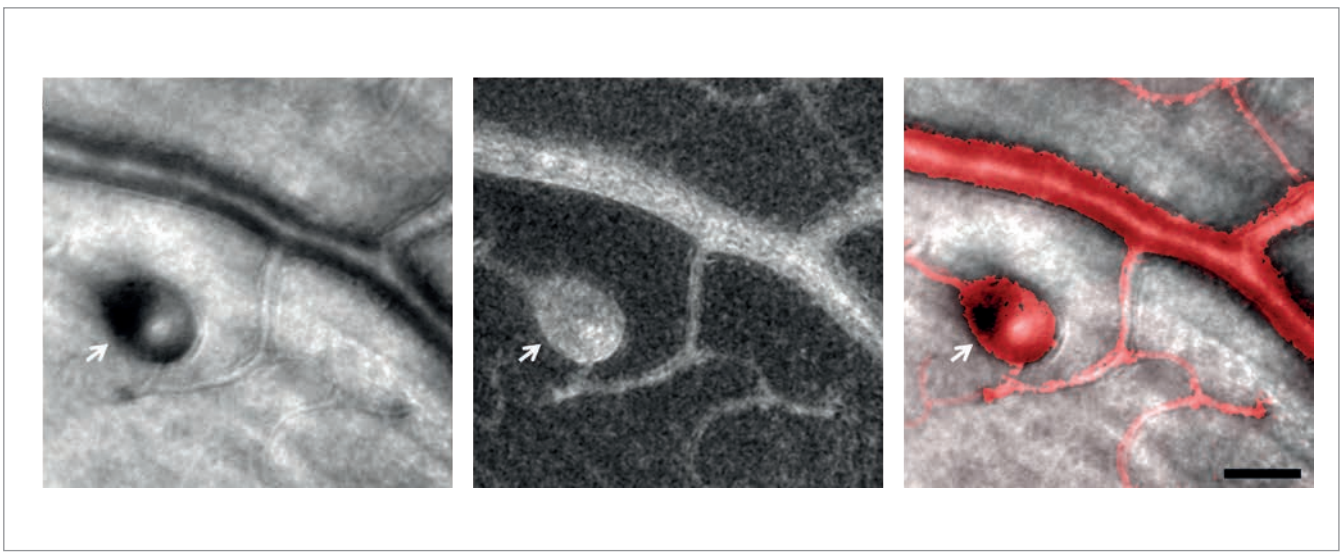

Incredible Images

Tumbling Es and Philanthropy

The Vision 2020 Links team – a group of ophthalmologists, orthoptists, and nurses from the Royal Free Hospital in London led by consultant ophthalmologist Clare Davey – went on a 10-day mission to Uganda in April. Photographs documenting that visit are inside this section (and on this page).

Photographer: Terry Cooper, Volk Optical.

Making a Difference

Checking a diabetic patient for eye disease at Mulago Hospital, Kampala, Uganda.

(Below) Laser treatment of a patient with diabetic eye disease.

Photographer: Terry Cooper, Volk Optical.



Fluorescent Keratitis

Autofluorescence of bilateral herpetic dendritic keratitis, dyed using fluorescein strips.

Image credit: Zachary Dupureur & David A Johnson.

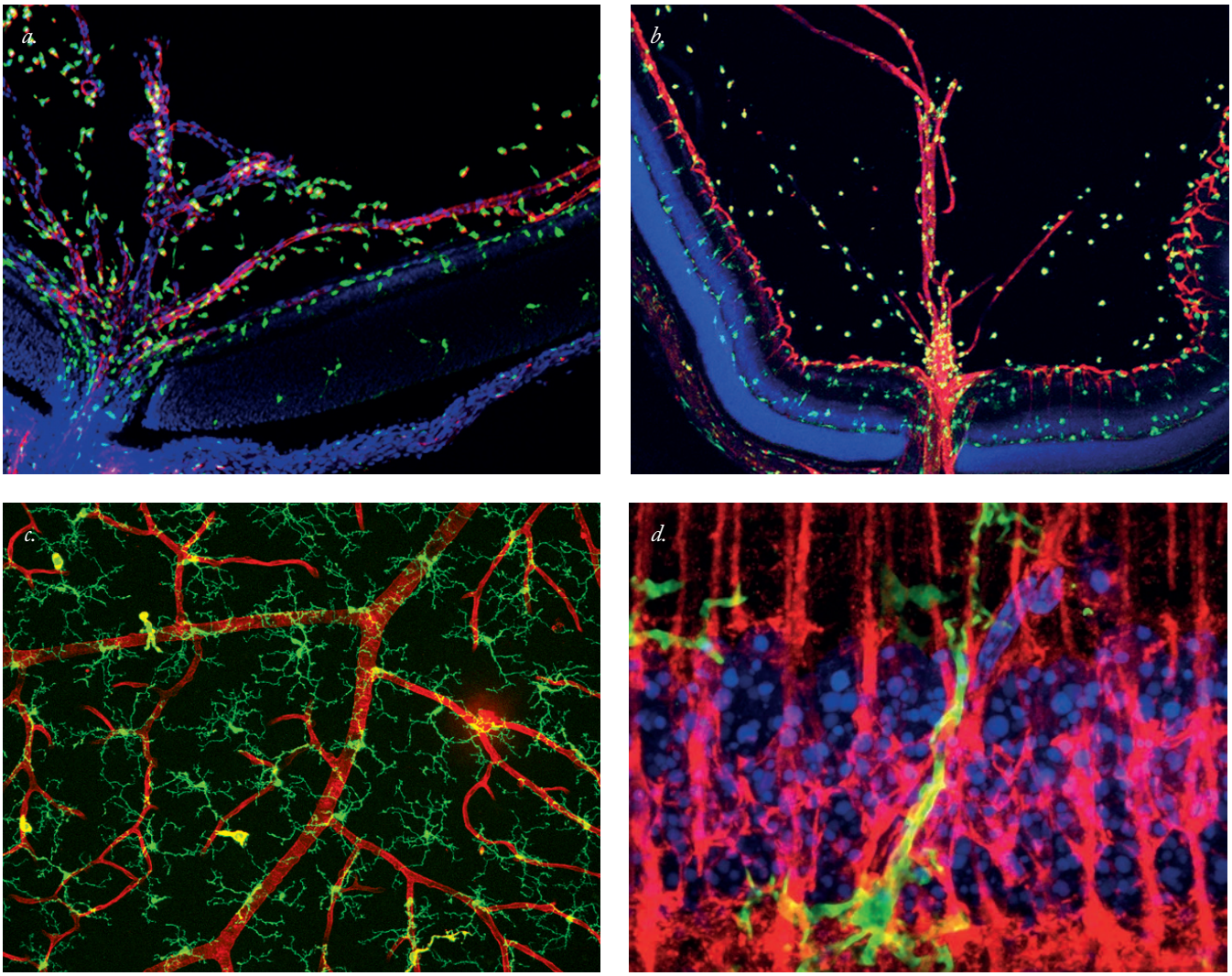

Captivating Confocal Images

a. Microglia (green) migrating into the developing retina at postnatal day 3 via the developing retinal vasculature and hyaloid vessels (red).
b. Microglia (green) migrating into the developing retina at postnatal day 7.
c. Microglia cells (green) in an en-face view of the inner plexiform layer in close proximity to retinal capillaries (red).
d. Microglial cell (green) fasciculating closely with radial Müller cell processes (red) in an endotoxin model of retinal inflammation.

Wai Wong, Chief of the Unit on Neuron-Glia Interactions in Retinal Disease, National Eye Institute, National Institutes of Health.

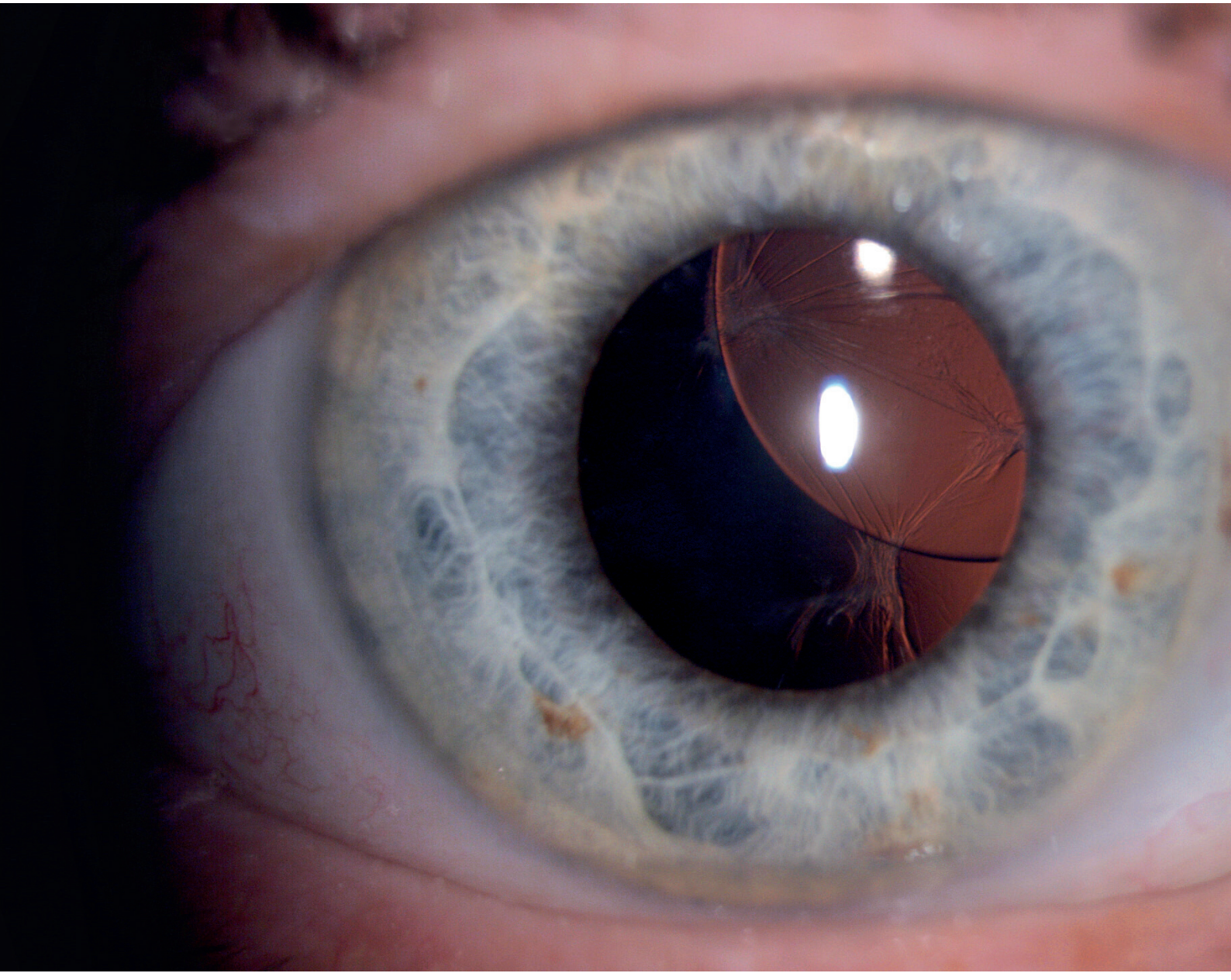

Sunrise Syndrome

An superiorly subluxated intraocular lens.

Photographer: Bohdan Kousal, Department of Ophthalmology, Charles University, Prague, Czech Republic

Introducing Ikervis

The first and only EU-approved ciclosporin eyedrop has arrived – what does this mean for patients with severe keratitis in dry eye disease?

There's currently a considerable unmet need amongst people with severe dry eye disease (DED): obtaining effective treatment (1). Diagnosis can be challenging when a significant proportion of patients with DED present with discordance between signs and symptoms (2) although thankfully, improved diagnostic algorithms and questionnaires are helping to identify more of those patients with the severe forms of the disease who are in need of an intervention (3).

But what are those interventions? Unlike milder forms of DED that can be managed with tear substitutes, lubricant drops or gels for symptom relief, more severe forms of DED are driven by a vicious circle of inflammatory processes that need something more than artificial tears to dampen the disease (4). Without causal treatment, this vicious circle can lead to severe damage to the corneal epithelium (5). Corticosteroids can perform that function, but have a poor side effect profile (especially with chronic use), and risk raising patients' intraocular pressure or inducing cataract formation (6).

The other way to dampen inflammation is to use ciclosporin-containing eyedrops (7), but this has been a challenge in the EU so far due to the absence of an approved, commercially available product.

That was yesterday's challenge. Ikervis, 1 mg/mL ciclosporin (Santen) has recently received marketing approval in the EU for the "treatment of severe keratitis in adult patients with dry eye disease, which has not improved despite treatment with tear substitutes" (8–10). The posology is simple: a single drop into each affected eye once daily at bedtime (8). Ikervis has a three-year shelf-life, is supplied in single-dose containers (8), and Ikervis is now approved for use in the EU.

The formulation is worth a closer look. Ikervis is a cationic oil-in-water emulsion of ciclosporin, based on Santen's Novasorb technology (11). The positively charged nano-sized droplets of the emulsion electrostatically adhere to the negatively charged mucins on the ocular surface, thereby improving ocular retention and absorption (Figure 1), and the lipids in the formulation support the stabilization of the tear film, too (11). The fact that the droplets are nano-sized is important: as droplet size reduces, the surface area to volume ratio increases, meaning a greater total surface area of the emulsion is exposed to the ocular surface – in essence, the eye "sees" more of the eyedrop. This has been demonstrated in rabbits (12) – Ikervis (1 mg/mL ciclosporin) administration results in corneal ciclosporin concentrations around four times greater than that of an anionic emulsion of 0.5 mg/mL ciclosporin. That is why the innovative cationic formulation of Ikervis makes once-a-day dosing possible (8).

Ikervis' regulatory approval was based on the results of its clinical trial program, which enrolled 982 patients in total. All studies were multicenter, randomized, controlled, double-blinded comparisons of ophthalmic cationic emulsion of ciclosporin versus vehicle control, i.e., versus cationic emulsion without any pharmaceutically active ingredient (9,13).

SANSIKA, the pivotal phase III study, was a 12-month trial that enrolled 246 DED patients with severe keratitis (defined as a corneal fluorescein staining [CFS] score of 4 on the modified Oxford scale). SICCANOVE was a 6-month trial that enrolled 492 DED patients with moderate to severe keratitis (CFS score of 2 to 4). Both studies showed that treatment with Ikervis was associated with significant improvements in CFS from baseline values and versus vehicle control, and an exploratory analysis in SANSIKA performed at month 6 found that ocular surface inflammation (as determined by human leukocyte antigen-DR expression) was significantly lower ($p=0.021$) in Ikervis-receiving patients than those receiving the vehicle control (10).

In general, Ikervis is safe and well-tolerated – even with long-term treatment. But there are two things patients should be informed about. The active ingredient, ciclosporin, gives rise to the therapy's most common side effect: eye pain or irritation (8) – often described by patients as a burning sensation upon instillation. However, this is normally mild-to-moderate in intensity (8). Secondly, patients need to be aware that it will take some time before their ocular surface disease starts to improve – Ikervis' effects aren't immediate, but over the longer term, it's effective in reducing ocular surface damage and inflammation, and may prevent DED from worsening (10).

Ultimately, the introduction of Ikervis onto the European market means three things. First, unlike artificial tears and lubricants, Ikervis addresses the underlying inflammatory processes present in severe keratitis in DED. Second, its formulation requires no refrigeration (since it can be stored at room temperature) and has a three-year shelf-life (8). And finally, it is the only approved topical formulation of ciclosporin available commercially in Europe today – bringing a novel treatment option to patients with severe keratitis in DED who, until now, had no access to this treatment option.

References:

1. *PA Asbell, S Spiegel, "Ophthalmologist perceptions regarding treatment of moderate-to-severe dry eye: results of a physician survey", Eye Contact Lens, 1, 33–38 (2010).*

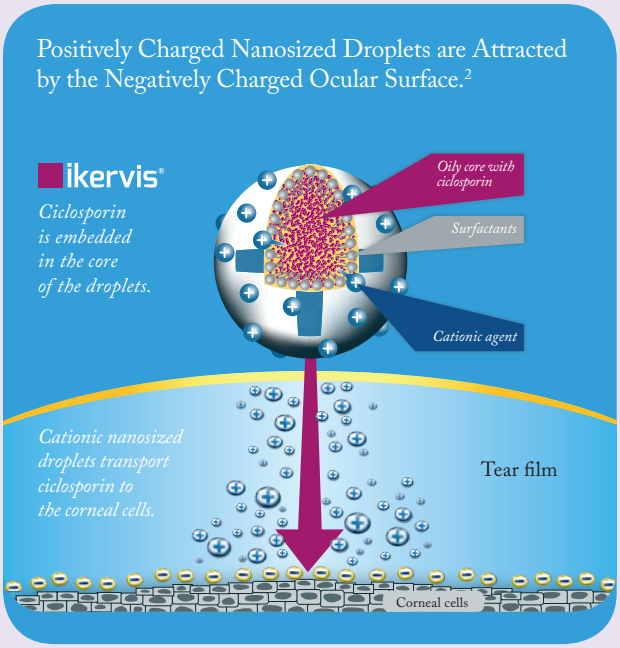

Figure 1. Why the Novasorb cationic nanoemulsion matters – electrostatic attraction to the surface of the cornea means that once-daily Ikervis dosing is possible.

2. *ME Johnson, "The association between symptoms of discomfort and signs in dry eye", Ocul Surf, 7, 199–211 (2009).*
3. *C Baudouin, et al., "Diagnosing the severity of dry eye: a clear and practical algorithm", Br J Ophthalmol, 98, 1168–1176 (2014).*
4. *DEWS. "Diagnostic methodology of the International Dry Eye WorkShop", Ocul Surf, 5, 108–152 (2008).*
5. *C Baudouin, "The vicious circle in dry eye syndrome: a mechanistic approach", J Fr Ophtalmol, 3, 239–246 (2007).*
6. *SC Pflugfelder, "Antiinflammatory therapy for dry eye", Am J Ophthalmol, 137, 337–342 (2004).*
7. *E Donnenfeld, SC Pflugfelder, "Topical ophthalmic cyclosporine: pharmacology and clinical uses", Surv Ophthalmol, 54, 321–328 (2009).*
8. *IKERVIS 1 mg/mL eye drops, emulsion. Summary of product characteristics. Available at: http://bit.ly/ikervis. Accessed May 15, 2015.*
9. *European Medicines Agency. IKERVIS Public Assessment Report. EMA/CHMP/473489/2014. Available at: http://bit.ly/ikervisEPAR. Accessed May 15, 2015.*
10. *European Medicines Agency, EPAR summary for the public, EMA/56994/2015. Available at: http://bit.ly/ikervisEPARsummary. Accessed May 15, 2015.*
11. *F Lallemand, et al., "Successfully Improving Ocular Drug Delivery Using The Cationic Nanoemulsion, Novasorb", J Drug Delivery, 2012:604204 (2012).*
12. *P Daull, et al., "Distribution of cyclosporine A in ocular tissues after topical administration of cyclosporine A cationic emulsions to pigmented rabbits", Cornea, 32, 345–54 (2013).*
13. *RR Buggage, et al., "The effect of Cyclokat (unpreserved 0.1% cyclosporine cationic emulsion) on corneal involvement in patients with moderate to severe dry eye disease participating in a phase III, multicenter, randomized, controlled, double-masked, clinical trial", Eur J Ophthalmol, RFCOR-115, SOE, Geneva, Switzerland (2011).*

New OCULUS Smartfield

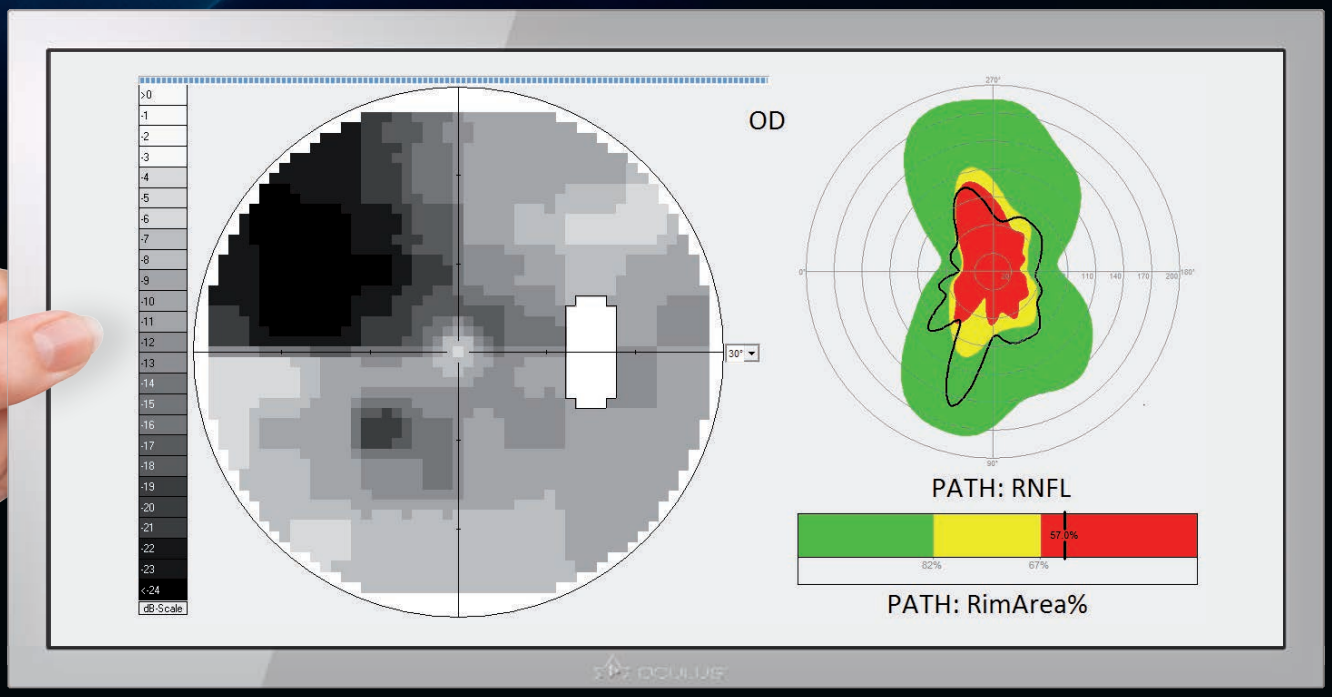

Please note: The availability of the products and features may differ in your country.
Specifications and design are subject to change. Please contact your local distributor for details.

Take the smart approach to visual field testing!

World Premiere at the
6th World Glaucoma Congress, Hong Kong

New OCULUS Smartfield: The modern device for standard automated perimetry

- SPARK – Threshold test in only 3 minutes
- TNT (Threshold Noiseless Trend) – Progression analysis
- PATH – Predictive function-structure display

www.oculus.de

OCULUS®

In Practice

Surgical Procedures
Diagnosis
New Drugs

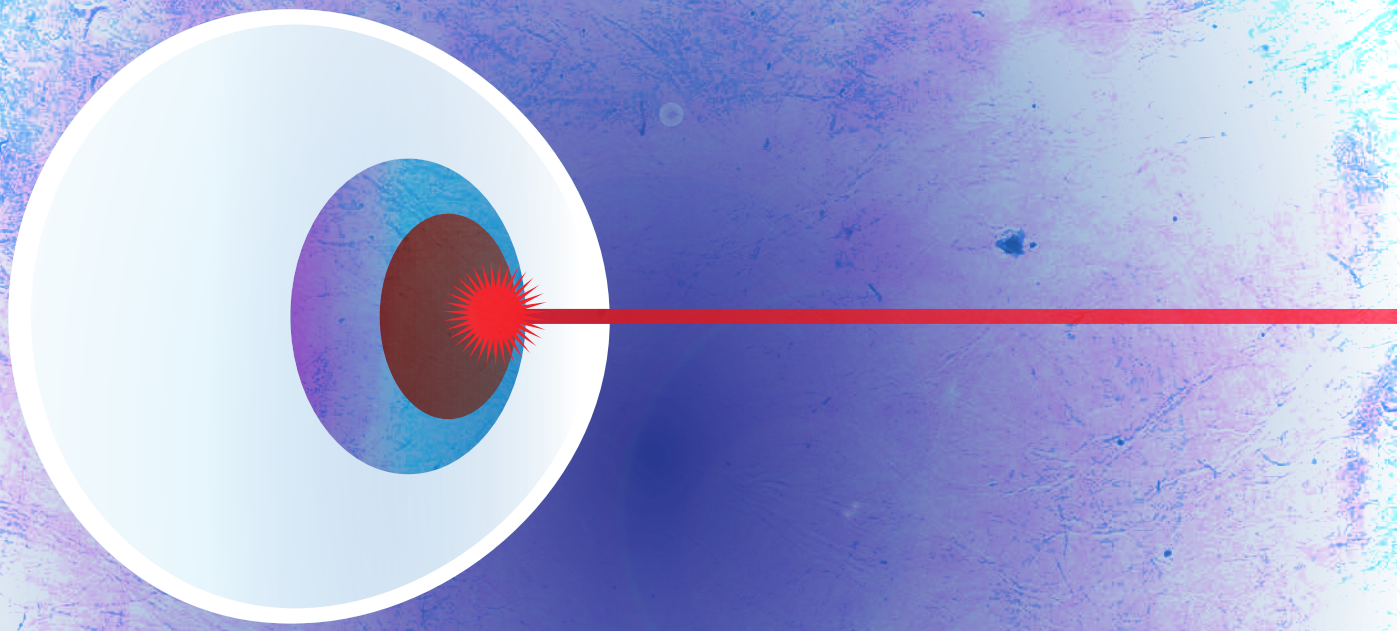

Venturing Into Venturi

Maximizing the advantages of femtosecond laser-assisted cataract surgery

By Wendell J. Scott

Just over a decade ago, most cataract surgeons operated entirely with manual incisions, and a large proportion of them would have performed phacoemulsification with a balanced salt solution (BSS) irrigation and aspiration using a peristaltic pump controlled with a foot pedal. Today, for many, it's a different story. If a femtosecond laser is used, it can not only perform the rhexis, but also pre-fracture the clouded lens, making it far easier to aspirate the lens fragments. Often, only minimal phaco power is required. As surgical technology evolves, so do our techniques. I converted to femtosecond laser-assisted cataract surgery, and by combining it with a Venturi pump for lens removal, I've found a successful method that I now employ in all of my cataract surgery cases.

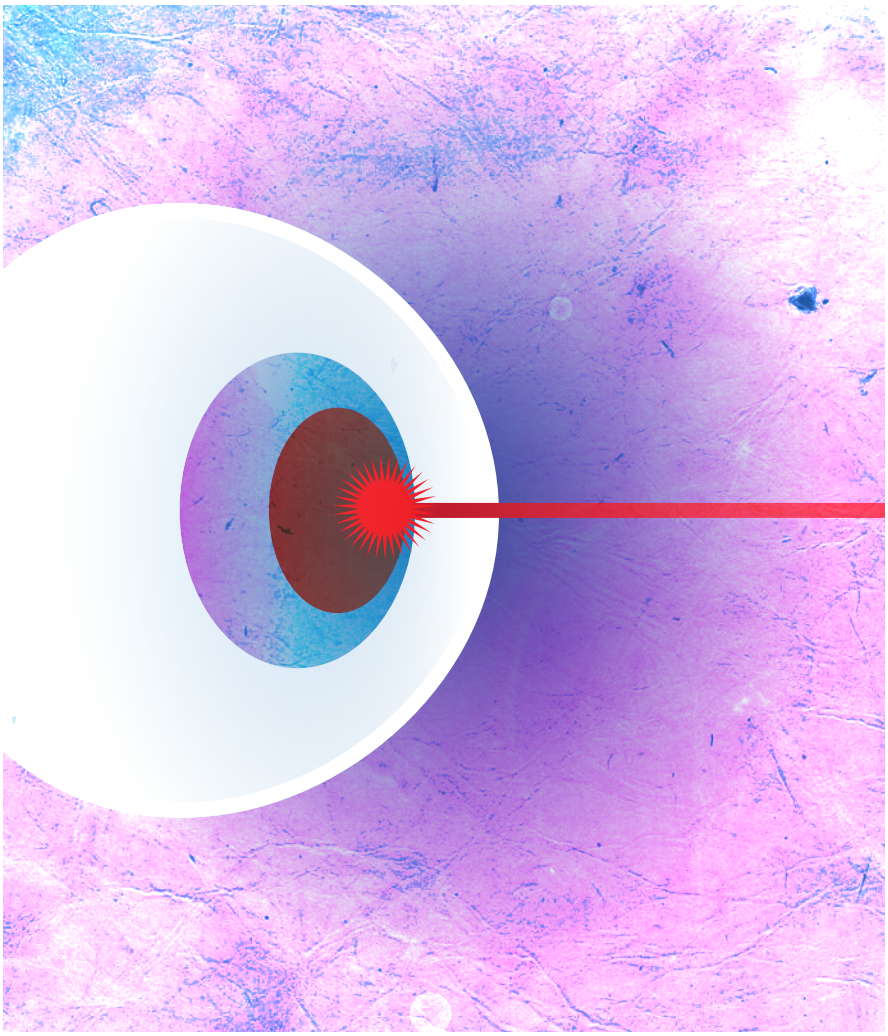

At a Glance

- *To aspirate lens fragments during cataract surgery, you need two things: balanced salt solution irrigation and vacuum for aspiration*
- *Many surgeons use peristaltic pumps, which are flow-based and require phaco tip occlusion*
- *Venturi pumps offer a way to instantly generate and control vacuum with minimal phaco energy and without the need for tip occlusion*
- *When using femtosecond laser technology for cataract surgery, Venturi pumps allow surgeons to take full advantage of the laser's fragmentation capabilities*

Back to basics

Let's go back to basics in terms of fluidics and vacuum in phaco systems. In order to aspirate lens fragments, you need two things: BSS irrigation and vacuum for aspiration. Peristaltic pumps are flow-based – they use rollers to compress the phaco outflow tubing, creating flow and vacuum. You can set the parameters beforehand, but you only get the maximal preset vacuum when the phaco needle tip is occluded with cataract material. Tip occlusion doesn't result in immediate vacuum generation, either. Rather, the vacuum builds relatively slowly, the peristaltic pump rollers slow, and the outflow level decreases. It's a nice, conservative way of aspirating the lens fragments, but it's not the fastest method out there. That title belongs to vacuum-based pumps such as Venturi or mechanical ones based on a rotary vane or diaphragm-based design. Venturi pumps exploit the Venturi effect, where a vacuum is generated by forcing pressurized air over an opening; mechanical pumps utilize either the rotary vane or diaphragm type. These configurations all operate in the same manner – the vacuum is stored in a reservoir, which can be utilized almost instantaneously by the surgeon, under the control of a foot

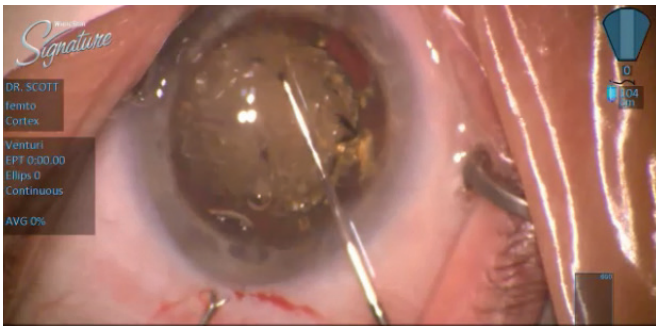

Image 1: The chop is placed distally at the capsulotomy edge along the segmentation line.

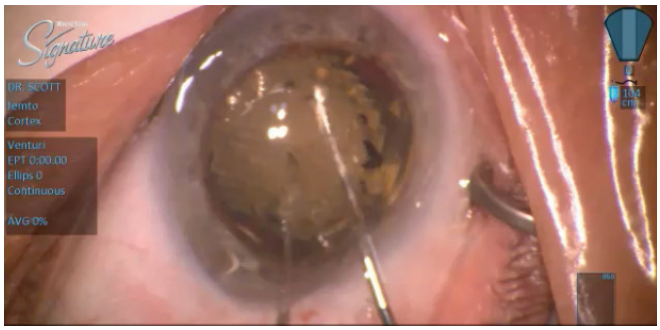

Image 2: The Bechert is placed proximally at the capsulotomy edge.

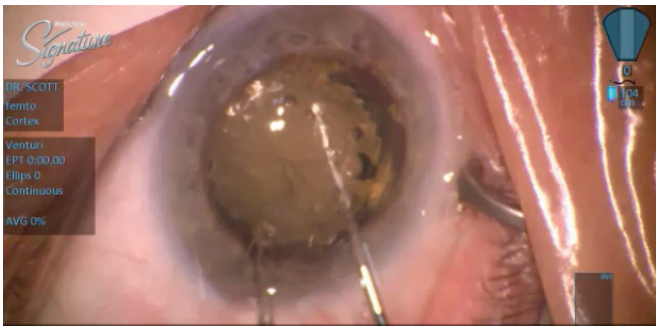

Image 3: The chop and cannula are both brought towards the center of the lens.

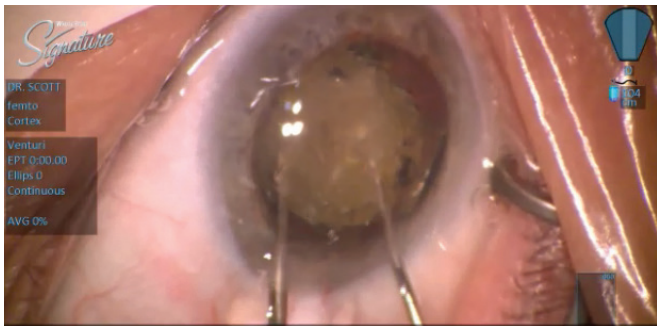

Image 4: Lateral force is applied to split the lens in two.

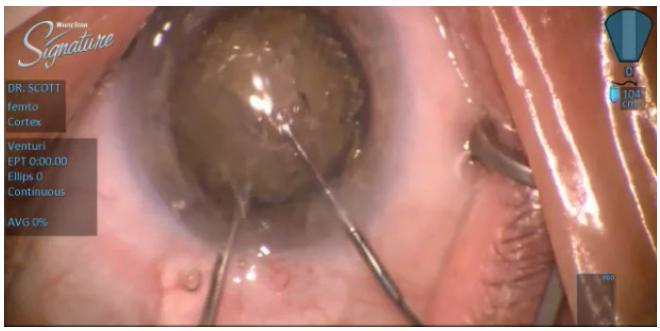

Image 5: The lens is split into quarters along the segmentation lines.

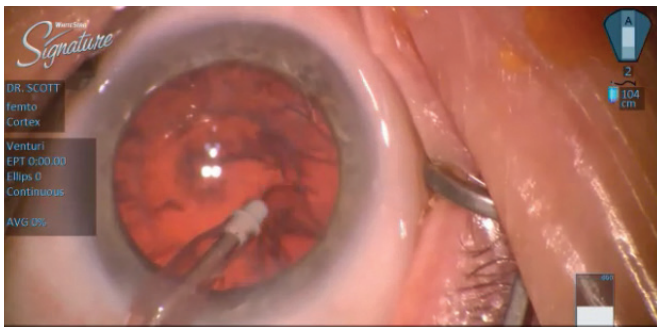

Image 6: The cortex is removed starting subincisionally

pedal – irrespective of whether or not the phaco tip is occluded. It's therefore faster, and vacuum, irrespective of occlusion, means that you're far less likely to need to chase lens fragments – more often than not, they come to you. Pairing a Venturi pump with a femtosecond laser that can perform lens fragmentation can make for a fast and effective method of phacoemulsification that requires minimal phaco (ultrasound) energy, minimizing the potential for corneal endothelial damage.

My own conversion

If you're accustomed to using peristaltic aspiration in your practice, switching to Venturi will take some adjustment. Anticipating my own conversion to laser cataract surgery, I began using AMO's WHITESTAR Signature System for my manual procedures about four months before I transitioned to femtosecond laser-assisted surgery, as it allowed me to switch between peristaltic and Venturi aspiration modes. At first, I only used the peristaltic pump mode, which I set to the familiar parameters I was already using for my quick chop technique. After I was comfortable with the machine's

"I quickly discovered it isn't phaco tip occlusion that the Venturi pump mode depends on – it's the surgeon controlling the foot pedal."

peristaltic function, I started trying the Venturi pump mode, still using the same phaco tip, sleeve and vacuum power that I was accustomed to in peristaltic mode. This let me determine the differences between the two pump modes with respect to lens removal and vacuum function. I quickly discovered it isn't phaco tip occlusion that the Venturi pump mode depends on – it's the surgeon controlling the foot pedal. Once the tip was in place, holdability was totally under my control without the limitations of peristaltic presets. I have over 25 years of experience using a peristaltic pump, but that was a new twist for me.

When I first began femtosecond laser procedures in cataract surgery, I tried using my quick chop technique to impale and split the lens, with the pump in peristaltic mode. But because the lens was no longer the same solid consistency, I had trouble gaining purchase on it. Even if you deeply sculpt the lens, it's still difficult to divide; you're pushing on the wall of the central sculpted area, but the fragmented lens doesn't offer the same level of resistance. That's what led me to develop my Femto Chop technique. Knowing how important it was to pre-chop the lens – especially for freeing and removing the first quadrant – I found that the Venturi mode was more effective than the peristaltic mode for aspirating the cataract.

Scott Femto Chop

Today, I do all of my cataract surgeries with the femtosecond laser, and I've had the opportunity to perform around 3,000 such procedures. Over time, I've developed what I believe is a highly efficient chop technique that exploits the benefits of femtosecond laser treatment and takes advantage of maximal Venturi vacuum to minimize the need for ultrasound energy.

To begin, I use the Catalys (AMO) femtosecond laser system to perform a 4.9 mm capsulotomy using customized settings, which results in a treatment time of less than one second. The speed of treatment helps minimize the potential effect of patient eye movement. By placing pressure on the center of the capsule (the "dimple-down" technique), I can confirm that the capsule is completely cut.

In a temporal approach, the Scott Femto Chop (Duckworth and Kent, Baldock, UK) or a Koch Chop is placed nasally in the segmentation line and a Bechert nucleus rotator is placed temporally just inside the capsulotomy border. I bring them toward the center of the lens. When they meet in the middle, I use both instruments to apply lateral force, moving them away from each other until the nucleus splits in two. Then I can split the lens into quarters.

Next, I insert the phaco tip and then reinsert the chop through the paracentesis. High Venturi vacuum and the chop help me to move each quadrant centrally towards the phaco tip, so that I can aspirate the cataract. As each quadrant is aspirated, the remaining lens acts as a safety barrier to separate the tip from the posterior capsule. If it becomes necessary, I might reduce vacuum and use 1 percent phaco energy on the last quadrant – but about 80 percent of cases use zero phaco energy. I use the technique I've just described for most of my cases, but I do have other methods for soft or very dense cataracts.

After removing the cataract, I use a "Venturi sweep" technique to aspirate the cortex. Starting subincisionally, I place the port slightly posterior to the capsulotomy border, facing the femto-cut cortex. Once the aspiration port engages the cortex, it is "swept," or moved circumferentially, along the capsulotomy border, removing the subincisional cortex. Then I rotate the port so that it's facing up and slightly forward, continuing the sweep and removal of the remaining cortex.

It's particularly noteworthy that my technique doesn't include hydrodissection. Once the lens has been fractured – by the chop technique and by pneumodissection from the secondary gas created by the femto treatment – the interface between it and the cortex is disrupted, rendering hydrodissection unnecessary.

Femtosecond laser-assisted methods will continue to evolve. The key step to zero phaco is splitting the lens into two or more pieces before attempting to remove it. Femtosecond technology allows us to provide effective treatment of both routine and complex cases, and it gives us excellent and consistent outcomes. If we also take advantage of Venturi vacuum technology, we can speed up the aspiration process to really capitalize on the advantages provided by the laser's fragmentation capabilities. In fact, femtosecond lens treatment and Venturi vacuum complement each other so well that I would say they were made for each other.

Wendell J. Scott is a partner at Mercy Eye Specialists, and is associated with the Mercy Medical Research Institute in Springfield, MO, USA.

You can watch a video of the Scott femto chop technique online at: https://top.txp.to/0615/femto-chop

It's Time to make a Move

The ONE laser platform for all your needs

It has never been so simple to adapt new technology into your daily workflow. The truly mobile FEMTO LDV Z8 finally enables you to use next generation femtosecond laser technology for your cataract and refractive surgeries. **www.femtoldv.com**

Perfect integration for a streamlined cataract workflow

Compact and mobile for a multi-site use

Modular platform for laser cataract and cornea procedures

FEMTO LDV Z8
Cornea
Cataract
Presbyopia

ziemer
OPHTHALMOLOGY

The FEMTO LDV Z8 is CE marked but not yet cleared by the FDA for the use in the United States.
For other countries, availability may be restricted due to regulatory requirements; please contact Ziemer for details.

Profession

Your career
Your business
Your life

Lights, Camera, Education!

Hundreds of ophthalmologists log on each week to watch a live stream of Wills Eye Hospital's Chiefs' Rounds. What's the attraction?

By Roisin McGuigan

On Fridays, when the faculty at Wills Eye Hospital gather for Chiefs' Rounds – an opportunity for the residents to present complicated cases to the faculty that attend – the cameras start rolling, and the meeting is streamed live online, where it can be freely accessed. We spoke with Wills Eye's Ophthalmologist-in-Chief, Julia Haller (JH) and Director, Media Technology Services, Jack Scully (JS) to understand why they've embarked upon this enterprise, and what it brings to ophthalmologists across the globe.

So what gave you the idea to turn Chiefs' Rounds at Wills Eye into a live webinar?
JH: We've had a robust educational program at Wills ever since the first ophthalmology resident was trained in the United States back in 1839. Teaching is a part of our DNA. But it wasn't until about 10, 15 years ago that we started thinking about putting more of our educational material online.

It started with a program that we had involving the Department of Defense, during the invasion of Afghanistan. We put a lot of our lecturers online for ophthalmologists and eye care providers in the military to view, as they were finding it increasingly hard to attend medical education programs. People liked it so much that back in 2007/2008, we decided to expand the Wills Eye Knowledge Portal, as we call it, because of the feedback.

More recently, we started interactively streaming Chiefs' Rounds on Friday mornings. At first we had just eight people watching the rounds, and now it's over 150. Word is spreading, and it's so great to hear people telling us how much they enjoy it, and that it's changing their practice.

So how does it work?
JH: It's an interactive program where residents present complicated cases to the faculty and ask them questions. So a typical session would be a resident presenting a case, for example, a 55-year-old lady who had cataract surgery a month ago and then came to the emergency room with blurry vision. So the resident will show pictures, then perhaps pick someone in the audience (probably a cataract surgeon) and ask, what do you notice about this patient? What tests would you order? What might your differential diagnosis be?

And what's unique is the interaction – you're not just listening to just one expert talking about his or her area of expertise, you have a whole room full of some of the top specialists in the world, discussing these cases together. It's spontaneous – our whole faculty is there throwing ideas around. For people outside, it's an opportunity to see arguably the top clinical practitioners in the world discussing cases, including many systemic and life-threatening diseases. They're tricky cases, and everybody wants to solve the mystery with us as our program unfolds, so it's a bit like Sherlock Holmes.

> *"We're essentially putting on an unscripted, unrehearsed television show."*

What facilities do you need to be able to livestream?
JS: Over the years, we've built up the infrastructure in our auditorium for this purpose. We've put up curtains behind the podium, wired the room for sound, improved the lighting, and mounted new, better cameras above the podiums so we can film the audience. And there's a speaker camera in the back – so we had to upgrade significantly to make this possible.
JH: In the past, you could just see the resident presenting the case and the slides, but now the audience is visible too – this is a little more nerve-racking because we have to consider how we look and sound, as we're going to be streamed on the Internet worldwide! But having the audience visible has made it a much more interactive experience – it gives you a feeling of what it's like to be at Wills in real time.

It must be quite a technical feat…
JS: Well, there's a lot going on in our

At a Glance

- *Every Friday, Philadelphia's Wills Eye Hospital stream their Chiefs' Rounds live to an international audience*
- *Virtual attendance counts towards CME, and remote viewers can send in questions afterwards about the cases presented*
- *Broadcasting live to the world isn't easy – in essence, the auditorium has to become a TV set, complete with microphones, cameras and lighting*
- *The livestreaming of Chiefs' Rounds has grown in popularity, with many ophthalmologists from around the world tuning in each week*

control room on Friday morning! I've been here for 30 years and I consider the live Chiefs' Rounds to be the most important part of the day. We have to make sure it goes off without a hitch. And we're also recording it for the Knowledge Portal. I have a smaller job too, which is making sure everyone has a mike in their hand and is using it – these things make such a difference for our audience.

JH: Yes, at first it was a challenge to get people to speak into the microphone, and that could make them hard to hear.

Jack and Bill Romano are very detail-oriented and keep everything running smoothly. It's like synchronized swimming – on top it looks so graceful, but underneath the water their feet don't stop moving. We're essentially putting on an unscripted, unrehearsed television show.

JS: Which can be scary sometimes!

And ophthalmologists are awarded CME credits for attending the virtual rounds?

JS: Well I'm not an expert, but if your country allows you to use ACCME credits you can get them. We get analytics on the webinar, so we know who has attended and it tells us if they attended for the full length of our Chiefs' Rounds. They can then contact our CME department which issues the Accreditation Council for Continuing Medical Education (ACCME) credit to that individual for attending. I think that is part of the draw.

JH: If you're a practicing ophthalmologist, it's a free way to get credits if you need them. But I also think it transcends that. Many people in residencies and training programs overseas, who don't need American CME credits, also tune in.

Can people viewing remotely join in and ask questions?

JS: Chiefs' Rounds take place every Friday from 7.00 to 8.00 am EST. As soon as we're done, our doctors are hitting the clinics and the OR, and starting their busy day. We would love to be able to take live questions during rounds, but the logistics of that would slow them down, which we can't do. But questions do come in, and we take them and email them to the presenting residents, who usually reply with their answers.

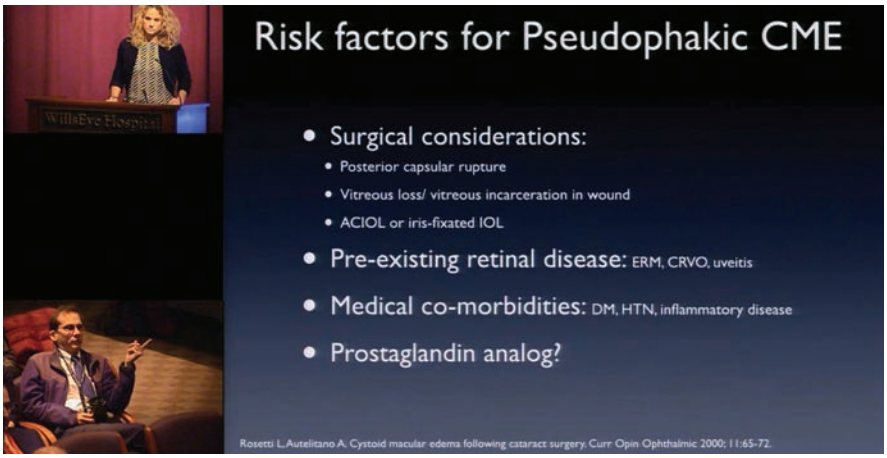

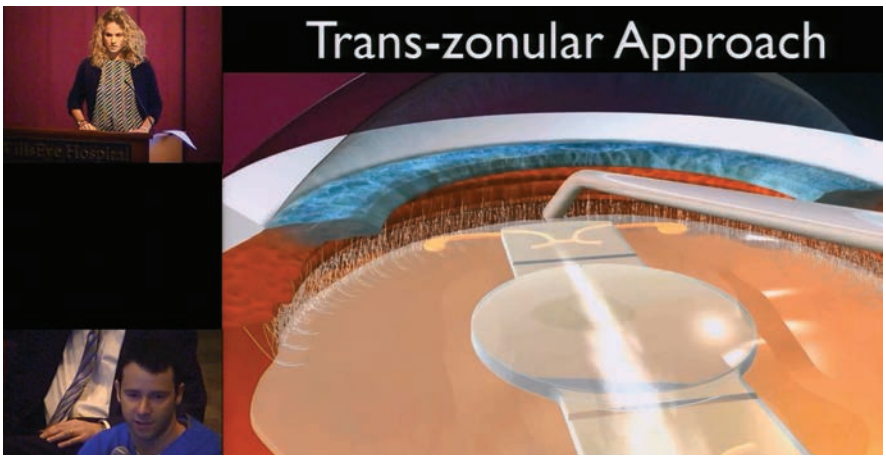

What to expect when you log in to watch a Wills Eye Chiefs' Rounds webinar.

It must be a lot of work. What are the benefits?

JH: Well, we get responses from people who say, we benefited from this tremendously, and we got tips for taking care of our patients. So goodwill, reputation, and a way to stay in contact – for example, the chief at the Mayo Clinic is a former fellow here, and he and his wife get up in time to watch it every week, and tell us how much they like it.

JS: I think it's also the culture at Wills – we want to share what we learn. If we get benefits from that, fantastic, but even if we don't, it's important to teach the next generation of ophthalmologists, and interact with ophthalmologists around the world. As Julia said, it's in our DNA.

JH: And it's just such a fun way to learn.

Julia Haller is Ophthalmologist-in-Chief and Jack Scully is Director, Media Technology Services at Wills Eye Hospital, Philadelphia, USA. The Live Streaming of Chiefs' Rounds is available here: http://top.txp.to/0615/willseye

Why Preservative Free Should Be the Standard of Care in Glaucoma

Why persist with preservatives? Those present in topical glaucoma therapies don't improve the active compound's efficacy – and cause ocular surface disease in many patients

Eyedrops don't have to be preserved. Given the right formulation and container, topical glaucoma medications can be made without the preservatives.

It's clear that a significant proportion of patients that receive chronic therapy with preservative-containing (PC) eyedrops experience ocular side effects (1). For example, many patients with glaucoma or ocular hypertension have ocular surface disease (OSD), and that's driven by the preservatives present in the eyedrops – principally the quaternary ammonium surfactant, benzalkonium chloride (BAC) (2). An increasing number of glaucoma medications have been associated with an increased frequency of severe dry eye symptoms and decreased emotional quality of life (3). BAC's damaging effects on the ocular surface are many (reviewed in the previous issue), and the OSD it can produce can be irritating, painful and significantly impact upon patients' quality of life. Furthermore, both patient dissatisfaction and the occurrence of adverse events have been shown to correlate with disease progression (4). However, in the past, it was thought that BAC was required in topical glaucoma medicine formulations as a penetration (and therefore efficacy) enhancer (5). So what is the current evidence for and against BAC?

A number of clinical studies have compared the efficacy of preserved and preservative-free (PF) topical glaucoma therapies. Hamacher *et al.* (6) examined the efficacy of PF- and BAC-preserved tafluprost in a 4-week crossover study in patients (n=43) with open-angle glaucoma (OAG) or ocular hypertension, and found that these formulations had equal efficacy (p=0.96). Shedden *et al.* (7) also found no difference in the IOP-lowering effect of PF- and BAC-preserved dorzolamide 2%/timolol 0.5% fixed combination eyedrops, in a trial that randomized 261 glaucoma patients to either drug. Clearly, the presence of preservatives has no effect on the efficacy of these anti-glaucoma drugs.

PF formulations can be of benefit to patients that experience ocular surface issues associated with PC prostaglandin formulations. Uusitalo *et al.* (8) investigated the tolerability and IOP-lowering efficacy of PF-tafluprost in patients (n=158) who had exhibited ocular surface side effects with a BAC-preserved latanoprost regimen. What they found was that PF-tafluprost maintained IOP at the same level as latanoprost, but was better tolerated and resulted in increased patient satisfaction, drop comfort and quality of life.

One of the reasons why BAC can cause ocular surface disorders is through goblet cell loss. Goblet cells are the main source of ocular surface mucoproteins and play a central role in tear film stability (9). They have been shown to diminish in number following exposure to BAC-containing topical glaucoma therapies (10), and it's thought that leads to decreased mucin production, tear film instability and ultimately, in many cases, OSD (11). Switching to PF-eyedrops can help improve goblet cell count, but in treatment-naïve patients with glaucoma, why start with PC therapy at all?

Mastropasqua *et al.* (12) assessed the goblet cell density (GCD) in 30 eyes of treatment-naïve patients with primary OAG with both *in vivo* laser scanning confocal microscopy and impression cytology. Patients were randomized to receive either PF-tafluprost, BAC-preserved latanoprost, the BAC-containing latanoprost vehicle or physiological buffered saline solution, and GCD assessments were performed at months 1 and 6 (Figure 1). What was clear was that BAC was bad news for GCD – relative to baseline levels, the numbers were reduced at both timepoints. Notably, PC-latanoprost and PF-tafluprost application actually increased GCD by month 1, but by month 6, eyes that received preserved latanoprost had GCD that was lower than baseline levels, whereas PF-tafluprost-receiving eyes maintained their increased levels of GCD. The study authors confirmed the earlier suggestion by Pisella *et al.* in 2004 (13) that prostaglandin analogs might have a protective or beneficial effect on goblet cells – and that prolonged BAC exposure can lead to toxicity that masks the beneficial effects of these drugs.

Given the evidence that the preservatives present in many topical glaucoma medications have no efficacy benefits, but can cause OSD, reduce regimen adherence and, by increasing side effects risk, speed the progression of glaucoma (4), the question is: why persist with preservatives, when preservative-free therapies are available?

References

1. *EW Leung, et al., "Prevalence of ocular surface disease in glaucoma patients", J Glaucoma, 17, 350–355 (2008). PMID: 18703943.*
2. *C Erb, et al., "German register for glaucoma patients with dry eye. I. Basic outcome with respect to dry eye", Graefes Arch Clin Exp Ophthalmol, 246, 1593–601 (2008). PMID: 18648841.*
3. *A Camp, et al., "Dry eye specific quality of life in*

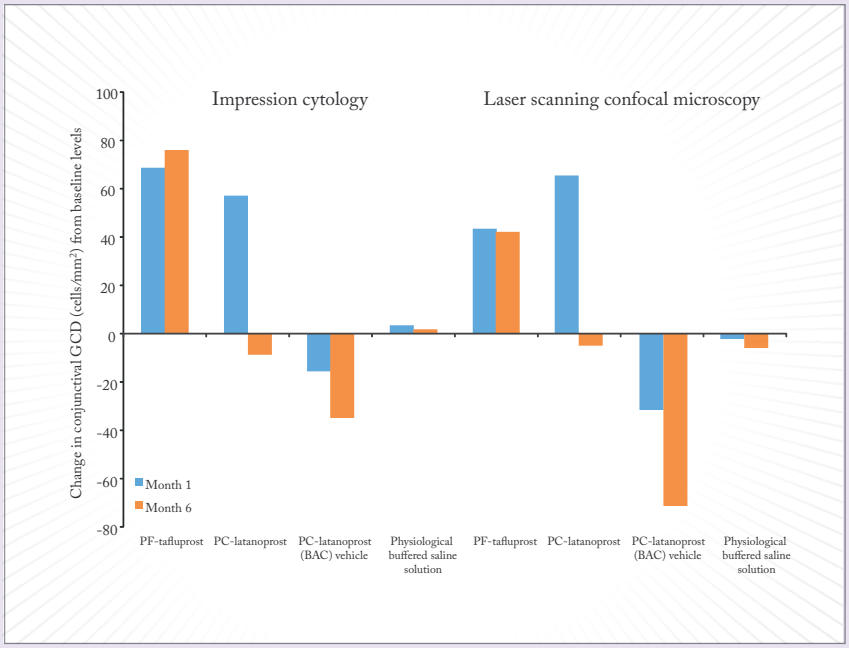

Figure 1. In vivo impression cytology and laser scanning confocal microscopy assessments of conjunctival goblet cell density (GCD; cells/mm2) at scheduled time points (12).

veterans using glaucoma drops", Cont Lens Anterior Eye, 38, 220–225 (2015). PMID: 25737401.

4. *P Denis, et al., "Medical outcomes of glaucoma therapy from a nationwide representative survey", Clin Drug Investig, 24, 343–352 (2004). PMID: 17516721.*
5. *M Irkec, et al., "Are preservatives necessary to improve efficacy of some glaucoma drops?", Br J Ophthalmol, 97, 1493–1494 (2013). PMID: 24216677.*
6. *T Hamacher, et al., "Efficacy and safety levels of preserved and preservative-free tafluprost are equivalent in patients with glaucoma or ocular hypertension: results from a pharmacodynamics analysis", Acta Ophthalmol Suppl, 242, 14–19 (2008). PMID: 18752510.*
7. *A Shedden, et al., "Comparison of the efficacy and tolerability of preservative-free and preservative-containing formulations of the dorzolamide/timolol fixed combination (COSOPTTM) in patients with elevated intraocular pressure in a randomized clinical trial", Graefes Arch Clin Exp Ophthalmol, 248, 1757–1764 (2010). PMID: 20437244*
8. *H Uusitalo, et al., "Switching from a preserved to a preservative-free prostaglandin preparation in topical glaucoma medication", Acta Ophthalmol, 88, 329–336 (2010). PMID: 20546237.*
9. *MJ Doughty, JP Bergmanson, "New insights into the surface cells and glands of the conjunctiva and their relevance to the tear film", Optometry, 74, 485–500 (2003). PMID: 12926821.*
10. *MY Kahook, R Noecker, "Quantitative analysis of conjunctival goblet cells after chronic application of topical drops", Adv Ther, 25, 743–751 (2008). PMID: 18670744.*
11. *G Van Setten et al., "Severe Dry Eye Disease – Facing the Treatment Challenges", European Ophthalmic Review, 8, 87–92 (2014).*
12. *G Van Setten, et al., "Conjunctival goblet cells density and preservative-free tafluprost therapy for glaucoma: an in vivo confocal microscopy and impression cytology study", Acta Ophthalmol, 91, e397–405 (2013). PMID: 23601909.*
13. *PJ Pisella, et al., "Conjunctival proinflammatory and proapoptotic effects of latanoprost and preserved and unpreserved timolol: an ex vivo and in vitro study", Invest Ophthalmol Vis Sci, 45, 1360–1368 (2004). PMID: 15111589.*

Next month

As a significant proportion of patients with glaucoma are sensitive to the preservatives contained in many topical glaucoma therapies, it's therefore important to diagnose these patients. We'll review the diagnostic tools and the European Glaucoma Society's guidelines for identifying these patients.

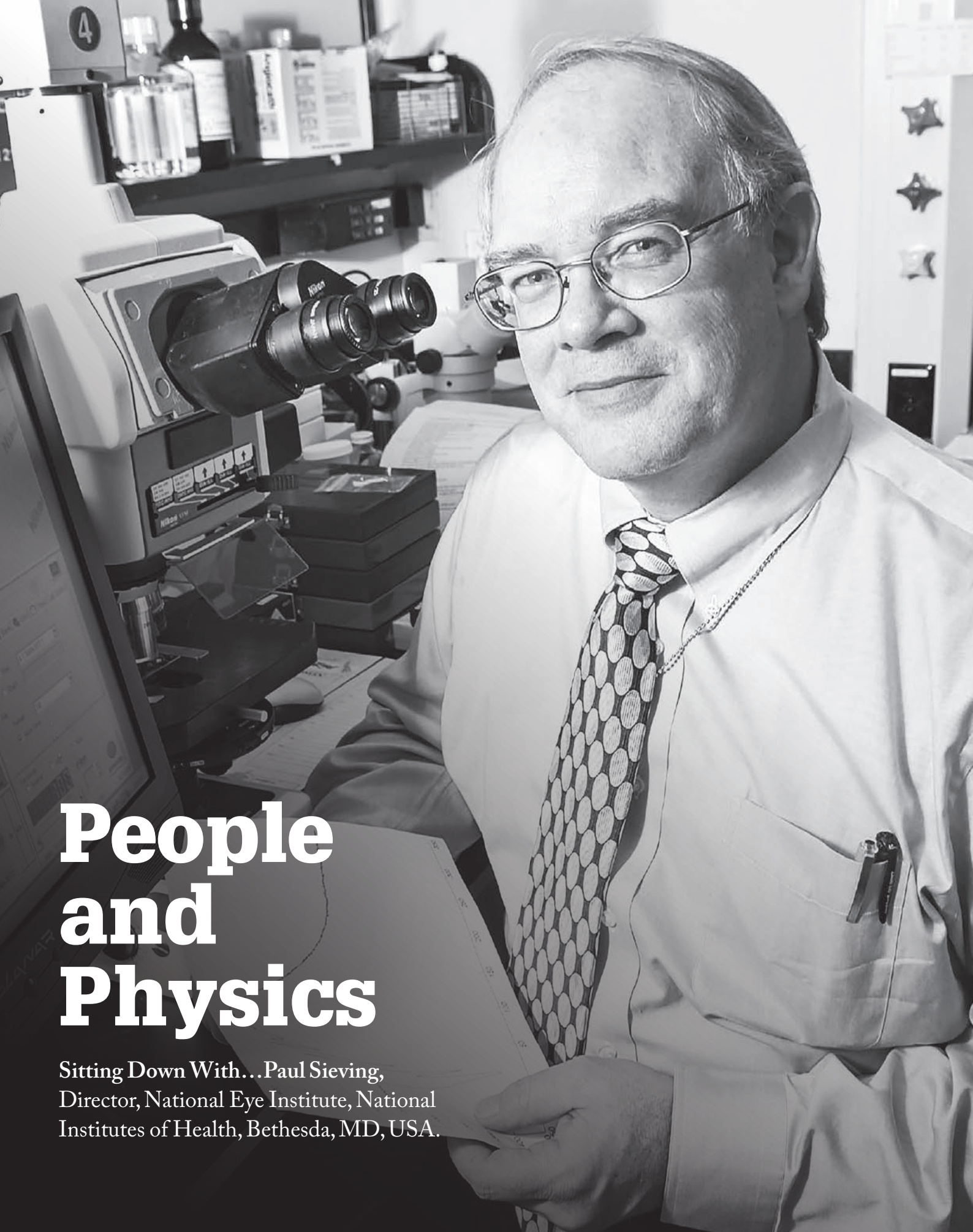

People and Physics

Sitting Down With…Paul Sieving,
Director, National Eye Institute, National Institutes of Health, Bethesda, MD, USA.

How did you end up where you are today?

I'm interested in people, but also in physics – two areas that don't typically go together. My interest in helping people motivated me to learn medicine, but once I started, I developed a particular interest in the workings of the eye, and especially the retina. I enjoy finding out how things work and why they fail, which is kind of an engineering approach to medicine – so the way vision works, with all the complexities of light refraction and absorption, appeals to my background in physics and my inclination toward engineering. Ophthalmology was a good combination of all the things I wanted to do.

After the first human genome was published, the importance of genetics became obvious. I was studying night blindness – and I could examine cells, calibrate light intensities, check peripheral vision, and ask about family histories, but none of that gave me a fundamental insight into the problem. I'm interested in why things happen, which is very hard to get your hands on. The easiest way is to find patients with a family history of disease and then study those families to identify the gene of interest. That way, you can get a handle on the pathophysiology of the disease. Genetics is a marvelously complex subject area, but it's also a tool – a key that unlocks the door to the biology of retinal disease.

How do you divide your time between research and administration?

I want to emphasize that I continue to do science. I see it as a vital part of my responsibilities – it's important for me to talk to knowledgeable scientists and clinicians. So in addition to my administrative duties, I maintain a laboratory at the National Institutes of Health (NIH), where I work in the evenings and on weekends. It turns out that I'm not the only one – about half of NIH directors maintain active research programs.

What's your management style?

My management style lets me expand beyond my own capabilities. I look for people who are excited about a job or idea I want to investigate, and hire them to focus on it. Over the course of the 14 years I've been at the National Eye Institute (NEI), I've been fortunate to find a number of hardworking, responsible people to join my team. I coordinate the "big picture," but these kinds of jobs are far too extensive for any one person to tackle, so I'm always looking for smart people to join the institute. I learn a lot from them, too; each person I work with has their own way of thinking. When I talk to them, I listen carefully so that I understand their needs, and then I can accommodate those things. I don't know if I'm a great communicator, but I try.

"I see science and medicine as a fabric that extends from all corners."

What's exciting you about your research at the NEI at the moment?

At the moment, I'm very proud because our lab has just received all the necessary regulatory approvals to begin human gene therapy studies in men with X-linked retinoschisis – structural splitting of the retina. We're now doing a gene therapy trial with a vector we developed in our laboratory. In an animal model, we were able to rescue the retinoschisis phenotype, so now it's time to take that work to humans. We've already injected several individuals with our new vector, so we're hoping to see some success soon.

Is this your career highlight to date?

The new trials aren't the only thing I'm proud of in my career. I've been fortunate enough to do a number of things that have been extremely gratifying. Many involved understanding the genetic pathologies of particular families, creating animals that have human equivalent diseases, and developing gene therapies for those diseases. I recently spoke at the NEI's Audacious Goals development meeting and used the words "seamless science," because I see science and medicine as a fabric that extends from all corners – but if you trace your way back through it, you can see where it's come from and which researchers and discoveries have turned it into what it is today.

What advice do you have for others who want to follow in your footsteps?

Follow what interests you, and if it interests you very deeply, don't worry about the money (unless you can't buy the bread and the butter). That's the advice I've always tried to follow. A lot of scientists and research clinicians my age are looking back and thinking that we had an easier time getting our careers off the ground 20, 30, or even 40 years ago. The current climate is particularly rigorous for people who are just starting out. There are a number of roadblocks: research funding is tight even as opportunities are burgeoning, and the complexity of science has grown as we've acquired new knowledge and resources. I feel strongly – as do my colleagues – that society needs to rekindle support for research.