

# the Ophthalmologist®

**Upfront**  
ChatGPT's experimental  
ophthalmic model

06

**Feature**  
Current issues in pediatric  
ophthalmology


26 - 31

**Glaucoma**  
AI as an integral component  
of diagnosis

47 - 49

**Sitting Down With**  
Ursula Schmidt-Erfurth,  
Medical University of Vienna

50 - 51



## **Lightbulb Moment: The Impact of AI**

Industry leaders set out their hopes and predictions for AI's  
growing role in ophthalmology

14 - 20

# elios

Highly adoptable<sup>1</sup>

Non-thermal excimer laser<sup>2</sup>

Glaucoma intervention at the time of cataract surgery<sup>3</sup>

## A sensible approach in glaucoma care.



### The Interventional Glaucoma Podcast

Scan the code to check out our new podcast all about the interventional glaucoma mindset. Join world-renowned glaucoma leaders as they engage in unscripted discussions about the latest innovations in Interventional Glaucoma and how applying new technologies in routine practice could improve patient-centered care.

1. Durr et al. *Eye and Vision*. 2020. 2. Pidro A, Biscevic A, Pjano MA, Mravicic I, Bejdic N, Bohac M. *Acta Inform Med*. 2019 Dec. 3. Töteberg-Harms M, Hanson JV, Funk J. *BMC Ophthalmol*. 2013 Jun.

ELIOS Vision GmbH is the EU distributor of ELIOS manufactured by MLase GmbH, located at 82110 Germering, Industriestr. 17, Germany and the FIDO laser applicator manufactured by WEINERT Fiber Optics GmbH, Mittlere-Motsch-Strasse 26, 96515 Sonneberg, Germany. ELIOS is CE marked and licensed for use in the EU in adult patients with glaucoma and is currently under investigational use in the US as part of an ongoing IDE study (FDA). Product feedback should be sent to [productsurveillance@eliosvision.com](mailto:productsurveillance@eliosvision.com). The ExTra II (laser class 4) has the brand name ELIOS. The ExTra II is equivalent to ExTra and AIDA devices.

[eliosvision.com](http://eliosvision.com)



**T**echnology, AI, robotics, big data, implanted intraocular pressure (IOP) sensors, state-of-the-art pumps as a replacement for drainage devices – these were a few of the forward-looking topics covered at the European Glaucoma Society (EGS) Congress in Dublin, Ireland (June 1–4, 2024)

A prescient glimpse of the near (and not-so-near) future is something we’ve come to expect from this celebrated glaucoma meeting. But the EGS event also takes time to look back and honor the visionaries whose achievements – sometimes decades-old – are still shaping the present. This year’s Jules François Lecture, for example, was given by ophthalmology legend (and Hall of Famer) George Spaeth, who imparted key lessons from his nearly 70-year career. Spaeth received a standing ovation from the audience – as much, of course, for his long list of accomplishments as for his insights from the podium. But what about those innovators who might not be so well remembered?


This was the subject of a keynote speech by Roger Kneebone, Professor of Surgical Education and Engagement Science at Imperial College London. Kneebone has made it his mission to track down and, where possible, engage with the practitioners who have not always graced the pages of the medical history books, but whose surgical influence has quietly spread far and wide. One such name is urologist John Wickham (1927-2017), whose use of early, self-constructed laparoscopic and Syclix-like devices in the 1980s was key to the development of keyhole surgery – later known as minimally invasive surgery. Wickham’s practices in this area were slow to catch on, however. (So were his endeavors in robotic surgery – he used the PROBOT to remove soft tissue from a patient back in 1991.)

Kneebone’s work highlights the value not just of revisiting the procedures of past surgeons, but also their surgical teams and other cogs in the machine, such as the medical device designers and manufacturers. Alluding to Thomas Kuhn’s *The Structure of Scientific Revolutions* (1962), he reminds us that progress is not a straightforward, upward trajectory of clean breakthroughs. Innovation is “messy;” it’s only when we read about it later does it become clearer, seemingly more deliberate, even pre-determined. We lose something, Kneebone concludes, if we forget or disregard the procedures of the past. To fuel and contextualize the innovations of the future, it’s important to look back – both to the famed visionaries and to those unsung pioneers whose patchwork solutions proved to be ahead of their time.

**Julian Upton**  
*Group Editor*



26



48

### In My View

- 10 **A Digital Frontier**  
Could the Apple Vision Pro and spatial computing transform the ophthalmological landscape?  
Tommy Korn reports

### Feature

- 14 **Lightbulb Moment: The Future Reality of AI**  
Our 2024 Power Listers set out their predictions for AI's growing role in ophthalmology
- 26 **Child's Eye View: Issues in Pediatric Ophthalmology**  
Exploring challenging pediatric eye diseases – and the digital tools being developed for their diagnosis and treatment

### 03 Editorial

Look Back in Wonder  
by Julian Upton

### On The Cover



*Is this "the lightbulb moment" as far as AI and healthcare is concerned?*

### Upfront

- 06 The latest news and research, including amblyopia's link to adult health, reducing incidence of age-related macular degeneration with Alzheimer's disease drugs, and ChatGPT's experimental ophthalmic model

### Reports

- 12 **Innovating the Field of Slit Lamp Imaging**
- 32 **Harnessing the OMNI Opportunit**
- 21 **Success with Centurion® with Active Sentry®**



Feel free to contact any one of us:  
first.lastname@texerepublishing.com

**Content**

Julian Upton (Group Editor)  
Alun Evans (Deputy Editor)  
Jamie Irvine (Associate Editor)

**Commercial**

Neil Hanley (Publishing Director)  
Sam Blacklock (Publisher)  
Ross Terrone  
(Business Development Manager)  
Clare O'Neill-Gill  
(Business Development Manager)

**Creative**

Charlotte Brittain (Senior Designer)  
Hannah Ennis (Lead Creative - Commercial)  
Sophie Hall (Social Media Manager)  
Emma Kaberry (Project Manager)  
Bethany Loftus (Project Coordinator)  
Harvey Marshall (Video Producer  
& Project Manager)

**Digital**

David Roberts (Digital Team Lead)  
Jody Fryett (Salesforce & Audience  
Sytems Manager)  
Peter Bartley (Senior Digital Producer)  
Jamie Hall (Audience Insights Analyst)  
Shea Hennessey (Digital Producer)  
Oliver Norbury (Digital Producer)  
Seamus Stafford (Digital Producer)

**CRM & Compliance**

Julie Wheeler (Compliance and CRM Assistant)

**Sales Support**

Lindsey Vickers (Sales Support Manager)  
Hayley Atiz (Sales Support Coordinator)  
Emily Scragg (Sales Support Coordinator)

**Marketing**

Michelle Gill (Brand Marketing Executive)  
Lauren Williams (Marketing Executive)

**Accounts**

Kerri Benson (Accounts Assistant)  
Vera Welch (Junior Accounts Assistant)

**Management Team**

*Chief Executive Officer - Andy Davies*  
*Chief Operating Officer - Tracey Peers*  
*Interim Lead & Financial Director - Phil Dale*  
*Editorial Director - Rich Whitworth*  
*Creative Director - Marc Bird*  
*Head of Sales / Publisher - Helen Conyngham*  
*Human Resource Manager - Tara Higby*  
*Head of Digital Operations - Brice Agamemnon*  
*CRM & Compliance Manager - Tracey Nicholls*  
*Marketing Manager - Katy Pearson*


Change of address info@theanalyticalscientist.com  
Julie Wheeler, The Analytical Scientist, Texere Publishing  
Limited, Booths Park 1, Chelford Road, Knutsford, Cheshire,  
WA16 8GS, UK

General enquiries  
www.texerepublishing.com | info@theanalyticalscientist.com  
+44 (0) 1565 745 200 | sales@texerepublishing.com

Distribution: The Analytical Scientist (ISSN 2051-4077),  
is published bi monthly by Texere Publishing Limited, Booths  
Park 1, Chelford Road, Knutsford, Cheshire, WA16 8GS, UK.  
Single copy sales £15 (plus postage, cost available on request  
info@theanalyticalscientist.com). Non-qualified annual  
subscription cost is available on request.

*Reprints & Permissions - tracy.nicholls@texerepublishing.com*  
*The copyright in the materials contained in this publication and the typographical  
arrangement of this publication belongs to Texere Publishing Limited. No person may  
copy, modify, transmit, distribute, display, reproduce, publish, license or create works from  
any part of this material or typographical arrangement, or otherwise use it, for any public  
or commercial use without the prior written consent of Texere Publishing Limited.*  
*The names, publication titles, logos, images and presentation style appearing in this  
publication which identify Texere Publishing Limited and/or its products and services,  
including but without limitation Texere and The Analytical Scientist are proprietary  
marks of Texere Publishing Limited. Nothing contained in this publication shall be  
deemed to confer on any person any licence or right on the part of Texere Publishing  
Limited with respect to any such name, title, logo, image or style.*

The Ophthalmologist is printed using soy ink



08



06

**Practice Fundamentals**


- 36 **Retina**  
Retinal seaweed, prime editing for inherited retinal diseases, and surgical tips from Ferenc Kuhn and Andrzej Grzybowski
- 40 **Anterior Segment**  
Outdoor UV radiation displays and photokeratitis, electroretinography developments, and trusting tripan blue
- 47 **Glaucoma**  
Trabeculectomy and Quality of Life, glaucoma adherence in Latin America, and AI-powered glaucoma risk stratification



50

**Sitting Down With...**

50 **Ursula M. Schmidt-Erfurth,**  
Professor and Chair of the  
Department of Ophthalmology at  
the Medical University of Vienna



## Amblyopia and Adult Health Risks

**A Lancet study points towards an association between childhood amblyopia and cardiometabolic disorders in adulthood**

Amblyopia affects an estimated 1.4 percent of children worldwide. But what if “lazy eye” was an indicator of later health problems? A new Lancet study—conducted by Siegfried Wagner, Vasiliki Bountziouka, Pirro Hysi, and Jugnoo Rahi on behalf of the UK Biobank Eye & Vision Consortium—suggests there could be, although the authors acknowledge the lack of evidence pointing to a causal relationship.

“What the study shows is that the average person who had amblyopia in childhood has a higher risk of cardiometabolic disorders in adult life—it doesn’t mean that everyone with amblyopia will develop these cardiometabolic disorders,” explains co-author Jugnoo Rahi. “But it is very unusual to have a clear childhood ‘marker’ of increased risk of cardiometabolic disorders as an adult.”

How strong is the link? Patients who had amblyopia as a child had a 16-percent higher

chance of becoming obese in adulthood, a 29-percent higher chance of developing diabetes, and were 25 percent more likely to develop hypertension in their adult life. “We hope that knowing this association can support the efforts of affected children and their families to achieve healthy lifestyles from the outset,” says Rahi.

Despite the lack of evidence to support causality, Rahi believes the findings do add usefully to evidence pointing towards the

importance of early life as a foundation for lifelong health. “Specifically, they uncover a potential indirect/non-vision benefit of childhood vision screening to detect amblyopia,” she says. “Since amblyopia affects between two percent and four percent of most child populations, there could be a significant impact at population level.”

*See references online at: [top.txp.to/amblyopia/health/risks](http://top.txp.to/amblyopia/health/risks)*

## Upfront

Research  
Innovation  
Trends



## INFOGRAPHIC

### The 30 Percent Deficit

The present and future state of the ophthalmology workforce in the US

From 2020 to 2035, the total ophthalmology supply is projected to **decrease** by **2650** full-time equivalent ophthalmologists

At the current trajectory, there will be a projected **30 percent** shortage of ophthalmologists in the US, relative to demand, by 2035







## SPOTLIGHT ON ARVO

### We help you keep up to date with the latest vision research from ARVO's journals

*Sweet enough?* A new study has investigated whether the use of artificial sweeteners – particularly saccharin – might impact neovascular age-related macular degeneration (nAMD) patients undergoing anti-VEGF treatment. The study found that saccharin does indeed appear to play a protective role for these patients, reducing scarring and improving pathological lesion control. PMID: 38558091

*VF Racial Disparity.* Asian and Black patients with glaucoma undergo less visual field testing (VFT), according to a new TVST study. The retrospective analysis explored 2,654 participants (1,515 white, 782 Black and 357 Asian) and, even when taking into account confounders, such as disease severity and socioeconomic disadvantage, revealed that Asian and Black individuals received fewer VFT visits. PMID: 38564202.

*Uveitis proteins.* Aiming to identify biomarkers linked to retinal vascular involvement in non-anterior uveitis, a TVST study performed proteomic analysis of 154 pediatric uveitis samples.

The team identified nine proteins that could be linked to retinal vascular involvement, and another 63 that could explain the differences in serum proteomes between anterior and non-anterior uveitis. The targeted proteomics analysis indicates mediators that could act as biomarkers for future personalized treatments of the disease, the researchers report. PMID: 38573655.

*Atropine percentages.* To compare the ocular surface effects of low-concentration atropine eye drops (0.01 percent and 0.05 percent) on a cohort of students (18–30 years old), researchers randomly assigned the two concentrations to 26 myopic students. The researchers found that 0.05 percent atropine can have a significant (but temporary) impact on the tear film, whereas 0.01 percent had minimal ocular surface effects. PMID: 38625083.

*RB's impact on childhood development.* To target the current gap in literature regarding the early growth differences between somatic and heritable retinoblastoma (RB), a large multinational team enrolled 253 RB patients (38 of whom were somatic and 214 heritable) from 10 different countries. The results suggest that there is no environmental or biological impact on childhood growth parameters for either form of the disease. PMID: 38662390.

Child photo sourced from: Unsplash.com



## Square Eyes

### Study indicates the surprising links between lower myopia risk and television

It might seem rather counterintuitive that watching television could actually benefit your eyesight. But that's exactly what new research claims... at least, to a degree. The BMC Ophthalmology Mendelian randomization study (1), published in March 2024, indicates that "leisure television watching" can reduce the risk of developing myopia and poor vision as one gets older.

The authors noted that this observation might be partially explained due to the fact that, because television screens have become larger and more common in households, they are having less negative impact on refractive change in viewers. The study also noted that moderate-to-vigorous physical activity was another factor associated with lower myopia risk.


The authors believe that these findings could offer future researchers "new insights into the potential mechanism for predicting myopia occurrence and progression."

See references online at: [top.txp.to/square/eye](http://top.txp.to/square/eye)

By 2035, it is predicted that metro areas will have **77 percent** workforce adequacy




**Ophthalmology's workforce** adequacy in 2035 is expected to rank **37th** out of 38 medical professions



The last commissioned eye care workforce study by the AAO was **29 years** ago

#### Reference

1. ST Berkowitz et al., *Ophthalmology Workforce Projections in the United States, 2020 to 2035, Ophthalmology*. 131, 133 (2024). PMID: 37739231.



## Ophthalmobot

### EyeGPT and EyeGPT PRO (experimental models) – expanding ophthalmology with the aid of ChatGPT

By Alfredo Di Giovanni

Ophthalmology is a field in constant evolution, where technology plays a significant role in improving the diagnosis and treatment of eye diseases. Recently, the introduction of EyeGPT and EyeGPT PRO (1) – generative pre-trained transformers (GPTs) that leverage ChatGPT's computing power with a focus on ophthalmological expertise – appears to mark a further step in this direction, combining medical expertise with advanced artificial intelligence (AI) technology.

EyeGPT is an artificial intelligence-based system designed to educate anyone interested in ophthalmology issues, and potentially aiding the early identification of eye problems. Using advanced algorithms, EyeGPT can analyze user-provided data to offer personalized

advice or respond professionally to ophthalmic questions. It can not only increase patient awareness of eye health, but also act as a fundamental first step in the preventive care chain.

EyeGPT PRO takes things up a notch by offering advanced functionalities, such as detailed analysis of diagnostic images and the ability to recognize characteristic patterns of early ocular pathologies. This is useful not only for more accurate diagnoses, but also for customizing treatments, based on a vast database and previous learnings. EyeGPT PRO also offers continuous updates on every aspect of ophthalmology, both in the clinical and basic research spheres. Every response can be further detailed to ultra-specialist levels. The model will always ask if the response is sufficient or if there's a need to delve deeper into even finer details, starting from the clinical level and reaching multidisciplinary with basic research disciplines.

EyeGPT's ability to identify early signs of rare or complex ocular diseases through the analysis of patterns in diagnostic images could significantly

reduce waiting times for an accurate diagnosis. Much has already been said about the usefulness of AI systems in recognizing pathological profiles from image analysis, such as in diabetic retinopathy. We have tested these features by asking EyeGPT PRO to analyze the complex patterns of tear film interferometry, correlating them with different stages of dry eye, yielding extremely interesting results.

The integration of EyeGPT and EyeGPT PRO in ophthalmology represents an interesting application of AI in this field. The goal is not only to improve patient care, but also to open new avenues of reflection and innovative approaches to understanding and treating eye diseases. However, it is important to remember that these are experimental models, still prone to errors or inaccuracies, and their refinement is the result of ongoing, nascent work that is aided by feedback on the technology from the wider ophthalmological community.

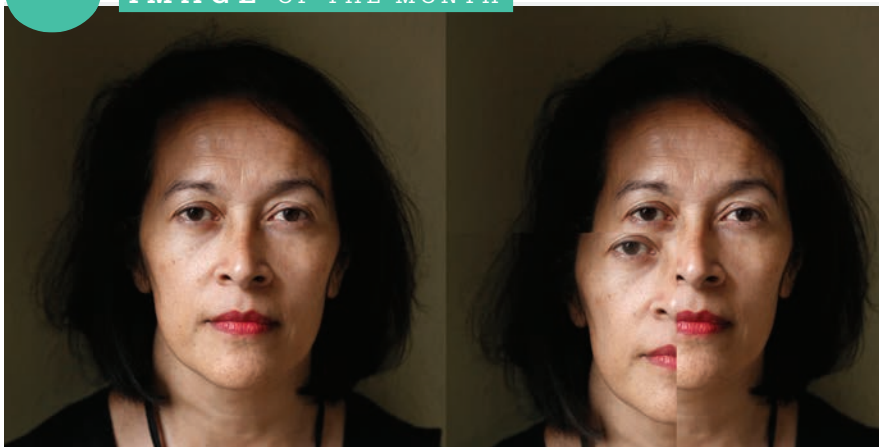#### Reference

1. EyeGPT (2024). Available at: <https://bit.ly/4a3jM5I>





## IMAGE OF THE MONTH

*Face to Face with Strabismus*

Original photograph by Francesca Cesari - diptych created in collaboration with Lucia Wilson, from Face to Face with Strabismus.

[luciwilson.co.uk/francescacesari.com](http://luciwilson.co.uk/francescacesari.com).

*Credit: Francesca Cesari & Lucia Wilson*

Would you like your photo featured in Image of the Month?  
Send it to [edit@theophthalmologist.com](mailto:edit@theophthalmologist.com)

## QUOTE OF THE MONTH

*“We’re still in the 1870s when it comes to AI and healthcare. I see parallels between where we are now and the dawn of the electrical age... A network of innovations was needed before the lightbulb could be adopted as a viable, widespread alternative to candlelight... We need a similar supporting ecosystem in place to take advantage of the massive potential of AI in healthcare.”*

Pearse Keane, Consultant Ophthalmologist,  
Moorfields Eye Hospital and Professor of Artificial  
Medical Intelligence at UCL

## Inhibiting AMD

**Alzheimer’s disease drugs could reduce incidence of AMD, says new JAMA study**

Reports say that acetylcholinesterase inhibitors (AChEIs) – commonly for those suffering with Alzheimer’s disease (AD) – could also possess secondary health benefits outside of dementia treatment (1). Examining the potential ophthalmic benefits of the drugs, researchers looked at how the inhibitors might reduce incidence of age-related macular degeneration (AMD) in those living with AD (2).

“Our findings demonstrated a small reduction in the risk of AMD among patients with AD,” confirms Scott Sutton, a clinical researcher at the Dorn Research Institute/Veterans Affairs Medical Center. Sutton says the next steps would be a randomized clinical trial to determine if there is a cause-and-effect relationship between the inhibitors and reduced incidence of AMD, as well as investigating the genetic predisposition for AMD to confirm the effect of the inhibitors. He also suggests further research should include more diverse demographics.

### Reference

1. V Kaushik et al., “Acetylcholinesterase Inhibitors: Beneficial Effects on Comorbidities in Patients With Alzheimer’s Disease,” *American Journal of Alzheimer’s Disease & Other Dementias*, 33, 73 (2018). PMID: 28974110.
2. S Sutton et al., “Alzheimer Disease Treatment With Acetylcholinesterase Inhibitors and Incident Age-Related Macular Degeneration,” *JAMA Ophthalmology* [Online ahead of print] (2024). PMID: 38175625.

## A Digital Frontier

Could the Apple Vision Pro and spatial computing transform the ophthalmological landscape?

By Tommy Korn

“Wow!” That was my reaction when I first received an early hands-on demo of Apple Vision Pro; at that moment, I realized the human race was about to enter a new era of computing.

Over the past two years, the medical field has witnessed the unveiling of groundbreaking technologies – from smartwatches that monitor heart function to generative AI, to wearable mixed-reality spatial computing ocular devices. And yet, as healthcare clinicians, we find ourselves at a contradictory crossroads, navigating through the fog of digital exhaustion from archaic, clunky 1990s’ electronic medical records to a sea of non-integrated, high-friction healthcare apps. Burnout is rampant, interoperability is a mere dream, and the essence of patient care is buried under layers of inefficiency – all of which contribute to poor patient access to care.

In the digital cacophony surrounding the world outside of healthcare, the advent of spatial computing – heralded by devices like the Apple Vision Pro – represents a beacon of transformative potential for our industry. This technology is not just another screen or gadget; it’s a paradigm shift in how we interact with information, bringing data to life in the three-dimensional space that surrounds us. A mixed-reality headset that can be viewed as a direct extension of the brain, the Apple Vision Pro promises an intimacy of interaction hitherto unimagined; these devices and their capabilities represent a type of cognitive augmentation only



### In My View

*Experts from across the world share a single strongly held opinion or key idea.*

envisaged up until now in science fiction.

As eye care professionals, our role transcends the clinical; we are the custodians of vision, the gatekeepers of perhaps the most profound senses through which humans perceive and interact with the world. The introduction of this technology that sits so close to the eye, bridging the digital and the sensory, places us at the vanguard of a new era. We are uniquely positioned to guide this evolution, ensuring that, as society navigates this uncharted territory, we do so with a compass that points towards enhancing human health and its mental wellbeing.

Innovate with purpose – my digital health doctrine  
Amid the buzz surrounding new

*“The advent of spatial computing represents a beacon of transformative potential.”*

technologies, the essential principles of digital health innovation should not be forgotten. At its core, we must ask three major questions when addressing any new digital technology:

1. Is it safe – does it respect privacy and offer value for the user?
2. Does it integrate seamlessly with existing systems?
3. Crucially, can it scale effectively across varied healthcare environments to benefit all, while having an economic model that allows the innovation to survive?

Beyond these considerations, there's an even more fundamental inquiry that underpins the very essence of any innovation, especially in healthcare: What is the job to be done? As ophthalmologists, we need to question whether it's necessary to "hire" this new spatial computing device. Will it significantly benefit our patients and our work lives? Does it fill a gap that existing technologies cannot? It's about making a discernment between sustaining technologies – which either replace or enhance current methods – and disruptive technological innovations that might carve out entirely new markets and create new, unforeseen healthcare services.

I believe that disruptive innovations are the shot in the arm that healthcare desperately needs, and when the correct job for a new technology is identified, that's when disruptive innovation comes into play. For example, take the advent of smartphones. No one could have predicted the rise of social media, telehealth, or the use of integrated cameras for medical imaging and diagnostics. These weren't just enhancements to existing gadgets; they were harbingers of new industries, new ways of connecting, and previously unimaginable applications in healthcare. Such groundbreaking mobile technologies laid the groundwork for creation of new businesses and industries.

The realm of spatial computing and VR/AR (virtual reality/augmented reality) devices in healthcare is ripe with potential for transformative

applications in new markets. Imagine technology-assisted surgeries that allow for unprecedented precision, aligning lens implants perfectly or executing meticulous incisions tailored to the individual's unique eye anatomy. This isn't just innovation; it's a reimagining of possibilities – a leap toward a future where the precision and efficacy of medical interventions promotes an unforeseen culture of patient safety.

*“As possibilities are reimagined, innovators must recognize that new technologies are akin to living organisms – they require continuous nurturing, development, and adaptation.”*

Privacy, eye health, and balance  
Prolonged use of wearable ocular devices could pose tangible risks to corneal health, including dry eye syndrome from reduced blink rates. As such, the close proximity of these wearables underscores a profound responsibility for ophthalmologists: to safeguard not only the physical health of the eyes, but also the private, sensitive data these devices can capture.

Eye tracking will be used by wearable eye computers as the primary interface modality, and this ability to record eye tracking is like monitoring someone's thoughts. Without a doubt, privacy must be the most sacred principle to uphold in this circumstance. Iris authentication is also unique to humans, and this data must also be safeguarded at all costs. As eye care clinicians, we can provide the expertise for guiding technology companies in how to ethically use this sensitive information without compromising the safety and privacy of the users.

Beyond the physical, there's also a psychological risk to consider – mental burnout and societal disconnection. In our pivotal role, we must guide the integration of mixed-reality/virtual technologies with a balanced perspective, ensuring that, as we look forward to new horizons of human-computer interaction, we also reiterate how important it is to take a break from these new devices and reconnect with the real, physical world. Maintaining a healthy balance between the natural world and the digital realm is key to maintaining a healthy life in the 21st century and beyond.

As we navigate this exciting yet daunting landscape, we must do so with foresight, compassion, and an unwavering commitment to the principles that have always guided our profession. The future of ophthalmology in the age of digital innovation is not just about adapting to new technologies; it's about shaping them to serve our highest purpose – the improvement of human health and vision, while simultaneously respecting the uniqueness and privacy of each patient.

*Tommy Korn MD, Ophthalmologist and Chief Physician Evangelist - Digital Health Innovations at Sharp HealthCare, Spatial Computing Center of Excellence, San Diego, California.*



# Innovating the Field of Slit Lamp Imaging

## Two leading ophthalmologists share their experience of using the newly launched 3D Imaging Option for the Haag-Streit Imaging Module 910 (IM 910)

In 2022, Haag-Streit launched the Imaging Module 910 solution for the BQ 900 slit lamp, boasting smart features such as auto-exposure mode and automatic aperture control to improve the success rate of conclusive images offered by conventional slit lamp cameras. In May this year, Haag-Streit further enhanced the proven benefits of the IM 910 by adding a 3D Imaging Option. By enabling the recording of videos and images in 3D, clinicians can now experience a more detailed and authentic representation of the slit lamp exam.

Two eye care experts currently using the 3D functionality of the Imaging Module 910 3D (IM 910 3D) are Michael E. Snyder, MD, of the Cincinnati Eye Institute, Ohio, USA, and Sunil Mamtora, FRCOphth, of Bristol Eye Hospital, UK. Snyder has a private practice specializing in complex cataract, cornea, and anterior segment surgery. Mamtora's subspecialty interests include cataract and medical retina/uveitis; his practice includes working in the hospital's emergency department, treating patients with "a huge spectrum of diagnoses and pathology."

A self-described early adopter of the technology, Dr. Mamtora has been using the IM 910 3D for around 18 months. He considers himself "a slit-lamp imaging enthusiast." While his hospital has a

dedicated imaging team (and a Haag-Streit BX 900 slit lamp, commonly known as "The photographer's slit lamp,") Mamtora enjoys taking his own photos and videos.

"The IM 900 was able to capture brilliant photographs," he says, "but I felt that the process of capturing a photo that I was happy with often took too long – this is a problem in a very busy hospital!" With the latest imaging module, the IM 910, however, "capturing a perfect image doesn't add any time to my workflow at all," Mamtora continues. "I can be examining a patient and think, 'It'd be useful to take a photograph.' Then all I need to do is turn a knob to enable the camera and then press the capture button. Everything is automatic; there are no settings to change, no PC is required, there's no waiting for software to load, and the picture looks perfect."

Another benefit is "the seamless way in which I can show patients photographs of their own eyes," Mamtora adds. "They really appreciate this, and as a result, they understand their condition better, are hopefully more compliant with their treatments, and will have better outcomes."

Dr. Snyder is a long-time (15-year) user of the IM 900; recently, he has been introduced to the IM 910 3D. He says: "The resolution of the device is high enough and the 3D voxels are good enough to complete the eye exam entirely without oculars for the robust majority of cases. Individual circulating anterior chamber white blood cells or red blood cells (RBCs) can be readily visualized and RBCs can be seen on the 3D screen as they flow through perilimbal capillaries." This level of digital resolution, without being coupled to the oculars "significantly improves the ergonomics of the slit lamp exam," he observes. "The high-quality digital record holds the promise of capturing the

entire clinical exam remotely, which could eventually improve efficiency for physicians and reduce waiting times for patients."

### The smart choice

The IM 910's smart features – including an algorithm that auto-selects the best image for the user – brings the technology one-step closer to "an entirely automatically captured slit lamp imaging protocol," says Snyder. "The auto-selection algorithm seems like a ripe opportunity to take advantage of AI. If we can fully digitize the slit lamp exam, AI diagnostic tools will not be far behind."

For Mamtora, the intelligent image processing and capturing software are "quite magical." He explains: "I can look through the oculars without turning away from the patient to look at a screen – when I see something that I think would be clinically useful to photograph, I can just press a single button. In the vast majority of cases, the photos and videos that are captured are exactly what I wanted – without the need to change any settings or distract myself from my examination."

He adds: "The IM 910's smart features have changed the way many of my colleagues view slit lamp imaging – from a chore to something that is relatively effortless."

### Documentation: "A picture speaks a thousand words"

The IM 910's addition of 3D vs "flat" images enriches the documentation process while enhancing the quality of materials. "The presence of 3D gives you more confidence to look at a photo and video and question what more could be added by examining the patient directly," explains Mamtora. "The most beneficial aspects of 3D are being able to ask for advice from senior or specialist colleagues who haven't examined the patient themselves and to show patients their own examination in a more immersive way."

Snyder adds that ophthalmologists are "used to visualizing anatomy in 3D. This



Sunil Mamtora



Michael E. Snyder



system brings that microscopic anatomy within the grasp of patients and their loved ones and, for the first time, allows the surgeon to complete an examination in an entirely digital modality.”

The IM 910 3D can also be integrated into many different environments, such as Haag-Streit's EyeSuite, or ophthalmologists' EMR or DICOM systems – providing, says Snyder, “an excellent way to document complex pathology for future comparison and, of course, become a pre-requisite for the remote digital exam.” With the device also permitting documentation of the state of the eye at the time of exam, he adds, it ultimately “fulfills the old axiom that ‘a picture speaks a thousand words.’”

“The other benefit,” says Mamtora, “is for patients to see their own slit lamp examination. They love this, and it's rewarding for the ophthalmologist. I recently saw a patient who had been referred with a suspicious iris lesion. I was able to take a video and then instantly show the patient the lesion on a 3D tablet.”

#### Teaching and learning: “Aha” moments

One of the reasons behind Mamtora's passion for slit lamp imaging is its educational potential. In the past, however, he found slit lamp examination “a challenging skill to learn, and I'm sure I'm not alone.” He goes on, “Developing skills in slit lamp examination is not just about being able to operate the slit lamp, but also to recognize what you are seeing. While the ability to record videos of pathology allows learners to see what they are meant to see, this can often take a long time to learn.”

And the addition of 3D “transforms medical education,” Mamtora says. “Students can put on a pair of 3D glasses and watch the examination live in 3D. This has been valuable for training courses we have delivered in the hospital, as well as giving a high-

quality learning experience to medical students, optometrists, nurses, and many others! I wish I could have had something like this when I was beginning my career.”

Snyder has previously used monocular “teaching” viewers attached to a beam splitter; but these optical tubes, he says, “are an ergonomic nightmare, and when the examiner moves the slit lamp abruptly, it can bump the eye of the observer. With the IM 910 3D, the examiner and observer are seeing the exact same thing at the exact same time, and without any parallax error. With that, “teaching becomes increasingly effective, whether the examiner is the learner or the observer,” says Snyder. Consequently, he anticipates “a much higher density of ‘aha’ moments.”

The IM 910 3D works very well for one-on-one teaching, but it can also extend the benefits to a much larger group of observing learners, limited only by the access to the 3D screen or availability of 3D projection, Snyder continues. “A whole room full of people can simultaneously see the expert clinician's exam, and with the recording function, the teaching can continue asynchronously without the presence of the patient. Grand Round programs that include a patient exam will no longer need to inconvenience the subject patients.”

#### The future: teleophthalmology

In recent years, especially following COVID-19, teleophthalmology\* has been on the rise. One way that Mamtora sees slit lamp imaging, and in particular 3D imaging, supporting

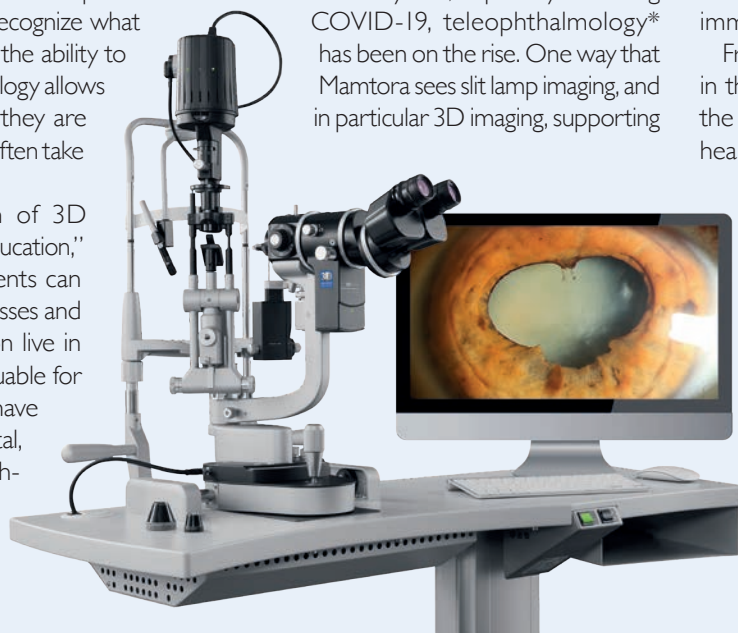
teleophthalmology in UK, for example, is in the referral of patients from optometrists to the hospital eye service. “Being able to more effectively triage referrals by realistically reviewing what was seen by the referring optometrist can allow us to manage patients with advice and guidance, rather than bringing patients for hospital appointments that they might not need,” he explains.

Looking beyond nations and borders, using the IM 910 has enabled Mamtora and his colleagues to stream slit lamp examinations globally as part of an online education program. “This technology can let you get an expert assessment of a patient from anywhere in the world.”

For Snyder, working in the US, where the IM 910 3D is already approved for use in teleophthalmology, this scenario is a reality rather than a future aspiration. “Remote consultation, whether local or distant, will likely usher in an environment in which the physician may first meet a patient in person in the operating room.” This increased efficiency will become a welcome modality to deliver needed care on a timely basis. Snyder goes on, “Remote, long-distance consultation may prime the patient and physician for an eventual in-person visit.” What's more, it can bring “extreme subspecialty care to patients who may not be able to travel to tertiary referral centers either due to cost, time, health, or even visa or immigration limitations.”

From improving access to specialist care in the developing world to strengthening the efficiency of patient pathways within healthcare systems, the potential for slit lamp imaging technology to transform ways of working is significant, agrees Mamtora. He concludes, “3D slit lamp imaging from the IM 910 3D is going to provide many new ways of working that we haven't even thought of yet!”

*\*Available in the USA only, not available in the EU*





*Lightbulb  
Moment:*

THE FUTURE REALITY  
OF ARTIFICIAL  
INTELLIGENCE



*The Ophthalmologist's 2024 Power Listers set out their hopes and predictions for AI's growing role in diagnostics, patient care, and practice management*

Ophthalmology is at the brink of change – one driven not by human hands, but by lines of binary code and algorithms. Yes, the era of artificial intelligence (AI) is upon us. And on whichever side of the AI fence you sit, the technology looks set to spread unceasingly across ophthalmology – just as it will across many other industries and society at large. As our 2024 Power Lister Ben LaHood (Adelaide Eye and Laser Centre) says, “We are going to see AI revolutionize ophthalmology to the same scale that the internet has changed our everyday lives. It will be everywhere and in everything we do as eye surgeons. Like all new technologies, there will be pros and cons of adoption, but just like the internet, there is no turning back now.”

LaHood may touch on the familiar sense of caution that surrounds the AI debate, but, make no mistake, he is excited about AI’s potential. “Ophthalmology is such a data-rich speciality that it lends itself to teaching systems to do almost all aspects of our work in a more accurate, safer, and more efficient manner,” he says. “As a refractive surgeon, I see AI becoming far better than me, for example, at determining the risk of ectasia and incorporating corneal shape into laser surgery treatments. Tasks that currently seem insurmountable, due to having too many interrelated variables, such as predicting surgically induced astigmatism, will become historical relics.”

## OCT IMAGING and DIAGNOSTICS

LaHood’s enthusiasm reflects the positive reactions we received from many of our 2024 Power List alumni when we asked them, “How do you think AI and machine learning will impact ophthalmology?”

Many are looking forward, for example, to AI’s impact on advancing the diagnostic potential of optical coherence tomography (OCT). Arthur Cummings of Wellington

Eye Clinic, Dublin, anticipates that “much of our image-based work will be performed by AI, and it will likely be more accurate than what we did before,” with AI doing “a better job of detecting glaucoma progression from analyzing OCT images and visual fields.” Likewise, H. Burkhard Dick, of the University Eye Clinic Bochum, Germany, foresees the technology turning OCT and other diagnostic tools “into powerhouses for the detection of systemic diseases, such as arterial hypertension and diabetes mellitus.” Moreover, it will “support, maybe even revolutionize, the diagnostics of diseases from other disciplines that have an impact on our patients, e.g., multiple sclerosis, dementia, Parkinson’s, and cardiological and endocrinological ailments.”

*“AI will help also to turn OCT and other diagnostic tools ‘into powerhouses for the detection of systemic diseases, such as arterial hypertension and diabetes mellitus.’”*

The Beijing Tongren Eye Center’s Ningli Wang positions AI as key to “achieving cellular-level resolution through OCT technology.” He explains, “The upcoming ‘OCT+X’ technologies, such as OCT combined with adaptive optics, Doppler imaging, and terahertz imaging, will push ophthalmic imaging to unprecedented levels of precision.”

And Christina Y. Weng of Cullen Eye Institute, Texas, adds that one of the most exciting applications of AI is “an emerging technology called home OCT.” She explains, “These AI-supported devices facilitate remote monitoring by allowing patients to self-capture daily retinal scans that could promote earlier disease detection and bring us one step closer to personalized medicine.”

I. Paul Singh of The Eye Centers of Racine and Kenosha, Wisconsin, USA, agrees that AI will not only allow for the earlier detection of diseases, such as retinopathy and glaucoma, but will also “help us to understand the progression of those diseases earlier than we can now.” AI, he goes on, “will help us to identify which patients will benefit from a particular therapy, which glaucoma technology or technique to use, which IOL to implant, or even which medication to utilize.” From a diagnostic perspective, Singh adds, “AI can help us to perform more accurate and targeted surgery.”

This progress, in turn, will bring diagnostics and disease





Clockwise from top left: Allen C. Ho; H. Burkhard Dick; Ranya Habash


monitoring to a much larger population, observes NHS England's National Clinical Director for Eye Care, Louisa Wickham. "I think this could be of value globally, particularly in countries that may be able to afford the equipment but do not have the expertise to analyze the data. It could help to support disease prevention and early diagnosis and treatment in populations that currently have very low access to health care." AI can enhance autonomous diagnostics relatively inexpensively, adds Wills Eye Hospital's Joel S. Schuman, and this is key to enabling access to care in regions without adequate numbers of ophthalmologists and subspecialists.

## **PATIENT CARE *and* MANAGEMENT**

Of course, medicine involves not just diagnosis, but patient management. Sonia H. Yoo of Bascom Palmer Eye Institute, Florida, looks forward to AI helping "decipher which patients should get which kinds of lens implants, identify which keratoconus patients to crosslink prior to them advancing, and see which patients need corneal transplant rejections and treat them accordingly." Wills Eye Hospital's Allen C. Ho

believes AI can help to improve our understanding of vision loss in patients, which "will help us develop and provide better care." The technology will be able to assist in "better selecting the best-fit IOL for an individual's lifestyle," observes Arthur Cummings. Hopefully, adds David Lockington of the Tennent Institute of Ophthalmology, Scotland, "the machines will talk to the patient, talk to each other, and then tell us which IOL is best for each individual patient's needs and lifestyle, or which topical medications will best optimize the patient's ocular surface based on bespoke molecular tear film analysis."

The integration of generative AI with connected devices will lead to a "continuous feedback loop between patient data, machine learning (ML) models, and precision treatment



Clockwise from top left: Francesco Carones; David F. Chang; Christina Y. Weng; Ben LaHood

strategies,” predicts Bascom Palmer’s Ranya Habash; this will facilitate “an ever-improving understanding of human health and, indeed, “could usher in a new age of medicine.”

As well as helping ophthalmologists provide better care for patients, AI will help to facilitate “large clinical studies on natural history and the benefits of treatment,” says Bascom Palmer’s Harry W. Flynn, Jr. Further, it will “allow residents and fellows in training to improve their knowledge base, which will secondarily impact the quality of care of patients in the field of ophthalmology.”

## The HUMAN TOUCH

A more contentious area of AI in ophthalmology is the question of where the “human doctor” resides in this future landscape. Do you conjure up dystopian scenarios – with frantic

ophthalmologists locked out of their practices, banging on the windows as the machines “take over?” Or is your AI-fueled world utopian, with doctors and machines working together in harmony to see that the practice runs extra smoothly?

Certainly, Christopher J. Rapuano of Wills Eye Hospital is hopeful that AI will reduce “many of the tedious tasks physicians need to do every day, such as writing progress notes.” Michael F. Chiang notes that, when AI becomes successful in assisting with real-world diagnosis, “clinical practice may shift toward management.” He explains, “This will involve detailed communication, empathy, and shared decision-making between patients and clinicians based on risk-



benefit tradeoffs, personal values, and so on. I am concerned that clinicians are losing these nuanced skills in an era of electronic health records (EHRs), copy-paste, and text templates – we will need to do more to cultivate those skills in the future.”

For Chiang, then, the rise of AI could, ironically, help regain some of those “lost” human skills. Gus Gazzard of Moorfields Eye Hospital, London, agrees: faster, more accurate, diagnoses with less room for “in my opinion” will create an “ever greater need for simple communication and compassionate discussion about risk and prognosis with anxious patients.”

As for AI “replacing” surgeons, Allen Ho is looking forward to AI’s impact on “precision image-guided robotic surgery,” while Charles McGhee says boldly that he “fully expects robotic surgery will replace the cataract surgeon within a decade.” David Chang of the University of California, San Francisco is also “optimistic about the feasibility of fully autonomous robotic cataract surgery” – noting that “the hardware is already viable and workable” – but cautions that developing AI-powered, machine learning software “will be the main challenge for an autonomous cataract surgical robot.” That said, he notes that some industry experts are suggesting that the creation of such a system will be less challenging than creating fully autonomous vehicles. “The beauty is that robotic hardware and software can be scaled and duplicated much faster and for less cost than training and employing a comparable number of new cataract surgeons.”

But Chang goes on to say that cataract surgeons “will still be needed for more difficult cases and to supervise and monitor the autonomous systems.” Indeed, the notion that human ophthalmologists will need to stay at the forefront of the patient management landscape of the future is one that is widely shared by both those who are optimistic and those who are cautious about AI. “Personally, I believe that AI and ML will only serve to support the future of ophthalmology,” leading to “greater efficiency, more patients, and, ultimately,

more sight saved,” says Stephanie Watson of the University of Sydney.

“AI will not revolutionize ophthalmology on its own,” notes Marie-José Tassignon of the University of Antwerp. “It needs ophthalmologists to guide the scientists involved in the development of AI.

There is plenty of potential here, but how far we go depends on making the right choices; it is about defining how AI can best serve our specific needs in the field.”

Says Bascom Palmer’s Richard K. Parrish II: “The biggest value of AI and machine learning will be helping patients realize that care and humanity is a unique component of a doctor-patient relationship, not an abstract concept defined in cyberspace.”

Meanwhile, Adviala Vision’s Francesco Carones does not believe that AI will replace human relationships. He says, “I believe that direct interaction with patients – to try to understand their fears and desires, and the compromises they are willing to accept – will remain fundamental in helping them make the most appropriate choices.”

*“When it comes to AI and healthcare, ‘we’re still in the 1870s,’ says Pearse Keane. ‘I see parallels between where we are now and the dawn of the electrical age.’”*

### Let THERE be LIGHT...

But perhaps we should give the last word to Pearse Keane. As well as being a consultant ophthalmologist at Moorfields Eye Hospital in London, Keane is Professor of Artificial Medical Intelligence at UCL. As such, he has been more deeply involved in the theory and application of AI and ophthalmology – and for a longer time – than many of his peers.

“The patient experience is profoundly rooted in human interaction with a clinician,” he agrees. “There is no replacement for an ophthalmologist when it comes to patient communication, nuanced decision-making, and in delivery of care such as surgery. The real power of AI in our profession lies in helping us tackle the challenge of growing waiting lists – by enabling more accurate triage and referral of patients at community level.”

And for Keane, another reason that we can afford to pause and



Clockwise from top left: Michael F. Chiang; Sonia H. Yoo; Pearse Keane; I. Paul Singh

take a more considered view of the coming of AI is that “we’re still in the 1870s,” when it comes to AI and healthcare. “I see parallels between where we are now and the dawn of the electrical age,” he explains. “The electrical age officially began on September 4, 1882, when the switch was flipped at Thomas Edison’s power station in lower Manhattan, providing electricity to households in New York. By the end of the month, Edison’s company had 59 customers; the next year, 513.” That moment in 1882 was “the culmination of 20 years of experimentation with more than 20 different prototype lightbulbs, but the bulb was only one small part of the story,”

continues Keane. “Before the lightbulb could work, you needed a reliable source of electricity; a distribution system – i.e., the ‘grid;’ a connection system; and a measurement system. A network of innovations was needed before the lightbulb could be adopted as a viable, widespread alternative to candlelight.”

We need a similar supporting ecosystem in place to take advantage of the massive potential of AI in healthcare, says Keane. “That includes considerations such as integration with imaging devices and administrative systems, an effective and user-friendly interface with clinicians, having a viable business model, and a forward-looking regulatory system, which, in the case of AI as a medical device (AIaMD), is still evolving.”

If the current state of healthcare AI is, then, analogous to the dawn of the electrical age, we have a little bit of time to further illuminate the one-way road that lies ahead.



## Success with Centurion® with Active Sentry®

### Real-world surgeon experiences performing cataract surgery using Centurion® with Active Sentry® at more physiologic IOP

Since its launch in 2019, use of Centurion® with Active Sentry® at more physiologic IOP has been adopted by surgeons globally. Dr. David M. Lubeck (US), Dr. Gábor B. Scharioth (Germany), Dr. Zaina Al-Mohtaseb (US), and Dr. Hugo Scarfone (Argentina) have each been using Centurion® with Active Sentry® for 2-4 years and are operating at 20-30 mmHg IOP or moving towards those levels. These surgeons were interviewed to discuss their experiences and stated that operating at more physiologic IOP may improve intra- and postoperative outcomes,<sup>1-18</sup> enhance patient satisfaction,<sup>4,7</sup> have positive effects on surgeon confidence and knowledge transfer, and may reduce procedure time.<sup>5</sup>

Using Centurion® with Active Sentry® at more physiologic IOP improves patient outcomes and provides procedural benefits.

	Number of years in practice	Number of years using Centurion® with Active Sentry® at more physiologic IOP
David M. Lubeck, MD	34	4
Gábor B. Scharioth, MD, PhD	25+	3+
Zaina Al-Mohtaseb, MD	10+	2
Hugo Scarfone, MD	35	4

Abbreviations: IOP = intraocular pressure; MD = Doctor of Medicine; mmHg = mm of mercury; PhD = Doctor of Philosophy; US = United States.

*Q: In your experience, what are the advantages in terms of outcomes when performing cataract surgery at more physiologic IOP using Centurion® with Active Sentry®?*

#### Intraoperative outcomes

*Dr. Lubeck:* Using Centurion® with Active Sentry® at more physiologic IOP has made a positive impact on irrigation solution usage, aspiration and total case time, and has enhanced patient comfort due to mitigation of reverse pupillary block (RPB).<sup>1,5,6,9</sup>

*Dr. Scharioth:* A study comparing 102 eyes each at infusion pressures of 20 or 60 mmHg using Centurion® with Active Sentry® for phacoemulsification showed benefits in case and aspiration time, and irrigation solution usage for the 20 mmHg group with no differences between groups in ultrasound time.<sup>5</sup> Additionally, even with very small incisions, the anterior chamber remains stable during phacoemulsification at more physiologic IOP.<sup>19</sup> Lastly, RPB is mitigated at more physiologic IOPs,<sup>1</sup> such as around 20 mmHg, which can reduce associated patient pain/discomfort,<sup>6,9,20</sup> and stress on the posterior capsule anterior hyaloid membrane.<sup>8</sup>

*Dr. Al-Mohtaseb:* While the amount of irrigation solution used depends on the patient's nuclear density,<sup>4</sup> RPB is typically associated with patient discomfort and can be mitigated with

*“Using Centurion® with Active Sentry® at more physiologic IOP has made a positive impact on irrigation solution usage, aspiration and total case time, and has enhanced patient comfort due to mitigation of reverse pupillary block (RPB).<sup>1,5,6,9</sup>”*

fewer IOP fluctuations.<sup>6</sup> I am excited to see the benefits from using Centurion® with Active Sentry® as I move towards operating at 30 mmHg.

*Dr. Scarfone:* Our study evaluated 40 patients each at infusion pressures of 80 or 30 mmHg with comparable nuclear densities who were operated on with Centurion® with Active Sentry®.<sup>9</sup> We found no differences in ultrasound time or use of irrigation solution between the two groups. However, we did find a higher prevalence of anterior vitreous detachment in the 80 mmHg infusion pressure group.<sup>9</sup> Our findings suggest that targeting a more physiological IOP may help control the severity and discomfort of RPB in high-risk patients, such as those who are young, myopic, or

have previously undergone vitrectomy.<sup>1,3,6</sup>

### Postoperative outcomes

*Dr. Lubeck:* Operating at more physiologic IOP reduces corneal swelling and anterior segment inflammation in the early post-operative period, enhances endothelial cell protection, and results in clearer corneas post-operatively.<sup>10-14</sup> Patients with clearer corneas commonly report improved vision.<sup>21</sup>

*Dr. Scharioth:* Phacoemulsification at more physiologic IOP alleviates stress on the posterior capsule anterior hyaloid membrane barrier, potentially decreasing lens dust in the anterior vitreous and reducing postoperative inflammation.<sup>8,9,15,22</sup>

*Dr. Al-Mohtaseb:* As a cornea specialist implanting premium IOLs, I've observed less corneal edema and anterior segment inflammation within one day post-surgery when I perform phacoemulsification moving towards a more physiologic IOP.<sup>13</sup> However, nuclear density and probe to cornea proximity also influence postoperative outcomes.<sup>23</sup> Lastly, operating at lower IOP may lead to less change in size of the foveal avascular zone.<sup>16-18</sup>

*"My patients are thrilled when they can see clearly one day after surgery!"*  
- Dr. Al-Mohtaseb

*Dr. Scarfone:* Our study found no differences in corneal swelling, endothelial cell loss, or postoperative inflammation among 40 patients each, with similar nuclear densities, who were operated on using Centurion® with Active Sentry® at 80 or 30 mmHg.<sup>9</sup> However, only the high infusion pressure group experienced an increase in macular thickness compared to baseline.<sup>9</sup>

**Surgeons agree that using Centurion® with Active Sentry® at more physiologic IOP does not impact the anterior chamber volume/depth during surgery.**

### Post-occlusion surge

*Q: Can you describe your experience with post-occlusion surge events when using Centurion® with Active Sentry® at more physiologic IOP?*

*Dr. Lubeck:* The frequency and magnitude of post-occlusion surges are indistinguishable when operating at more physiologic versus higher IOP levels. This ensures minimal impact on the surgery's flow and efficiency.

*Dr. Scharioth:* In 102 eyes operated on with Centurion® with Active Sentry® at 20 mmHg, Active Sentry® engaged less during nucleus removal than in the 102 eyes operated on at 60 mmHg.<sup>5</sup>

*"Since post-occlusion surge represents the moment of highest risk for complications during the procedure, such as posterior capsule rupture (PCR), the ability to minimize such events using Centurion® with Active Sentry® is valuable."* – Dr. Scharioth

*Dr. Al-Mohtaseb:* I can't remember the last time I encountered a detectable post-occlusion surge event using Centurion® with Active Sentry® at more physiologic IOP.

*Dr. Scarfone:* Suzuki et al.'s study in pig eyes mirrors my clinical experience where Centurion® with Active Sentry® reduces surge volume and enhances anterior chamber stability.<sup>19</sup> I don't worry about surge events during surgery since the compensatory mechanism kicks in automatically!<sup>5,19</sup>

Both typical and complex cases can be completed satisfactorily when using Centurion® with Active Sentry® at more physiologic IOP.

**Surgeons agree that subgroups of patients, such as those who are high axial myopes, have pseudoexfoliation, have low endothelial cell density, or have denser nuclei, can benefit from the enhanced anterior chamber stability of using Centurion® with Active Sentry® at more physiologic IOP.** <sup>20; 24; 25</sup>

### Patient satisfaction

*Q: How would you describe the level of patient pain, discomfort, and satisfaction when using Centurion® with Active Sentry® at more physiologic IOP?*

*Dr. Lubeck:* Patients are comfortable while operating at more physiologic IOP which allows them to converse with me and position the eye as requested.<sup>20</sup> I find that patients feel empowered and have a sense of pride in contributing to their successful outcomes and sense of well-being.

*Dr. Scharioth:* Patients rarely complain of discomfort when phacoemulsification is performed with Centurion® with Active Sentry® at more physiologic IOP.<sup>7,9,20</sup> are often surprised at how quick the procedure is, and are satisfied post-surgery.

*Dr. Al-Mohtaseb:* Our patients report they are more comfortable when phacoemulsification is performed at more physiologic IOP.<sup>9,20</sup>

*Dr. Scarfone:* My patients feel minimal pain or discomfort when the infusion pressure remains low.<sup>9</sup> In our study, the 30 mmHg pressure group had better subjective perception (measured with the Wong-Baker FACES Pain Rating Scale) than the 80 mmHg infusion pressure group (P=0.0001).<sup>9</sup>

Performing phacoemulsification with Centurion® with Active Sentry® at more physiologic IOP enhances confidence and training.

### Surgeon confidence and training

*Q: How has using Centurion® with Active Sentry® at more physiologic IOP influenced your confidence and the confidence and learning curve of surgeons adapting to operating at this IOP level?*

*Dr. Lubeck:* Using Centurion® with Active Sentry® at more physiologic IOP is an intuitive experience, bringing me immense satisfaction with outcomes at the end of each day. Initially I was skeptical, like most

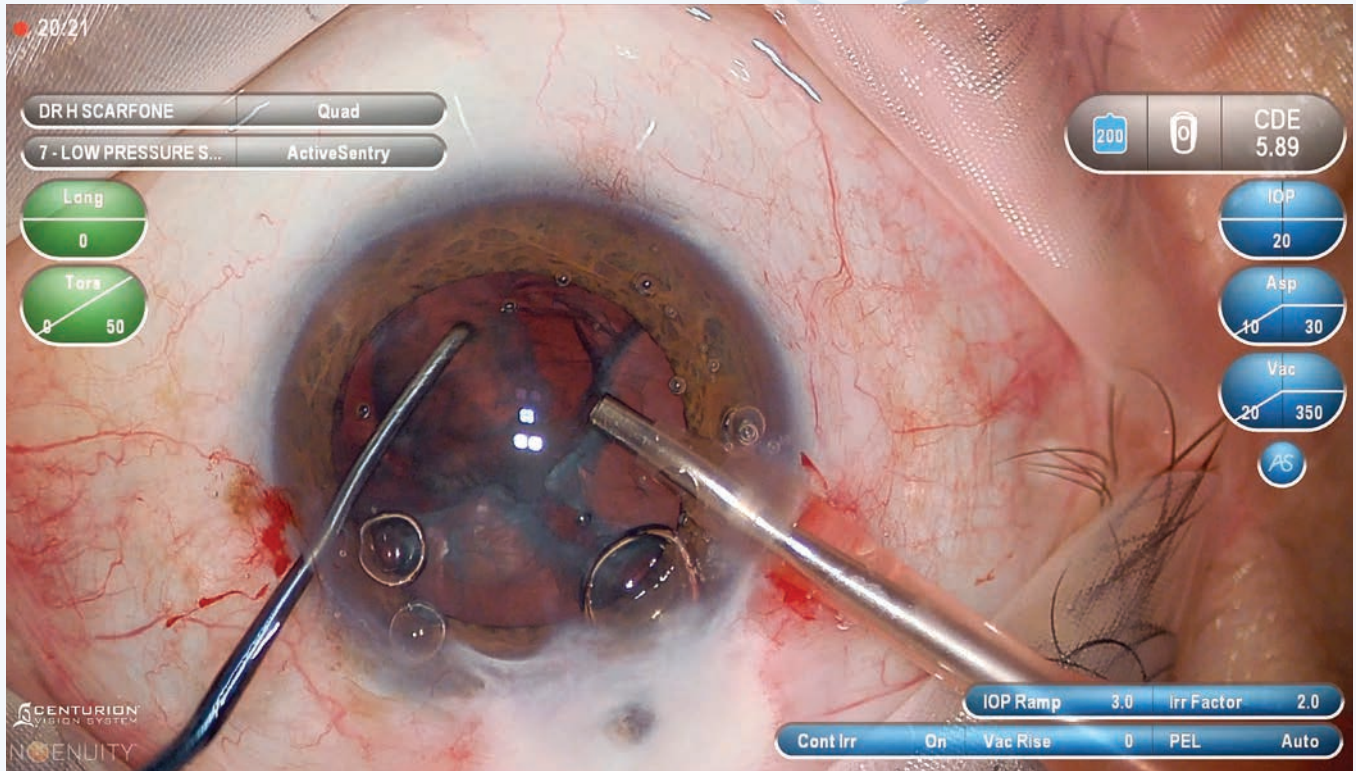


Figure 1: Real-Life Experience with Centurion® with Active Sentry® at More Physiologic IOP

surgeons, however, I found that adopting these parameters was straightforward and did not require significant changes to my surgical technique.

*Dr. Scharioth:* I feel safe and confident using Centurion® with Active Sentry® for phacoemulsification at infusion pressures below 30 mmHg, I have even gone below 25 mmHg. Experienced surgeons adapt comfortably to lowering their infusion pressure.

*Dr. Al-Mohtaseb:* Centurion® with Active Sentry® ensures anterior chamber stability and prevents post occlusion surge,<sup>5</sup> aiding in trainee surgeon education.

*Dr. Scarfone:* Operating at more physiologic IOP boosts my confidence in both routine and challenging cases and benefits patients. I recommend starting at 50 mmHg and gradually lowering to 30 mmHg as confidence and proficiency develop.

Centurion® with Active Sentry® at more physiologic IOP offers numerous practice benefits, improving efficiency.

#### Economics

*Q: How has using Centurion® with Active Sentry® at more physiologic IOP affected the procedure volume of your practice?*

*Dr. Lubeck:* Performing cataract surgery with Centurion® with Active Sentry® at a more physiologic IOP has yielded intraoperative efficiencies that reduce procedure time.<sup>5</sup>

*Dr. Scharioth:* Centurion® with Active Sentry® at more physiologic IOP reduces treatment costs of RPB due to its mitigation,<sup>1</sup> lowers case time,<sup>5</sup> and ultimately enhances surgical capacity amidst rising expenses.

*Dr. Al-Mohtaseb:* In my experience, I perceive that I am more efficient using

*“I feel safe and confident using Centurion® with Active Sentry® for phacoemulsification at infusion pressures below 30 mmHg, I have even gone below 25 mmHg.”*



*“My favorite days are in the OR performing cataract surgery using Centurion® with Active Sentry® at more physiologic IOP.”*

Centurion® with Active Sentry® moving towards a more physiologic IOP due to lower case time and reduced irrigation solution usage than when operating at higher IOP.<sup>5</sup>

Dr. Scarfone: Centurion® with Active Sentry® at more physiologic IOP reduces anterior vitreous detachment.<sup>9</sup> Recently, the number of surgeries I perform has increased, and my practice is thriving! Efficiencies gained with Centurion® with Active Sentry® as well as the use of premium IOLs leave my patients feeling satisfied and prompts more referrals.

*“My patients are very satisfied with their results which I believe has contributed to the practice’s growth. Working alongside my team, we’ve gained confidence and are happier with the work we do, which has led to even better results.”* – Dr. Scarfone

#### Real life experience

Dr. Lubeck: My favorite days are in the OR performing cataract surgery using Centurion® with Active Sentry® at more physiologic IOP. My second favorite days are the first day after surgery where I relieve the patients surgical experience and outcomes with them.

Dr. Scharioth: I find satisfaction in performing phacoemulsification using Centurion® with Active Sentry®, especially in complex patients such as those with a hard nucleus, weak zonules, and small pupils, or those with intraoperative floppy iris syndrome.<sup>24, 25</sup>

Dr. Al-Mohtaseb: Every day I perform complex cases with comfort and confidence knowing that the surgery will go smoothly.

Dr. Scarfone: The optic nerve of glaucoma patients is less resilient to hypoxia, often caused by high and fluctuating IOP.<sup>26</sup> I operated on a 68-year old patient with severe glaucoma, perforated filtration bleb, and cornea guttata (Figure 1). Operating with Centurion® with Active Sentry® at 20 mmHg allowed for a fluctuation-free environment and offered protection towards the optic nerve. In these situations, I am confident that I am providing the best care possible for my patients.

#### CENTURION® VISION SYSTEM IMPORTANT PRODUCT INFORMATION

**Caution:** Federal (USA) law restricts this device to sale by, or on the order of, a physician.

As part of a properly maintained surgical environment, it is recommended that a backup IOL Injector be made available in the event the AutoSert® IOL Injector Handpiece does not perform as expected.

**Indication:** The Centurion® Vision System is indicated for emulsification, separation, irrigation, and aspiration of cataracts, residual cortical material and lens epithelial cells, vitreous aspiration and cutting associated with anterior vitrectomy, bipolar coagulation, and intraocular lens injection. The AutoSert® IOL Injector Handpiece is intended to deliver qualified AcrySof®

intraocular lenses into the eye following cataract removal.

The AutoSert® IOL Injector Handpiece achieves the functionality of injection of intraocular lenses. The AutoSert® IOL Injector Handpiece is indicated for use with the AcrySof® lenses SN6OWF, SN6ADI, SN6AT3 through SN6AT9, as well as approved AcrySof® lenses that are specifically indicated for use with this inserter, as indicated in the approved labeling of those lenses.

**Warnings:** Appropriate use of Centurion® Vision System parameters and accessories is important for successful procedures. Use of low vacuum limits, low flow rates, low bottle heights, high power settings, extended power usage, power usage during occlusion conditions (beeping tones), failure to sufficiently aspirate viscoelastic prior to using power, excessively tight incisions, and combinations of the above actions may result in significant temperature increases at incision site and inside the eye, and lead to severe thermal eye tissue damage.

Good clinical practice dictates the testing for adequate irrigation and aspiration flow prior to entering the eye. Ensure that tubings are not occluded or pinched during any phase of operation.

The consumables used in conjunction with ALCON® instrument products constitute a complete surgical system. Use of consumables and handpieces other than those manufactured by Alcon may affect system performance and create potential hazards.

**AEs/Complications:** Inadvertent actuation of Prime or Tune while a handpiece is in the eye can create a hazardous condition that may result in patient injury. During any ultrasonic procedure, metal particles may result from inadvertent touching of the ultrasonic tip with a second instrument.

Another potential source of metal particles resulting from any ultrasonic handpiece may be the result of ultrasonic energy causing micro abrasion of the ultrasonic tip.

**ATTENTION:** Refer to the Directions for Use and Operator's Manual for a complete listing of indications, warnings, cautions and notes.


- Cionni RJ, Barros MG, Osher RH (2004) Management of lens-iris diaphragm retropulsion syndrome during phacoemulsification. *J Cataract Refract Surg* 30 (5): 953-956.
- Zeppieri M, Tripathy K (2023) Pigment Dispersion Glaucoma. eds). StatPearls Publishing: StatPearls [Internet].
- Bang SP, Joo CK, Jun JH (2017) Reverse pupillary block after implantation of a scleral-sutured posterior chamber intraocular lens: a retrospective, open study. *BMC Ophthalmol* 17 (1): 35.
- Scarfone HA, Rodriguez ECC (2023) Evaluation of Early Changes of the Anterior Vitreous Interface After Cataract Surgery, Using Low Pressure Settings Determined by OCT. American Association of Cataract and Refractive Surgery (ASCRS). San Diego, California. May 6, 2023.
- Beres H, de Ortueta D, Buehner B, Scharioth GB (2022) Does low infusion pressure microincision cataract surgery (LIPMICS) reduce frequency of post-occlusion breaks? *Rom J Ophthalmol* 66 (2): 135-139.
- Kang YK, Kim MJ, Kim HK, Chun BY (2017) Clinical Analysis of Ocular Parameters Contributing to Intraoperative Pain during Standard Phacoemulsification. *J Ophthalmol* 2017 9463871.
- Ashkenazy S, DeKeyser Ganz F (2019) The Differentiation Between Pain and Discomfort: A Concept Analysis of Discomfort. *Pain Manag Nurs* 20 (6): 556-562.
- Kawasaki S, Tasaka Y, Suzuki T, Zheng X, Shiraishi A et al. (2011) Influence of elevated intraocular pressure on the posterior chamber-anterior hyaloid membrane barrier during cataract operations. *Arch Ophthalmol* 129 (6): 751-757.
- Scarfone HA, Rodriguez EC, Rufiner MG, Riera JJ, Fanego SE et al. (2024) Vitreous lens interface changes after cataract surgery using active fluidics and active sentry with high and low infusion pressure settings. *J Cataract Refract Surg* 50 (4): 333-338.
- Kokubun TT, Yabana, T, Maekawa S, Yokoyama Y, Kunikata, H, Nakazawa, T (2022) The protective effect of normal-IOP cataract surgery on the corneal endothelium. Japanese Ophthalmological Society. Osaka, Japan. April/May 2021.
- Rauen M (2023) Phacoemulsification at high IOP and physiologic IOP: Impact on posterior segment physiology. Association of Cataract and Refractive Surgery (ASCRS) San Diego, California. May 7, 2023.
- Suzuki H, Oki K, Shiwa T, Oharazawa H, Takahashi H (2009) Effect of bottle height on the corneal endothelium during phacoemulsification. *J Cataract Refract Surg* 35 (11): 2014-2017.
- Vasavada AR, Praveen MR, Vasavada VA, Vasavada VA, Raj SM et al. (2010) Impact of high and low aspiration parameters on postoperative outcomes of phacoemulsification: randomized clinical trial. *J Cataract Refract Surg* 36 (4): 588-593.
- Vasavada V, Raj SM, Praveen MR, Vasavada AR, Henderson BA et al. (2014) Real-time dynamic intraocular pressure fluctuations during microcoaxial phacoemulsification using different aspiration flow rates and their impact on early postoperative outcomes: a randomized clinical trial. *J Refract Surg* 30 (8): 534-540.
- Núñez-Álvarez C, del Olmo Aguado S, Merayo-Lloves J, Osborne N (2015) Damage to the corneal endothelial cell in situ is attenuated by long wave red light. ARVO Annual Meeting Abstract. Denver, Colorado. June.
- Zhao Z, Wen W, Jiang C, Lu Y (2018) Changes in macular vasculature after uncomplicated phacoemulsification surgery: Optical coherence tomography angiography study. *J Cataract Refract Surg* 44 (4): 453-458.
- Liu J, Liu Q, Yu H, Xia Y, Zhang H et al. (2021) Microvascular Changes in Macular Area After Phacoemulsification and Its Influencing Factors Assessed by Optical Coherence Tomography Angiography. *Ther Clin Risk Manag* 17 405-414.
- Nourinia R, Kiani A, Hassanpour K, Nikkhab H, Faramarzi A et al. (2023) Optical coherence tomography angiography parameters after cataract surgery. *Int Ophthalmol* 43 (8): 2679-2686.
- Suzuki H, Igarashi T, Takahashi H (2023) Effect of a new phacoemulsification and aspiration handpiece on anterior chamber stability. *J Cataract Refract Surg* 49 (1): 91-96.
- Liu Y, Hong J, Chen X (2023) Comparisons of the clinical outcomes of Centurion® active fluidics system with a low IOP setting and gravity fluidics system with a normal IOP setting for cataract patients with low corneal endothelial cell density. *Front Med (Lausanne)* 10 1294808.
- Mayo Clinic (Web Page) Fuch's dystrophy. Updated March 5, 2022. Available online at: <https://www.mayoclinic.org/diseases-conditions/fuchs-dystrophy/symptoms-causes/syc-20352727>. Accessed: January 18, 2024.
- Sridhar U, Tripathy K (2023) Lens-Induced Inflammation. eds). StatPearls Publishing: StatPearls [Internet].
- Kausar A, Farooq S, Akhter W, Akhtar N (2015) Transient Corneal Edema After Phacoemulsification. *Journal of the College of Physicians and Surgeons Pakistan* 25 (7): 505-509.
- Jirásková N, Stepanov A (2021) OUR EXPERIENCE WITH ACTIVE SENTRY AND CENTURION OZIL HANDPIECES. *Cesk Slov Oftalmol* 77 (1): 18-21.
- Kim HW, Kim I, Kim HS, Kim EC (2023) The comparison of handpiece anti-surge system and main body in cataract surgery. medRxiv
- Luo Y, Xu G, Li H, Ma T, Ye Z et al. (2023) Application of the Active-Fluidics System in Phacoemulsification: A Review. *J Clin Med* 12 (2): 611.

# CHILD'S EYE VIEW: *Current Issues in Pediatric Ophthalmology*

We explore challenging pediatric eye diseases – and the digital tools being developed for their diagnosis and treatment

By Alun Evans and Jamie Irvine





Given a recent JAMA Ophthalmology study by Siegler et al. (1) spotlighting a dearth in the number of pediatric eye care specialists available to large swathes of the US population, we decided it was high time to dig into this oft-overlooked subspecialty of ophthalmology. So, what exactly is happening in this space? We explore some of the most challenging pediatric eye diseases, and survey the digital tools that are helping to improve diagnosis and treatment.

## I. Retinopathy of prematurity

Retinopathy of prematurity (ROP) is a multifactorial disorder characterized by an early stage of retinal microvascular degeneration, followed by neovascularization that can, in some cases, lead to permanent visual loss. One key global challenge in this space is the mismatch between need and service capacity. This is most prevalent in low- to middle-income countries, but also extends to countries where pediatric ophthalmology remains less popular amongst trainees, such as the UK and US.

Another challenge is screening. “The barriers to screening are similar around the world,” says Darius Moshfeghi, Professor of Ophthalmology at Stanford Medicine. They include a lack of specialists, high associated costs, medicolegal risks, geographic dispersion of the at-risk population, and a lack of standardization in programs. However, Moshfeghi believes that “telemedicine, using wide-angle imaging with standardized image sets, mandated weekly exams, central grading sites with experienced expert graders, and implementation of ROP scoring can mitigate most of these barriers.” He also believes that “AI algorithms will supplement and, in some cases, supplant the graders in the future.”

The progress of AI is one of many advances in this space, another being the increased availability and approval of

intravitreal therapies; for example, aflibercept. However, there is work to be done in terms of how clinical and research teams implement these interventions. “Defining the real-world use of the drug, together with inclusion criteria, dosage, timing of administration, and the need for follow-up care and additional interventions, will be crucial,” says Lola Solebo, pediatric ophthalmologist and clinician scientist at UCL GOS Institute of Child Health and Great Ormond Street Hospital, London.

To consider the ROP landscape as a whole, “consolidation and standardization are the order of the day,” says Moshfeghi.

“In the US and elsewhere, telemedicine is centralizing grading of infants at-risk for ROP into centers of excellence.” This, in turn, can lead to

predictable and scalable approaches to

ROP screening, thus minimizing the risk of missing an infant who could benefit from intervention.

Moshfeghi also highlights that this will include a shift towards more objective data-based methods, as opposed to the subjective interpretation of bedside binocular indirect ophthalmoscopic examinations.

The therapeutic and technological developments in ROP are encouraging for families dealing with their child’s diagnosis. However, communication is key. “Unique difficulties and challenges exist when the spectrum of life-threatening and visually disabling disease coexist,” explains Audina Berrocal, Professor of Clinical Ophthalmology and pediatric retina specialist at the Bascom Palmer Eye Institute, University of Miami. Solebo adds, “Families of children with potentially blinding conditions often fear sight loss and blindness to the extent that their fear becomes an obstacle to them understanding or retaining information.”

One potential solution is an integrative team approach that encourages the education of parents, discussion of treatment, as well as alternatives and likely outcomes. “Current specific challenges include the absence of a parent physically present



in the neonatal intensive care unit, differences of opinion within caregivers, and concerns for the potential morbidities of current screening and treatment modalities,” adds Berrocal. However, she states that the use of virtual telemedicine has greatly improved communication for the caregiver and family.

## II. Inherited retinal disease

Inherited retinal diseases (IRDs) encompass an array of diverse conditions, each with a specific genetic makeup. Currently, IRDs are linked to over 270 distinct genes and manifest in varying degrees of clinical severity and inheritance patterns – from blindness in infancy and early childhood to progressive vision loss throughout adulthood. The development of comprehensive and effective therapeutic options against IRDs has proven to be a challenge for scientists. In a recent study, however, Mark Pennesi, Director of Ophthalmic Genetics at the Retina Foundation and Professor of Ophthalmology at Oregon Health and Science University, and his team evaluated the safety and effectiveness of EDIT-101 – an experimental gene editing treatment that uses CRISPR technology – in patients born with a form of leber congenital amaurosis (LCA) driven by CEP290 mutations. CRISPR allows scientists to address mutations in larger genes that might not be candidates for AAV gene therapy; one major issue with CEP290 is that it is too big to fit into the typical AAV vector. Notably, 79 percent of the study participants experienced a measurable improvement after receiving treatment, and there were no procedure-related adverse events. CEP290 mutations account for 20–30 percent of patients with LCA.

CRISPR-Cas9 offers several advantages over previous gene editing technologies as it facilitates targeted gene editing in an efficient, specific, and modifiable manner. Progress with CRISPR-Cas9 research now means that gene editing is a feasible strategy for the treatment of IRDs. Although this is not a cure, Pennesi concludes, “This is an exciting time for patients with IRDs. The demonstration that CRISPR can work in this field will inspire further research in this area and the development of even more potent therapies.”

## III. Strabismus

Strabismus affects 0.14–5.65 percent of children, with an estimated average prevalence of 1.93 percent worldwide. In the US, it is classed as one of the most common medical eye disease diagnoses in early vision care. Janine Collinge, pediatric ophthalmologist and Chair of Public Information Committee with the American Association for Pediatric Ophthalmology and Strabismus (AAPOS) notes that “difficulties with access to

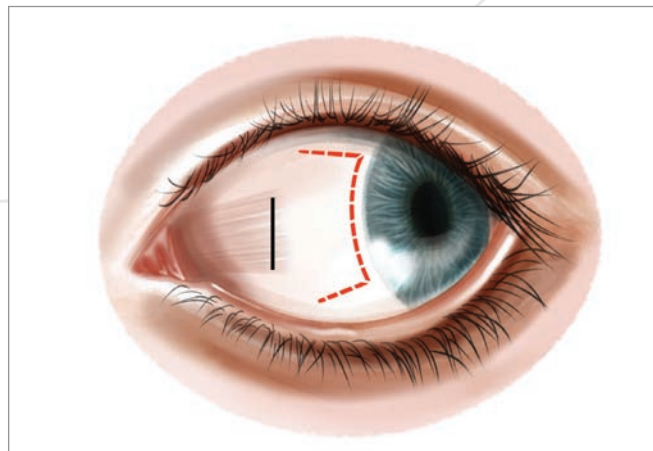


Figure 1. Standard incision for strabismus surgery

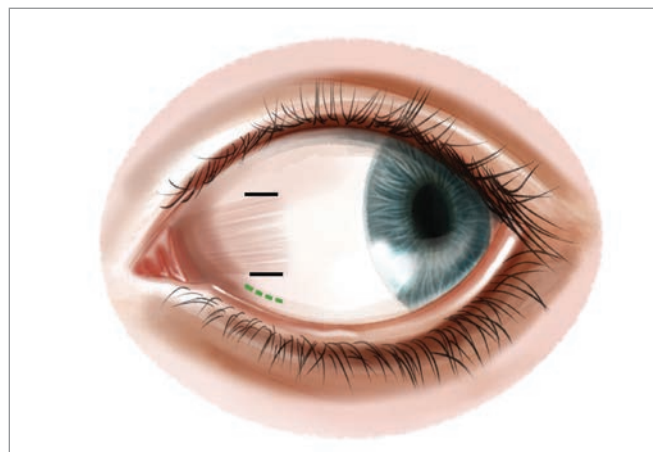


Figure 2. Minimally invasive strabismus surgery

care and low/declining reimbursement for services,” especially in the pediatric arena, is major issue in strabismus. “There is a national shortage of pediatric ophthalmologists, and there are deserts of pediatric eye care across the country,” she says.

The UK is facing similar issues. “Not every place offers the same level of eye care for children” says Saurabh Jain, Consultant Ophthalmic Surgeon and Clinical Director of Services at the Royal Free London NHS Foundation Trust. “Some schools offer pediatric eye screening and some do not, even though it is one of the most cost-effective ways of picking up asymptomatic childhood eye disease,” he adds.

Public awareness of the condition is an important component, with Jain pointing to “a lack of information about eye conditions that affect children and their correct treatment.” Ophthalmologists also face the issue of adequately communicating what strabismus involves and what subsequent treatment of the condition will look like. “Some of the big





Jugnoo Rahi

challenges in patient and family education, in terms of eye care, are reliant on time and appropriate resources,” Collinge notes, with many ophthalmologists not having enough time in their day to educate both patients and families.

Though strabismus treatments have remained relatively unchanged over the years, the industry has seen some surgical progress in recent times. Jain explains how researchers have begun to understand the fact that “the muscles are innervated in such a way that they work within compartments, so this

can be utilized to improve the surgical outcomes by selectively weakening or strengthening the muscle fibers.” He points to a new focus on minimizing the size of the incision used for surgery – both to improve patient outcomes and reduce inflammation. “Minimally invasive strabismus surgery is rapidly becoming the new standard of care,” he says. Figure 1 (in red) shows the standard incision; minimally invasive incisions are shown in green and black in Figure 2.

Surgery incidences in childhood strabismus are witnessing



a decline – especially in the UK and US; Jain believes that the drop could be attributed “to the general improvement in social economic status and nutrition,” as well as “a better understanding of how to manage strabismus in children by non-surgical means, and earlier presentation of children with these problems to an eye clinic.”

However, Collinge is less optimistic, especially given the issues with access to healthcare in the US. “There is concern that increasingly more children may have to suffer with untreated eye disease for long periods in their life,” she notes. “This has the potential to impact vision, learning, and development. It could furthermore impact productivity in adulthood. Only time will tell.”

#### IV. Amblyopia

Amblyopia affects an estimated 1.4 percent of children worldwide. But what if “lazy eye” was an indicator of later health problems? Recently, a study in *The Lancet* suggests otherwise; however, the authors acknowledge the lack of evidence pointing to a causal relationship (2).

“What the study shows is that the average person who had amblyopia in childhood has a higher risk of cardiometabolic disorders in adult life – it doesn’t mean that everyone with amblyopia will develop these disorders,” explains study co-author Jugnoo Rahi, a practicing ophthalmologist and epidemiologist. “But it is very unusual to have a clear childhood ‘marker’ of increased risk of cardiometabolic disorders as an adult – and in the case of amblyopia, a marker that is known for every child due to whole population screening.”

Rahi believes the findings add usefully to the existing evidence base pointing towards the importance of early life as a foundation for lifelong health. “Specifically, they uncover a potential indirect/non-vision benefit of childhood vision

screening to detect amblyopia,” she says. “It would be good to investigate if knowledge of the association was helpful to affected children as they grow up in terms of motivating or maintaining healthy lifestyles, as that would be an important route to a population benefit via child vision screening.”

Given these potential ramifications of amblyopia in later adulthood health, what therapies are currently under development for the disease?

“There have been advances in amblyopia therapies – Dichoptic binocular treatments have recently been FDA approved for use with specific criteria,” says Janine Collinge. “These therapies offer alternatives to traditional patching and atropine treatments for amblyopia.”

Collinge observes that these therapies have been designed for specific types of amblyopic patients, but notes how “cases of treatment success in patients who would otherwise be seen as off-label – older patients, patients with larger angle strabismus, patients with other ocular comorbidities – suggest that these treatments may have the potential to help improve vision in even more people.”

Another alternative, adds Saurabh Jain, consultant ophthalmic surgeon at the Royal Free London NHS Foundation Trust, can be found in binocular summation and technological aids. “One of these is Luminopia, an FDA-approved binocular therapy that uses a virtual reality (VR) headset to stream a child’s favorite [television] show,” Jain says. “Treatment is only one hour a day, six days a week, [and] showed significant vision improvement as early as four weeks into a 12-week clinical trial.” Jain believes that, although the treatment is still very new, the promising results from these early clinical trials indicate that it could present a useful accessory to – or perhaps even completely replace – eye patching.





Ranya Habash

## Digital care

The rapid expansion of artificial intelligence (AI) and machine learning (ML) into healthcare has created a whole new way of approaching telemedicine in ophthalmology. “These technologies not only improve the scope and efficacy of pediatric eye care, but also make it more engaging for children, which is crucial for ensuring their cooperation to improve treatment outcomes,” explains Ranya Habash, the former Medical Director of Technology Innovation at Bascom Palmer Eye Institute.

Habash cites some real-world examples of this tech in practice, including a pediatric glaucoma program set up at Bascom Palmer, which employs the iCare tonometer for remote patient monitoring of intraocular pressure, and Darius Moshfegi work at Stanford, performing tele-ROP screenings and virtual follow-ups by reviewing fundus images captured through portable cameras by staff in remote areas of the US. She also points to RemoniHealth, a company offering remote home monitoring software, which allows for pediatric

patients to “be screened and followed for conditions like amblyopia, strabismus, and macular disease from the comfort of their homes,” and physicians being “reimbursed for this monitoring through RPM and RTM CPT codes.”

Bascom Palmer’s David Tse, an oculoplastic surgeon, offers tele-prosthetics via 3D printing so that patients anywhere in the world can receive them. “This is particularly important for children with tumors or trauma, since they require new prosthetics as their faces grow,” says Habash. “Tse uses a simple photo of the patient, then 3D prints a custom prosthetic using the mirror image of the patient’s face. With this method, we are able to more quickly create prosthetics that are cheaper and more personalized for continual facial growth in kids.”

However, as Ting Fan Tan and colleagues note in 2023 (3), “Much work is required to convince governance bodies to accept new digital health tools... [and] inventors and researchers are [currently] hampered by an unclear, challenging roadmap to the deployment of novel digital health tools.”

Tan’s study goes on to note that, “Resource limitations, especially in [low- and middle-income countries], are another major barrier to implementation. Remote areas often lack the necessary infrastructure to adopt new technologies, due to insufficient equipment, poor internet and electricity coverage, and absence of robust telecommunication networks. This is compounded by scarce funding, with support impeded by bureaucracy, budget restrictions, and high staffing turnover.”

## The road ahead

Policy changes and global cooperation at the highest levels will be needed if this new technology is to reach its full potential. As for the field in general, as Siegler et al. (1) recommend, both practitioner reimbursement and recruitment should be revised if more residents and graduates are to be enticed into the subspecialty. But while there are substantial challenges to overcome in pediatric ophthalmology, on current evidence, the ongoing treatment and knowledge advancements seem to offer hope for the future.

### References

1. NE Siegler et al., “Access to pediatric eye care by practitioner type, geographic distribution, and US population demographics,” *JAMA Ophthalmol.*, 142, 454 (2024).
2. SK Wagner et al., “Associations between unilateral amblyopia in childhood and cardiometabolic disorders in adult life: a cross-sectional and longitudinal analysis of the UK Biobank,” *eClinicalMedicine* (March 7, 2024).
3. TF Tan et al., “Artificial intelligence and digital health in global eye health: opportunities and challenges,” *The Lancet Global Health*, 11, e1423 (2023).

## Harnessing the OMNI Opportunity

**MIGS with the OMNI® Surgical System should be an option for all suitable glaucoma patients at the time of cataract surgery, says Consultant Ophthalmologist Dan Lindfield**

OMNI from Sight Sciences is an implant-free, minimally invasive technology indicated for ab-interno canaloplasty and trabeculotomy to reduce intraocular pressure in adult open-angle glaucoma (OAG) patients. It gives surgeons the option to treat glaucoma at the time of cataract surgery or as a standalone procedure, targets three areas of resistance intended to lower IOP, and delivers sustained long-term IOP reduction.

Dan Lindfield, Consultant Ophthalmologist and Glaucoma Director at the Royal Surrey County Hospital in Guildford was the first in the UK to use OMNI and regularly performs OMNI with and without cataract surgery. Lindfield feels “aligned to the mentality of implant-free surgery.” He explains, “As a rule, MIGS aims to improve or restore physiological drainage and the absence of a foreign body left behind in the angle therefore seems intuitive. Previously there



was no choice, but now we have devices such as OMNI, where an implant-free approach is possible.”

Lindfield thinks of OMNI as a “canal cleaner.” He explains, “Many parallels can be drawn between glaucoma procedures and household plumbing, but clearing the blockage by dilating and ‘flushing’ the system is one of OMNI’s primary mechanisms of action.” He now predominantly performs only viscocanaloplasty with OMNI.

“Generally I prefer not to de-roof the canal by removing trabecular meshwork. There’s emerging evidence that Schlemm’s is a pulsatile, peristaltic system reliant on valves (1) so I prefer to clear the canal and encourage rejuvenation of these natural flow mechanisms”.

He continues, “There’s always a small opening created in the trabecular meshwork during the process of cannulating the canal which acts as the conduit between anterior chamber and the canal. However, it’s useful to have the option to ‘do more’ and add trabeculotomy if patient specifics require. I’m drawn to treating 360 degrees because the disease affects 360 degrees. The beauty of the retractable microcatheter of the OMNI system is that I can access 360 degrees. I’m not limited to treating only what is opposite the corneal incision like other MIGS devices dictate.

Combining OMNI with cataract surgery For Lindfield, MIGS with OMNI should be an option for all glaucoma patients at the time of cataract surgery. “I think if a patient has concurrent cataract and glaucoma, then combining their proposed cataract procedure with a MIGS procedure is an opportunity that should be grasped,” he says. “Bleb-forming MIGS (MIBS) aside, the safety profile and predictability of the post-op journey means most of my glaucoma patients receive a procedure such as OMNI if they are undergoing phaco without negatively impacting our

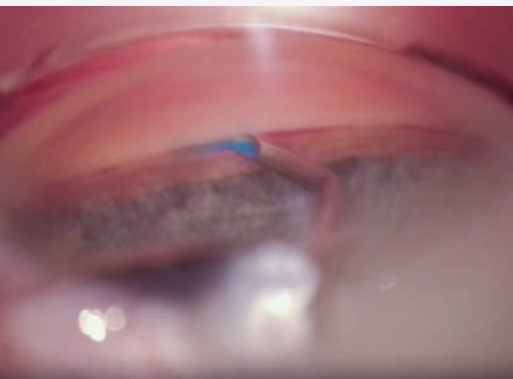
theater efficiency or productivity.” Indeed, Lindfield feels that “not considering MIGS is an opportunity missed.” He goes on, “Hospitals are very well set up for high-efficiency, high-volume cataract surgery. Data and experience illustrates that the addition of MIGS can be appended to a cataract procedure efficiently.

Most theaters lose time with turnaround and set-up, but for OMNI there is minimal set-up, adds Lindfield. “Just open the sterile pack, fill with cohesive viscoelastic and hand to the surgeon. I think adding such devices to the glaucoma surgical options within a hospital benefits patients without negatively impacting cataract workflow because it’s simple and reproducible and fits symbiotically with phaco.”

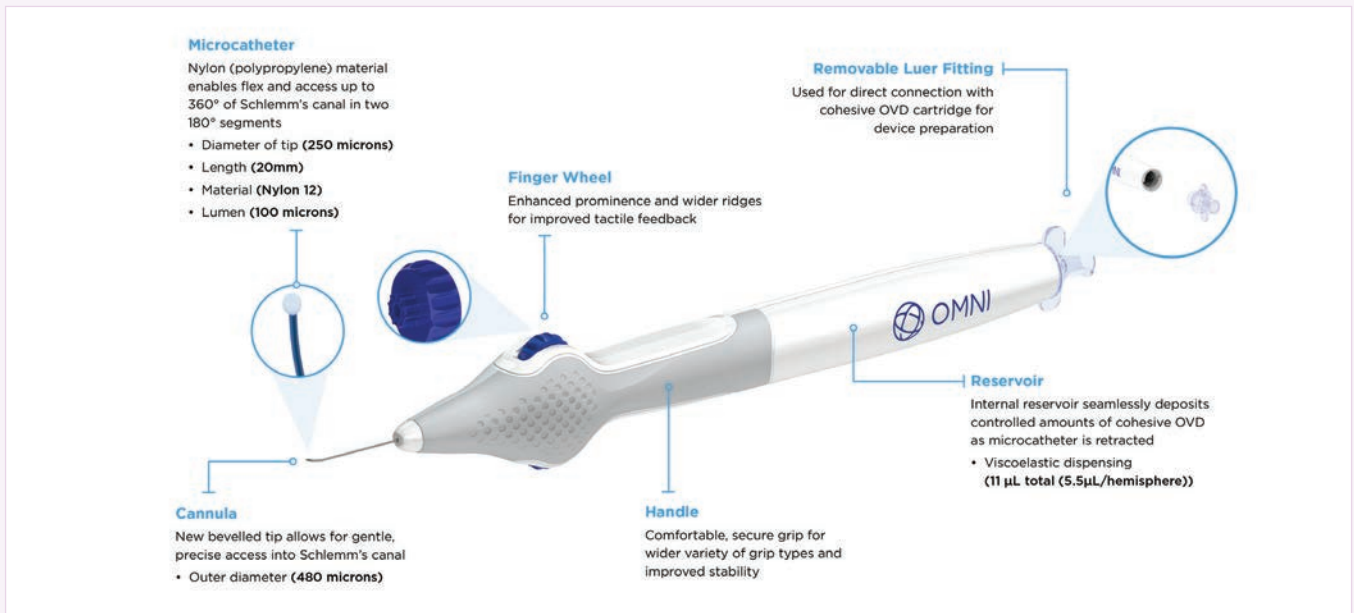### Safety profile

Lindfield points to three key studies supporting OMNI’s safety and effectiveness compared to other procedures: the GEMINI study, which is a prospective series but now has 36 months’ follow-up of 66 eyes (2), and two retrospective studies – ROMEO with 24 months follow-up (3) and the IRIS Registry (4), which provides outcome evidence for large numbers of patients (9000) receiving MIGS procedures. “IRIS offers some comparisons between the commonly available MIGS devices and shows favorable IOP reduction and medication reduction for OMNI compared to both iStent and Hydrus,” explains Lindfield. “I have many patients doing well at three years; our data suggest useful reduction in pressure with minimal adverse events. Our rate of significant hyphema is now less than 2%. Other adverse events, such as hypotony or leaks, have been rare in the clinical studies and not encountered in my practice.”

The post-op care plan for patients who have had OMNI surgery is very similar to cataract surgery alone, notes Lindfield. “Any device creating a conduit between the anterior chamber and the canal effectively breaches the blood aqueous barrier. Therefore, we







should expect some additional inflammation.” Lindfield prefers to inject intracameral Dexamethasone at the end of the procedure to dampen this inflammation for the first 24 hours post operatively. “The risk of spikes is very low, as the drug is effectively cleared within 36 hours,” he says. “Miostat is also proven to reduce pressure spikes by aiding non-conventional outflow while the work completed on the conventional outflow is allowed time to recover. Otherwise, I use my standard cataract regime or topical antibiotic, steroid, and NSAID.”

#### Equal access for suitable patients

The biggest lesson for a MIGS surgeon is “when is MIGS not suitable,” Lindfield continues. “If a patient would do better with filtration surgery, then we shouldn't forget that. However, OMNI combines well with cataract – unlike filtration surgery. The recovery and patient journey with OMNI is superior to filtration. In my practice I consider all cataract patients with open-angle glaucoma as candidates for OMNI. Only a very low-target pressure or an atypical angle would deter me. Care should be taken with anticoagulant/antiplatelet drugs. Canaloplasty is essentially cannulating a vein so some blood reflux is always to be expected. However, with good technique and absence of drugs

that increase bleeding tendency, then clinically significant hyphema is rare.”

Awareness is key to ensuring equal access to OMNI for all suitable patients, says Lindfield. “Glaucoma referral pathways and cataract surgical pathways differ around the world, but I believe that all glaucoma patients having surgery should be made aware of the option of adding MIGS such as OMNI to their cataract surgery.” He concludes, “It would be unwise for a surgeon not to mention the opportunity for a concurrent MIGS procedure to a patient with glaucoma having cataract surgery. It's an opportunity missed.”

#### References

1. M Johnstone et al., Aqueous outflow regulation – 21st century concepts. *Prog Retin Eye Res* 2021;83:100917.
2. MD Greenwood et al., “36-Month Outcomes from the Prospective GEMINI Study: Canaloplasty and Trabeculotomy Combined with Cataract Surgery for Patients with Primary Open-Angle Glaucoma,” *Clin Ophthalmol.*, 17, 3817 (2023). PMID: 38105915.
3. BK Williamson et al., “Canaloplasty and Trabeculotomy with the OMNI System in Patients with Open-Angle Glaucoma: Two-Year Results from the ROMEO Study,” *Clin Ophthalmol.*, 17, 1057 (2023). PMID: 37056792.

4. <https://www.sightsciences.com/us/sight-sciences-announces-12-month-results-from-american-academy-of-ophthalmology-iris/>

Dan Lindfield is a paid consultant of Sight Sciences, Inc.

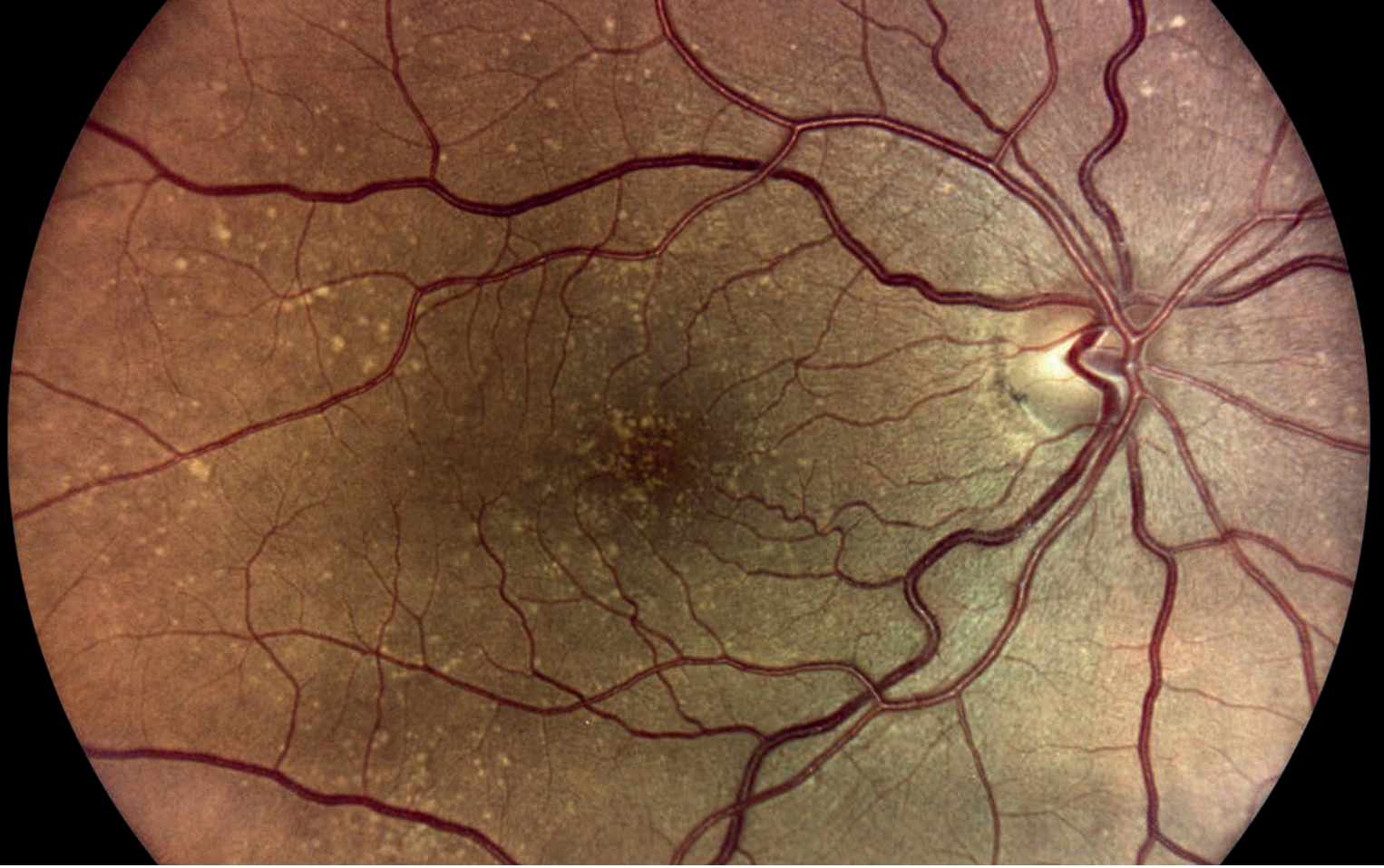This information is intended solely for healthcare professionals located in the UK and EU. Patients should direct questions to their healthcare professional.

**INDICATIONS FOR USE:** The OMNI Surgical System is indicated for the catheterization and transluminal viscodilation of Schlemm's canal and the cutting of trabecular meshwork to reduce intraocular pressure in adult patients with open-angle glaucoma.

For important product information including cautions and adverse events, please refer to the full instructions for use available at [omnisurgical.com/international](http://omnisurgical.com/international)

OMNI and the Sight Sciences logo are registered trademarks of Sight Sciences, Inc.

All other copyrights and trademarks are owned by their respective owners.  
©2024 Sight Sciences, Inc.  
05/2024 OM-3188-OUS.v1



# iCare DRSplus

## Automated TrueColor Confocal imaging



Ultra-High resolution TrueColor confocal imaging, IR and RGB-channels



No dilation, 2.5 mm pupil size



Fast, fully automated image acquisition

ICARE-DRSPPLUS-AD-MM-272-REV01-2024-05

**icare** For better perception

[www.icare-world.com](http://www.icare-world.com)

iCare is a trademark of Icare Finland Oy, Icare Finland Oy, Icare USA, Inc., iCare World Australia Pty Ltd, China iCare Medical Technology Co. Ltd and Centervue S.p.A., are parts of Revenio Group and represent the brand iCare. Centervue S.p.A. is the Legal Manufacturer of DRSplus. iCare DRSplus is a trademark or a registered trademark of Icare Finland Oy in the EU and the USA and/or other countries. Not all products, accessories, services or offers are approved in every market. Approved labelling and instructions may vary from one country to another. This material is intended for healthcare professionals only. © 2024 Icare Finland Oy. All rights reserved.

**CE** 0123





*Practice  
Fundamental  
Retina*

**Retinal seaweed.** A new South Korean study has proposed an innovative method for treating retinal detachment. To replace the vitreous body of the eye, the team behind the study – which included ophthalmologists, chemical engineers, and pathologists – created an artificial hydrogel based on alginate, a viscous carbohydrate naturally occurring in seaweed. They concluded that the artificial substitute could serve as a possible vitreous replacement for real-world retinal detachment care. PMID: 38199216.

**CRISPR for inherited retinal conditions.** Massachusetts Eye and Ear recently released results of an innovative clinical trial, BRILLIANCE, in which researchers demonstrated the efficacy of CRISPR gene editing for treating the inherited retinal degeneration caused by Leber congenital amaurosis (LCA). The technique demonstrated measurable improvements in 11 of 14 trial participants, with the researchers indicating that these promising results “support further research of in vivo CRISPR-Cas9 gene editing to treat inherited retinal degenerations.” PMID: 38709228.

**Adora2a for AMD.** A team of scientists have discovered that Adora2a – a gene related to higher prevalence of coronary lesions – might also correlate with the clinical outcomes of AMD patients. They found that when Adora2a is deleted in the

endothelial cells of mouse models, it can prevent subretinal fibrosis. The scientists now plan to try and develop an antibody for Adora2a in an attempt to block the excessive blood vessel growth found in early-stage AMD, as well as the fibrosis of late-stage AMD. PMID: 38446902.

**P-GAN positives.** Artificial intelligence (AI) can increase the speed of retinal imaging by up to 100 times, according to the latest National Institutes of Health (NIH) research. Employing an AI method known as P-GAN (parallel discriminator generative adversarial network) to adaptive optics optical coherence tomography (AO-OCT), the research team was able to improve both retinal image contrast and the speed of diagnostic imaging times. They hope that this newly developed tool will help specialists better evaluate age-related macular degeneration (AMD). PMID: 38600290.

**Critical flicker.** The rate of visual perception in humans varies widely, according to new evidence found in a study conducted by Trinity College Dublin. To measure this visual perception speed (or “temporal resolution”), researchers used the critical flicker fusion threshold – a measure aimed at determining the maximum frequency someone can determine that a light source is flickering (as opposed to fusing into one constant light source). PMID: 38557652.

**IN OTHER NEWS**

*AMD hallmarks.* A study has found that OCT can be used to determine the outer retinal hallmarks of AMD. The findings present a simplified risk stratification model that could be used to indicate biomarkers associated with predicting outer retina and retinal pigment epithelium (RPE) atrophy growth. PMID: 38471039.

*A coherent understanding.* A new study has emphasized the clinical importance of swept-source optical coherence tomography (SS-OCT) angiography. SS-OCT allows practitioners to better study early indicators of Type II diabetic retinal disease in those patients without clinically observable retinopathy. PMID: 38428559.

*Retinal layer insights.* Researchers have conducted phenotypic and genotypic analysis of retinal thickness in the OCT images of 44,823 UK Biobank participants; they found significant links between retinal thinning and various non-ocular diseases, including neuropsychiatric and pulmonary conditions. PMID: 38266105.





## Gene Editing Primed for Success

### The development and application of prime editing engineered virus-like particles for the treatment of inherited retinal diseases

Mutations in key genes involved in the development or function of the retina result in inherited retinal diseases (IRDs). To date, over 325 genes and genetic loci have been identified as contributors to IRDs, with most of these genes having more than one identified mutation that is causative of disease.

Our ability to identify candidate genes outpaces our ability to develop molecularly targeted treatments for IRDs, and, given the aforementioned numbers of both genes and mutations, it will be a great challenge to develop small molecule therapies for each mutated protein. Thus, researchers must develop new therapeutic approaches for IRDs. This new approach is exemplified by the development of Luxturna (voretigene neparvovec) – the first FDA-approved gene augmentation therapy. Approved for the treatment of LCA, Luxturna was a triumph of translational research, providing proof of concept for gene augmentation therapy and sequencing-informed treatment. However, gene augmentation therapy is less likely to be able to treat diseases that act in a dominant manner, as expression of the wildtype gene may not be able to ameliorate the toxic effects of a dominant negative mutant protein. Another limitation of gene augmentation therapy is its inability to package large transgenes, such as *USH2A*, *MYO7A*, and *ABCA4*, as cargoes in gold standard viral vectors. In light of this, other therapeutic strategies –

such as direct genome editing – need to be considered to address these unmet needs for IRD treatment.

#### Prime editing

First developed in the lab of David Liu at the Broad Institute of MIT and Harvard, prime editing (PE) is a novel third-generation CRISPR/Cas9 gene editor. PE offers many advantages over traditional, nuclease based CRISPR/Cas9 strategies. In (relatively) simple terms, the process uses at least one prime editing guide RNA (pegRNA) to target a partially inactivated Cas9 protein to a defined location in the genome where a single-stranded DNA break is made. Next, a reverse transcriptase, which is fused to Cas9, installs an intended edit templated by the pegRNA by reverse transcribing the template into DNA, which is then incorporated into the genome. The mechanism of PE enables the correction of all 12 types of point mutations, as well as the reversion of small insertions and deletions.

#### Prime editor engineered virus-like particles

A major challenge in the application of PE and other genome editors is the need to safely and efficiently deliver genome editing components. The use of viral vectors, such as adeno-associated viruses and lentiviruses, come with significant drawbacks. When CRISPR/Cas9 components are expressed over a sustained period – such as from a cell that has been transduced by a virus – there

is an increased risk of unintended off-target and bystander editing outcomes. There is also a low risk of viral genome insertion into the genome, either in a random (and potentially oncogenic location) or into the nicked DNA strand. An ideal genome editing delivery platform should deliver CRISPR/Cas9, PE, and guide RNA components transiently, thereby limiting risks.

Our previous research demonstrated that engineering the Moloney murine leukemia retrovirus structure enables the packaging of base editor protein and guide RNA without an associated viral genome. This results in an engineered virus-like particle (eVLP), which has a high cargo capacity, a modifiable tissue/cell-type tropism, and transient delivery of genome editors without risk of genome integration. We showed that subretinal delivery of base editor eVLPs in vivo corrected a mutation in rd12 mice; these mice carry a natural nonsense mutation in Rpe65 – an enzyme expressed in the retinal pigment epithelium (RPE) that is critical for the retinoid visual cycle, and the same enzyme that is replaced by Luxturna. The editing also resulted in protein rescue and substantial physiology rescue of the electroretinography (ERG) response, indicating partial restoration of visual function.

However, the base editor eVLP architecture did not support efficient PE in vitro. To improve editing efficiency, we engineered and optimized several components of the eVLPs, including



Samuel W. Du

optimization of nuclear export and import signals, engineering the protease release site, and improving recruitment and packaging of both PE protein and pegRNAs. This led to two high-efficiency and complementary architectures: the PE v3- and PE v3b-eVLPs.

We chose two mouse models of IRDs to test the in vivo editing capability of these PE-eVLPs. Once again, we corrected the rd12 mouse model of Rpe65 and observed efficient RPE editing and physiological rescue. We also investigated the use of PE-eVLPs in the rd6 model of Mfrp, where mutations are associated with RP. This naturally occurring mouse line has a four base pair deletion in an mRNA splicing site, leading to aberrant mRNA splicing and no expression of MFRP protein. This deletion mutation is uncorrectable by base editing and provides a powerful proof-of-

concept for IRD-causing insertion and deletion mutations. Again, we observed efficient editing in the RPE and restoration of wildtype MFRP protein. Importantly, for both genes and mouse models, we did not detect any off-target editing in the top ten sites we determined by CIRCLE-seq to be most susceptible to off-target editing in the RPE of animals treated with PE-eVLPs. This further supports the safety of transient PE-eVLP delivery for the treatment of IRDs.

#### The future of IRD treatment

Genetic medicine is poised to become an exciting treatment modality for IRDs. With further advances in PE and PE-eVLPs, we can envision the successful correction of almost all disease-causing mutations that lead to LCA, RP, and other IRDs. Though more careful study

of the immunogenicity and off-target editing effects of PE-eVLPs need to be explored, prime editors will soon enter clinical trials, as Prime Medicine recently announced in a press release last year.

In our work, we demonstrated efficient in vivo editing of the RPE. A major unmet goal for the development of PE-eVLPs will involve the targeting of PE-eVLPs to rod and cone photoreceptors, which we did not investigate in this study, but constitute a major therapeutic target for IRD research. Nevertheless, as more disease-causing genes and mutations are discovered by sequencing of affected patients, researchers can design precision medicine PE therapies to correct these mutations and restore sight.

*Samuel W. Du is an MD/PhD candidate in the lab of Krzysztof Palczewski at the University of California, Irvine.*

# Worth a closer look

Precision solutions for laser eye surgery

**SCHWIND**  
eye-tech-solutions



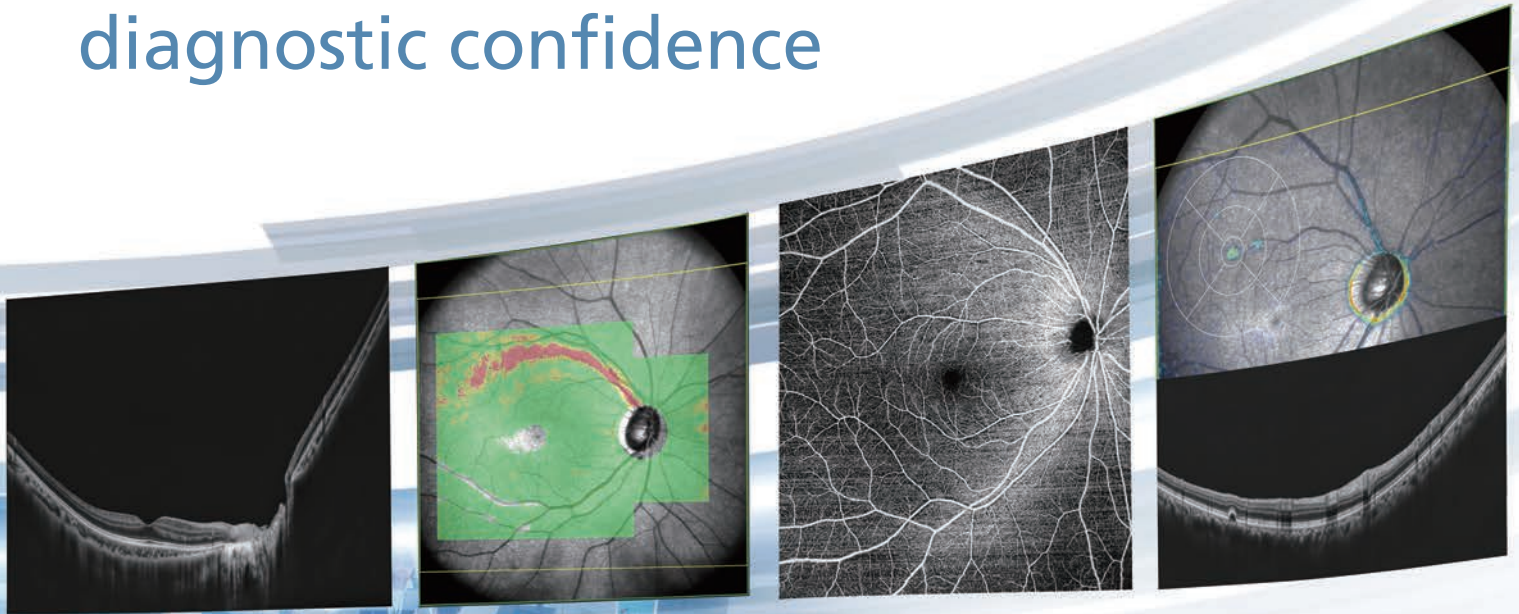SCHWIND has been driving the development of corneal surgery for over 30 years. Today the company offers doctors and their patients a comprehensive portfolio of eye laser correction solutions, with the SCHWIND ATOS femtosecond laser and the SCHWIND AMARIS excimer laser – including SmartSight lenticular extraction, touchless SmartSurfACE treatment, intrastomal SmartLASIK and PresbyMAX.

The seamlessly linked high-performance SCHWIND MS-39, SCHWIND SIRIUS+ and SCHWIND PERAMIS diagnostic systems provide impressive depth of detail for treatment decisions, whether with corneal and ocular wavefront data, pachymetry or OCT-based epithelium data.

# Optical Coherence Tomography RS-1 Glauvas

New

## Faster workflow without compromising diagnostic confidence



250kHz

250,000 A-scans/s  
high-speed imaging



Effortless operation  
and interpretation



Wide, deep, high-  
resolution imaging



Advanced analytics







## Practice Fundamental Anterior Segment

**Event horizon.** A new report has investigated how UV radiation displays used in outdoors events might be linked to photokeratitis. The report looked at a case study of eight participants who had all attended the same event, all presenting with photokeratitis symptoms around approximately nine hours after exposure to the UV lights. The report found that, though there was no anterior chamber reaction in these patients, all eight experienced eye pain and were affected bilaterally. PMID: 38696206.

**Electroretinography developments.** Japanese scientists have created a new multi-electrode device that can measure the electrical potentials of the retina at different points simultaneously, without the need for placement of hard contact lenses. Wrapping gold mesh electrodes around a commercially available soft disposable contact lens soaked in monomer 3,4-ethylenedioxythiophene (EDOT) solution, the team were able to develop a flexible, highly transparent system for taking ERG measurements that fits a patient much like an ordinary disposable contact lens. DOI:10.1002/admt.202400075

**FAF or faff?** Scientists have drafted up a report on how fundus autofluorescence (FAF) – a non-invasive but relatively underused imaging technique – can be used to help both diagnose and monitor two different types of uveitis. The researchers report that FAF, which detects pathological abnormalities in the choroid and retina, could

be used to provide doctors with information on levels of inflammation caused by both posterior uveitis and panuveitis, as well as – thanks to how the fluorophores are distributed – determine the underlying form of uveitis in the patient. PMID: 38785922.

**Uveal melanoma therapy.** A new Nature study reveals that metastatic uveal melanoma – previously considered resistant to immunotherapy – can potentially be treated using “tumor-infiltrating lymphocyte (TIL)” therapy. However, TIL therapy does not work on all uveal melanoma patients. In response, the researchers developed a clinical tool – the Uveal Melanoma Immunogenic Score (UMIS), which takes a holistic measure of the tumor microenvironment. Individuals with higher UMIS scores were more likely to experience better tumor regression with TIL therapy than those with lower scores, indicating that UMIS could act as an effective biomarker for patient selection. PMID: 38627362.

**Smart predictions.** A new research paper has introduced a smart wireless measuring contact lens (WMCL) that can accurately measure intraocular pressure (IOP), even when internal temperature variations exceed 10 °C. The Beijing-based research team posit that this technology – with its accuracy and sensitivity for IOP monitoring in porcine eye in vitro – could present a viable method for accurate early detection and monitoring of glaucoma in the future. PMID: 38651323.

### IN OTHER NEWS

*Patching positives.* Eye patching (or “occlusion therapy”) in children with unilateral congenital cataracts (UCC) causes no negative impact on a child’s development or on family stress levels, according to a new study. PMID: 38635258

*Vape gets in your eyes.* A new systematic review has indicated that vaping can have a negative impact on the ocular surface. The study looked at both intended (vaping) and non-intended (explosions or damaged products) exposures to electronic cigarette components, concluding that the “impact of vaping on the ocular surface is not benign.” PMID: 38731149.

*Lens solution.* Previous research has suggested that pre-existing contact lens disinfectants are ineffective when it comes to preventing biofilm, but a new study appears to have come up with a solution (pardon the pun). Hydroquinone – the organic compound found in tree bark and effective in malaria prevention – could also prevent microbial keratitis. PMID: 38247615.

## Rehabilitating Vision After Keratoconus

### TransPRK, PACE, and All Femto CAIRS as surgical options for keratoconus

What is the current state of the art for rehabilitating the vision of patients with keratoconus? That's one of the questions we are most frequently asked, and the answer is always, "It depends." There is certainly a spectrum of options, but the best one depends on the individual patient's cornea. Patients with complex corneal pathologies, such as failed refractive surgeries and highly advanced corneal ectasias, are often referred to our clinic – the ELZA Institute in Zurich, Switzerland – and we have decades of experience in managing such cases. Here, we share what we have learned over the years.

#### Quality versus acuity

With keratoconus, there can be a big difference between visual acuity – what a patient can read on a chart – and visual quality (see Figure 1). Early on in the development of a cone, patients not only develop increasing amounts of ametropia, but also regular and – crucially – irregular astigmatism, which causes the biggest problems.

Cone development creates irregular astigmatism because the distortion of the corneal shape increasingly creates irregular surfaces of the anterior and posterior cornea, and this manifests as the hallmark higher-order aberration (HOA) visual disturbances that keratoconus is famous for causing. Irregular astigmatism cannot be corrected by spectacles or regular contact lenses alone.

#### Surgical intervention

If a patient has a mild, stable keratoconus

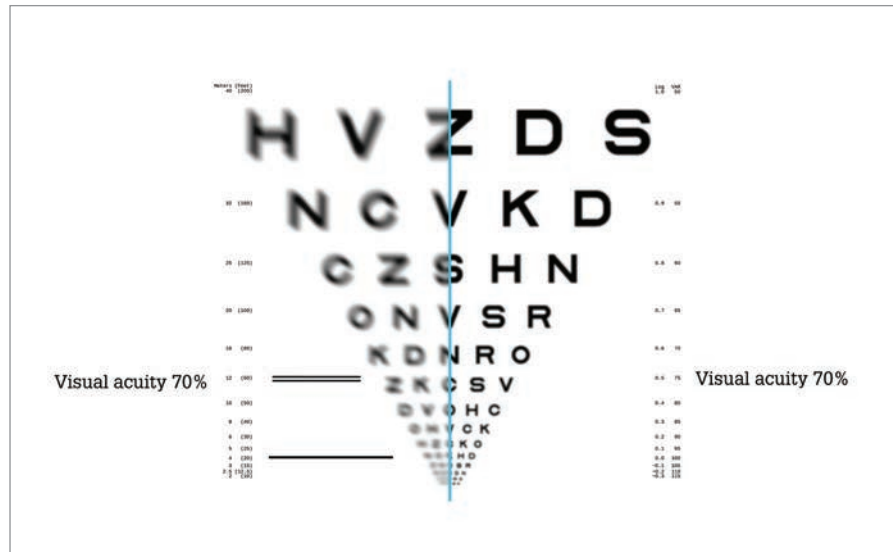


Figure 1. The difference between visual acuity and visual quality. In both images, the patient has the same visual acuity, but different visual qualities – and it is the degradation of the latter that causes so much of the visual disability in patients with corneal ectasias.

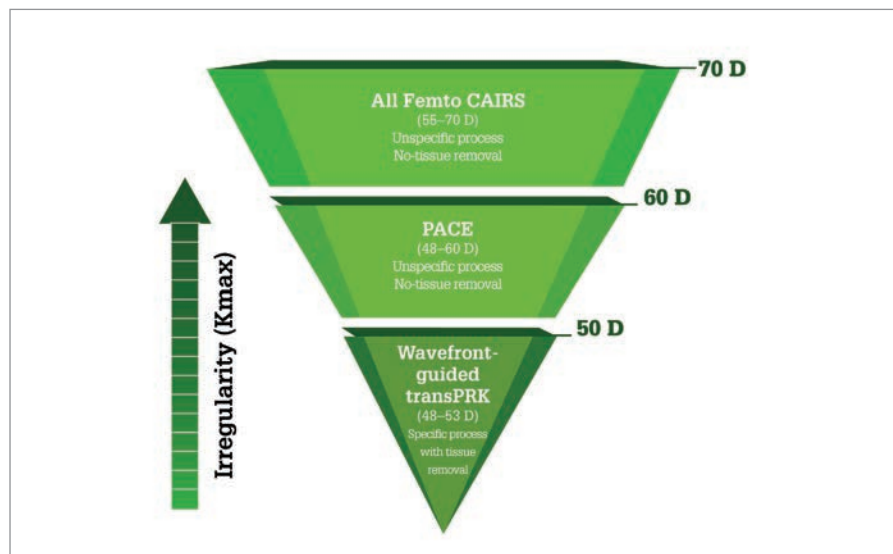


Figure 2. The ELZA pathway for ectatic cornea rehabilitation surgery. There are several surgical options available today, and in isolation, or combination, can be used to improve the regularity of the cornea, and the visual quality too.

with satisfactory daytime vision with spectacles, the best course may be to take no action until the condition changes. If progression does occur, then corneal cross-linking (CXL) should be performed to halt further deterioration.

If surgery is necessary, there are several options available, and these can be used in isolation or in combination to rehabilitate vision as much as possible (see Figure 2). Typically, where we start

on this journey depends on the amount of corneal irregularity present in the cornea. If there is a significant amount, we start with a less-specific process to help flatten the cone; if required, we follow this with more targeted approaches to further improve vision.

#### Ring segments

Intracorneal ring segments (ICRS) is the surgical intervention that typically delivers

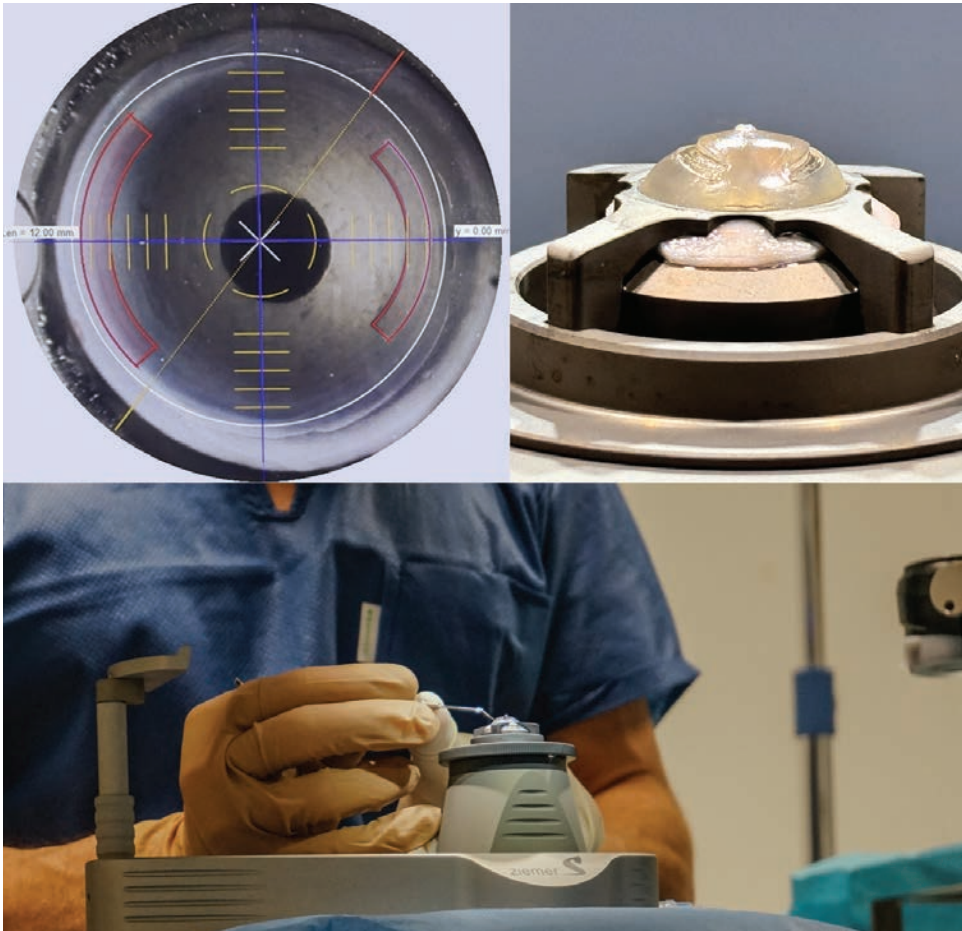


Figure 3. Creation of the All Femto-CAIRS ring segments from the donor cornea.

the greatest corneal regularization effect. ICRS, which have been available for over 20 years, are crescent-shaped devices made from polymethylmethacrylate (PMMA); they are implanted into crescent-shaped pockets made in the stroma (either by a blade or a femtosecond laser). Once implanted, the presence of the ring segments raises the cornea and causes the corneal curvature over the cone to flatten. This not only helps to redistribute biomechanical forces away from the cone region, but also to regularize the shape of the cornea, all without removing tissue. ICRS can also be removed at a later date; in other words, the procedure is reversible.

The corneal reshaping induced by the ICRS acts to reduce corneal irregularities

and enhance patients' quality of vision. The only disadvantage with ICRS is that, in some cases, the rigid nature of the ring can result in ring migration or extrusion – and there is a very small risk of corneal infection or neovascularization.

So, how can this be improved? By making the rings from corneal tissue...

#### CAIRS and All Femto CAIRS

The brainchild of ophthalmologist Soosan Jacob, CAIRS – corneal [allogeneic] intrastromal ring segments – involves the creation of ring segments from human donor corneas. With CAIRs, the tissue inserted into the pocket (essentially collagen, rather than rigid PMMA) should have a lower risk of

migration or extrusion. Cornea, cataract, and refractive surgeon Shady Awwad worked with Soosan to further enhance CAIRS to make it a fully femtosecond laser-based procedure, called All Femto CAIRS.

With ICRS, the most appropriate ring length is chosen from the manufacturer's selection; it is then inserted into the appropriately placed pocket. With All Femto CAIRS, the surgeon can specify the exact dimensions of the corneal ring segment, as well as the placement of a femtosecond-laser created tunnel in the stroma (see Figure 3). This makes the procedure as customizable to each patient's cornea as it possibly can be. Awwad observes that “the allogeneic nature of the rings means that we can place the rings in pockets that are shallower in the stroma, and this amplifies the reshaping effect, compared with PMMA rings placed in deeper pockets,” suggesting that CAIRS procedures have more potential to regularize corneal shape than ICRS. This year, the ELZA Institute became the first center in Switzerland to offer All Femto CAIRS. Our experience with it – and that of our patients – has been entirely positive to date.

#### PACE

If a cornea requires cross-linking, an excellent option in many cases is PACE (PTK-assisted customized epi-on CXL), which we described in a recent issue of *The Ophthalmologist*. PACE is a second-generation customized CXL method that uses a phototherapeutic keratectomy (PTK) ablation to remove the corneal epithelium above the cone (but no stromal tissue), which is then followed by a short, high-fluence partial epi-on/epi-off cross-linking procedure. The cross-linking effect is greatest over the cone – also the region that requires strengthening – and less in more peripheral regions. This is because PACE produces a riboflavin gradient (greatest over the epi-off cone region, lower in regions where it is required to penetrate the remaining epithelium), as well as a UV gradient



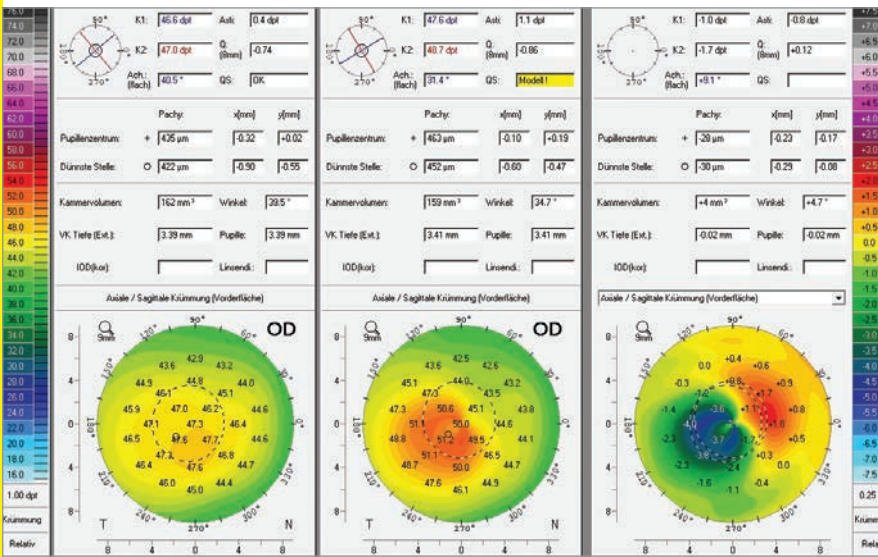


Figure 4. The effect of PACE on corneal topography, before and 5 minutes after the procedure.

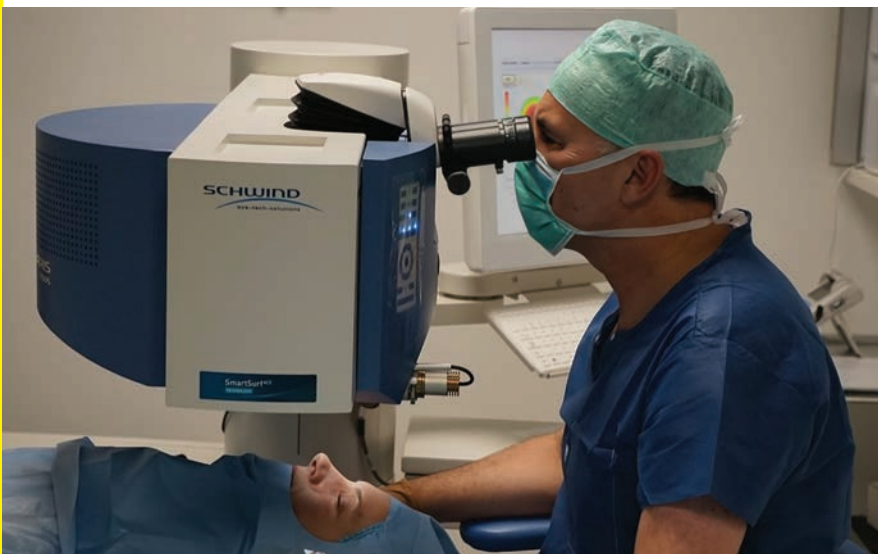

Figure 5. Wavefront-guided TransPRK being performed.

(epithelial cells absorb UV energy) and an oxygen gradient (epithelial cells consume oxygen, which is required to diffuse into the stroma and oxygen is rate-limiting for the UV-riboflavin photochemical reaction that strengthens the cornea). This results in a significant immediate flattening of the cone and regularization of the cornea (see Figure 4). Over six months to a year, the method leads to around 8–12 diopters of total flattening. If a further flattening effect is required on the cornea, PACE can be performed after All Femto CAIRS.

In suitable corneas, either procedure (in isolation, or in combination) can be followed by therapeutic PRK surgery if necessary.

**Wavefront-guided transPRK (surface ablation)**

Once a cone is cross-linked, the cornea may flatten slightly – up to 1 diopter – over the next six months. For corneas with sufficient biomechanical strength and residual tissue after CXL, wavefront-guided photorefractive keratectomy (PRK) surface ablation with an excimer laser can be

considered (see Figure 5). This technique, primarily aimed at corneal regularization rather than refractive correction, can significantly reduce HOAs. Our excimer laser platform, the SCHWIND Amaris, has a built-in wavefront-guided ablation algorithm that can specifically address and reduce the HOAs in irregular corneas. It is a precise process, suitable for corneas up to a general limit of 52 or 53 diopters, and can significantly enhance visual quality by addressing irregular astigmatism.

**Patient-centric care**

As we have shown, there are several options available for rehabilitating the vision of people with keratoconus. But combining them can yield better results than using the techniques in isolation. The “best” approach? Well, that is specific to each and every eye, and selection should be driven by the topography, tomography, pachymetry, and biomechanics of the cornea, as well as, of course, the experience of the surgeon and the wishes of the patient.

Ultimately, whether the treatment is surgical or non-surgical (for example, special contact lenses), it’s important for patients to know that – no matter how bad their vision is with keratoconus – there is hope.

*Farhad Hafezi is a Professor of Ophthalmology at the University of Geneva, Switzerland; Research Group Leader at the CABMM of the University of Zurich, Switzerland; Chief Medical Officer of the ELZA Institute, Zurich, Switzerland; Adjunct Clinical Professor of Ophthalmology at the USC Roski Eye Institute, Los Angeles, USA; Research Professor at the NYU Grossman School of Medicine, New York, and Visiting Professor at the Wenzhou Medical University, Wenzhou, China.*

*Emilio de Almeida Torres-Netto is a cornea, cataract and refractive surgeon at the ELZA Institute, Zurich.*

## Quest for the Ideal Bleb

**Why Santen's PRESERFLO MicroShunt could mean "fewer sleepless nights for glaucoma surgeons"**

To avoid blebitis risks and any possible leakage, glaucoma surgeons tend to aim for posterior, diffuse-filtering blebs in primary open-angle glaucoma (POAG) treatment – a goal usually achieved through trabeculectomy. However, though trabeculectomy is generally considered to be an effective procedure, bleb morphology can vary considerably and the postoperative course can be somewhat unpredictable. Furthermore, potential serious risks such as hypotony, shallow AC, choroidal detachment, hyphema, and decompression retinopathy can still occur in a small number of patients (1).

The PRESERFLO MicroShunt – performed using an ab-externo approach, with the patient under at least topical anesthesia – is an innovative, minimally invasive bleb-filtering device that allows surgeons to perform controlled (and thus more predictable) intraocular pressure (IOP) lowering and subconjunctival drainage of aqueous

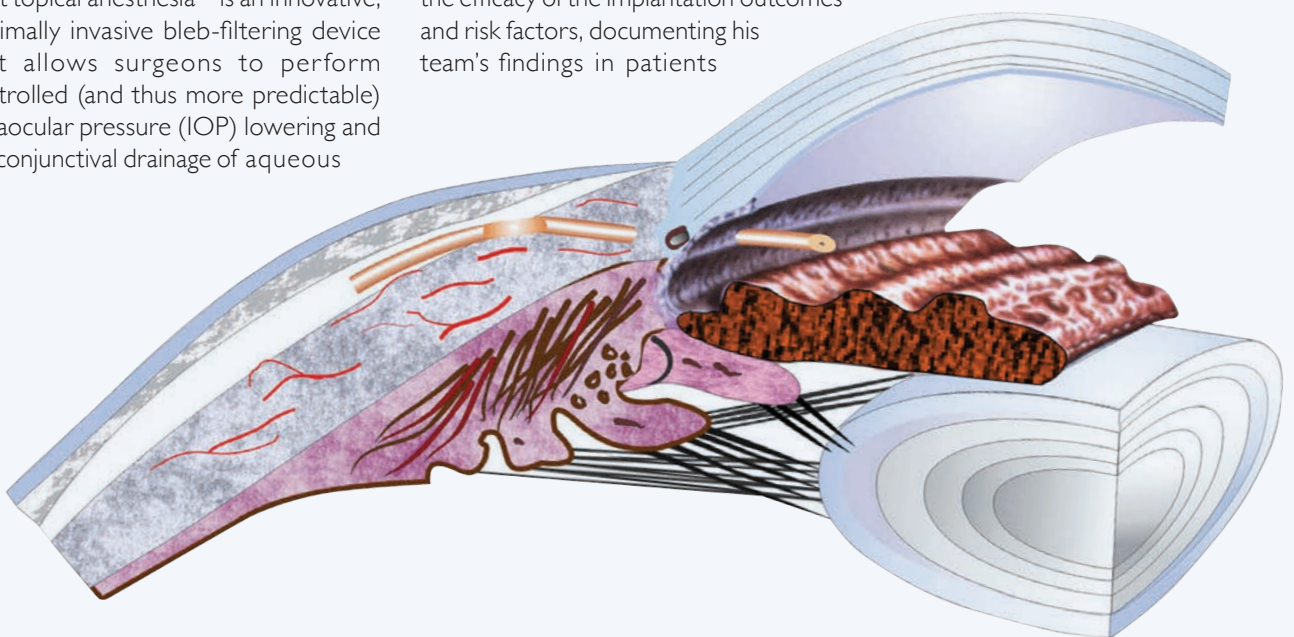
humor, increasing their chances of achieving ideal bleb morphology. Built from poly(styrene-block-isobutyleneblock-styrene), or "SIBS," the device is a 100 percent synthetic, biocompatible material first employed for coronary stents in 2002 and features an 8.5-mm tube with an outer diameter of 350  $\mu\text{m}$  and 67- $\mu\text{m}$  diameter lumen. This diameter is ideal for preventing both clogging and chronic hypotony. Additionally, the biocompatible and biostable SIBS components have been found to produce minimal scar tissue formation (2), leaving no biodegradation byproducts, positioning the PRESERFLO MicroShunt as a predictable, controlled and safe alternative to trabeculectomy when operating on POAG patients.

The view from the top

The PRESERFLO MicroShunt's unique set of features have drawn leading industry names – such as MIGS trailblazer, all-round surgical innovator, and our number one Power Lister, Ike Ahmed – to participate in clinical evaluations of the device. Since 2015, Ahmed has been conducting follow-up studies examining the efficacy of the implantation outcomes and risk factors, documenting his team's findings in patients

*"The PRESERFLO MicroShunt's unique set of features have drawn leading industry names like Ike Ahmed to participate in clinical evaluations of the device."*

over one-year (3) and three-year (4) periods. These studies have "[guided] us in what to expect with the results of this procedure in a wide range of patients and settings," says Ahmed. "We had a high degree of follow-up, which is important." In retrospective studies, patients can get



lost in follow-up and the data remains incomplete, Ahmed explains, but in his PRESERFLO MicroShunt studies “around 90 percent of patients had follow-up after one year, which is very good, and we were able to really look into those patients.”

The two studies showed promising results for the device's efficacy. Initially, the one-year follow-up data – taken from a large and diverse cohort of 436 glaucoma patients who underwent ab-externo SIBS surgery with Mitomycin C (with or without previous subconjunctival surgery) – indicated “promising rates of qualified and complete surgical success with decreased medication burden and few postoperative complications and interventions” (3). The three-year follow-up study built on these promising rates, with the authors encouraging

further comparisons to other filtering surgeries be made to “further facilitate integration of the SIBS microshunt into the surgical treatment paradigm” (4).

The study results show comparable low IOPs within the same range achieved by trabeculectomy. Ahmed says, “Although we did not do any head-to-head comparisons, we had substantial pressure lowering – IOPs that were typically down to 12, to the low teens – and we had success rates that were fairly consistent with what we saw in other studies looking at trabeculectomy. We felt these results showed a significant IOP drop coinciding with medication reduction.” Ahmed believes that these trials also point to the safety of the procedure: “The results for PRESERFLO demonstrate a fairly good adverse event profile.”

#### Tips and tricks

A key factor in the IOP-lowering success of the implant is when it's used in conjunction with chemotherapeutic agent, Mitomycin C. “Based on our Cox analysis, patients who received a higher dose of Mitomycin C were found to have a higher success rate,” notes Ahmed. “We started off at 0.2 mg/ml MMC, then moved to 0.4 mg/ml MMC [in] a time-interrupted fashion. So, we feel we have a reasonable data set to also confirm the benefit of using Mitomycin C at higher doses, without really increasing the risk of patient complications.”

Alongside selecting the most effective device for the type of surgery being performed, there are also various critical surgical factors involved in reliably reaching low IOP. “We've been very meticulous about how we handle the Tenon's capsule,” explains Ahmed. “Because bleb formation with this device occurs in the sub-tenon space, and, because this is a single lumen device, placement of the device so that it doesn't get trapped under Tenon's is really important.” The Tenon's capsule also

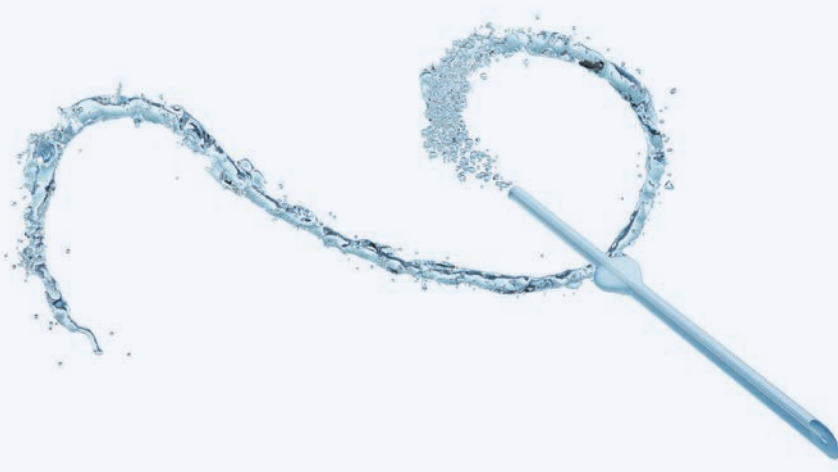needs to be managed atraumatically. “We take great caution during the opening and dissection, being careful not to adulterate the Tenon's with any kind of injection or trauma,” Ahmed continues. “And when we close, we [suture the] Tenon's in a two-layer closure – meaning that we close the Tenon's first and then the conjunctiva – to really ensure adequate positioning.”

The physiological placement of the device is crucial; the surgeon should ensure it is placed away from the cornea and not kinked, where it might get either blocked or else reduce the lumen size. Additionally, says Ahmed, the device should be placed in the superior quadrant, rather than at 12 o'clock, to encourage posterior bleb formation and provide ideal morphology. Of course, surgery can be an unpredictable endeavor at the best of times. “There are some patients that still get hypotony, so we need to understand why they do,” he says. “There might be some device differences, patient differences, healing differences, technique differences... We're seeing people using rip cord sutures in the lumen to protect from hypotony – so it's about understanding whether this is necessary. We don't do it routinely; we do it for high-risk patients who are at risk of hypotony.”

Ahmed believes the number one benefit of the PRESERFLO MicroShunt is the controlled pressure drop and flow that the device offers, which helps reduce the risk of hypotony complications and provides a smooth postoperative course for the majority of patients. He adds that the device “also achieves substantial pressure lowering – probably some of the most powerful pressure lowering of our new devices – in a way that's done with minimal postoperative intervention, with reduced needling rates compared to other procedures, and also bleb morphology being optimal, meaning again that posterior diffuse bleb, which is ideal.”

*“The physiological placement of the device is crucial; the surgeon should ensure it is placed away from the cornea and not kinked, where it might get either blocked or else reduce the lumen size.”*





#### Which patients?

For ophthalmologists choosing to use the PRESERFLO MicroShunt for the first time, Ahmed lists a number of considerations one should bear in mind. First is patient selection – “making sure we have healthy conjunctiva in the area of surgery, and that we have a good open angle to place a device deep in the anterior chamber to protect the cornea.”

In terms of pressure targets, he adds that while the PRESERFLO MicroShunt typically results in pressures down to 12, if patients do require a more substantial drop to “six or seven or eight mmHg”, he would recommend still performing a trabeculectomy to reach these numbers, adding, “but otherwise, if we want to get the pressure down typically into the low teens, and most patients are on no medications, then that’s where the sweet spot is.” Plus, “post-op bleb management is of course crucial to overall patient outcome,” he adds, reminding us that sometimes patients will still need to have a post-operative 5-FU, and that ample steroids should also be used for the healing process.

Ahmed is optimistic about how the PRESERFLO MicroShunt might further evolve in clinical practice, especially

when surgeons remain focused on accurate patient selection. It’s important to understand the right patient profile, he explains. “For example, we looked at primary standalone procedures compared to combined procedures with phaco, and we looked at refractory patients who have had previous surgery, and we found the highest success rates were in patients who have had standalone primary surgery.”

He also suggests that, moving forward, this patient population should be expanded into pediatrics, as well as older patients. “There is a learning curve, both with patients and surgeons who are learning this procedure,” he says. “Hopefully the pearls I’ve covered here will shorten that learning curve. Around the world, we’re seeing fairly good adoption – with surgeons using the device we’re finding fewer postoperative visits, less variation in pressure, faster visual recovery, which is important for return to function – and overall good experience.” All of which, Ahmed believes, will hopefully lead to “fewer sleepless nights for glaucoma surgeons.”

The PRESERFLO MicroShunt offers surgeons a range of benefits not previously seen in minimally invasive

devices designed to lower IOP for glaucoma and reduce the need for further medication. Using the device, surgeons may find that they are able to fully optimize their outcomes, increasing their surgical success rates, and provide their carefully selected patient cohort with the utmost level of care.

#### References

1. B Ramona et al., “Intraoperative and postoperative complications in trabeculectomy,” *Rom J Ophthalmol*, 59, 243 (2015). PMID: 29450314.
2. AC Acosta et al., “A newly designed drainage implant made of poly(styrene-block-isobutylene-block-styrene): biocompatibility and function in normal rabbit eyes,” *Arch Ophthalmol*, 124, 1742 (2006). PMID: 17159034.
3. I Ahmed et al., “All Consecutive Ab Externo SIBS Microshunt Implantations With Mitomycin C: One-Year Outcomes and Risk Factors for Failure,” *Am J Ophthalmol*, 255, 125 (2023). PMID: 37352909.
4. “Ab Externo SIBS Microshunt with Mitomycin C for Open-Angle Glaucoma: Three-Year Results as a Primary Surgical Intervention,” *Ophthalmol Glaucoma*, 6, 480 (2023). PMID: 37044278.

*Santen does not endorse off-label use of PRESERFLO® MicroShunt. Long term effects of MMC with the use of this device have not been evaluated. Necessary precautions and interventions on the use of MMC are highly recommended.*

*The PRESERFLO® MicroShunt glaucoma drainage system is intended for reduction of intraocular pressure in eyes of patients with primary open-angle glaucoma where IOP remains uncontrollable while on maximum tolerated medical therapy and/or where glaucoma progression warrants surgery. Please read the PRESERFLO® MicroShunt Instructions for Use carefully and complete the relevant training before using the device.*


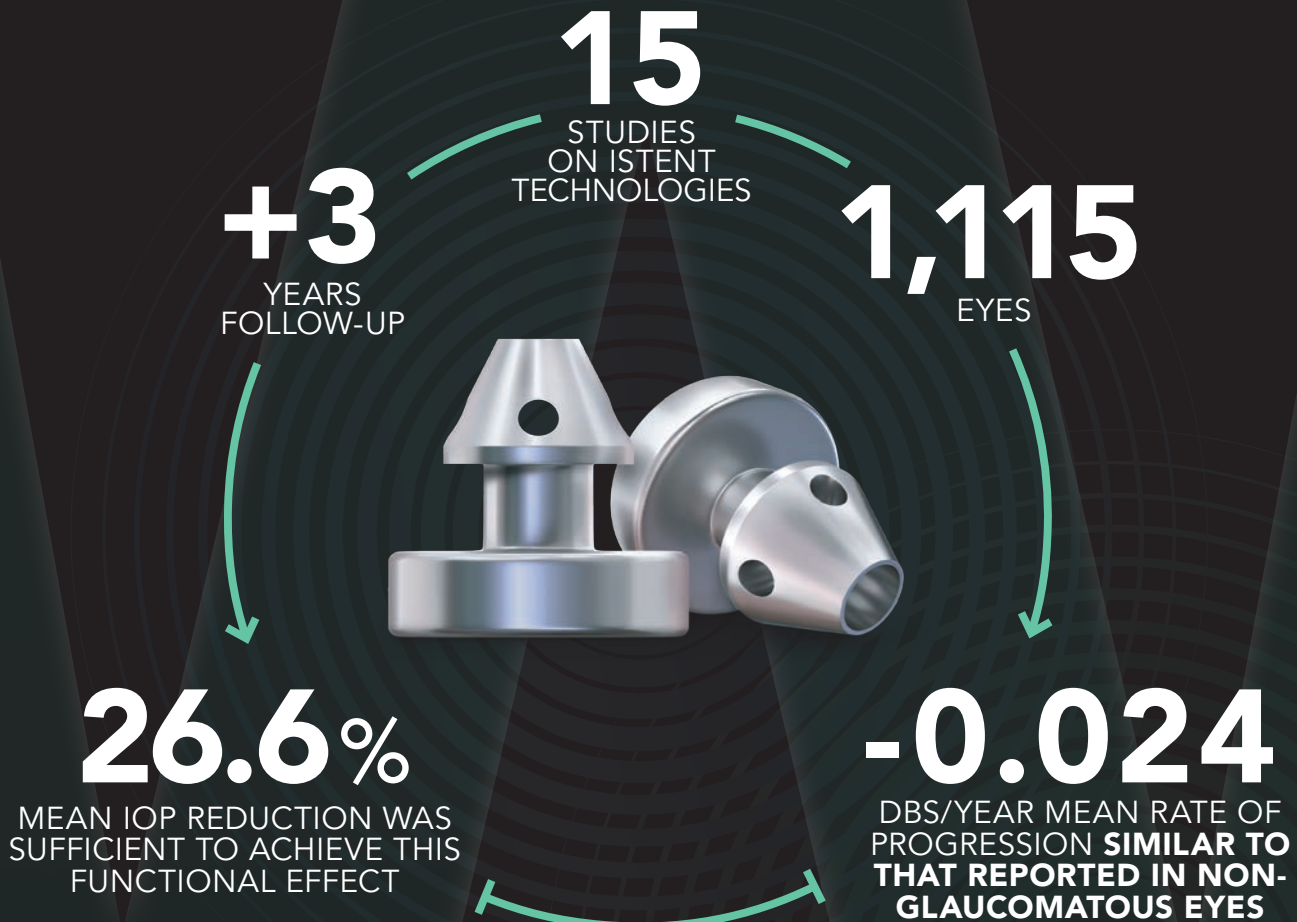


iStent  
inject® w

# STOP!

## Glaucoma Disease Progression

iStent® technologies have been proven to **stabilize visual fields loss and glaucoma disease progression** with a favourable risk-benefit ratio<sup>1</sup>



**INTERVENE EARLIER WITH ISTENT INJECT® W**  
TO PRESERVE PATIENTS' FUNCTIONAL VISION AND QUALITY OF LIFE

1. Gillmann K, Hombeak DM. *BMJ Open Ophthalmol* 2024;9:e001575. doi:10.1136/bmjophth-2023-001575.

**iStent inject® W IMPORTANT SAFETY INFORMATION**

**INDICATION FOR USE:** The iStent inject® W is intended to reduce intraocular pressure safely and effectively in patients diagnosed with primary open-angle glaucoma, pseudo-exfoliative glaucoma or pigmentary glaucoma. The iStent inject® W can deliver two (2) stents on a single pass, through a single incision. The implant is designed to stent open a passage through the trabecular meshwork to allow for an increase in the facility of outflow and a subsequent reduction in intraocular pressure. The device is safe and effective when implanted in combination with cataract surgery in those subjects who require intraocular pressure reduction and/or would benefit from glaucoma medication reduction. The device may also be implanted in patients who continue to have elevated intraocular pressure despite prior treatment with glaucoma medications and conventional glaucoma surgery. **CONTRAINDICATIONS:** The iStent inject® W System is contraindicated under the following circumstances or conditions: • In eyes with primary angle closure glaucoma, or secondary angle-closure glaucoma, including neovascular glaucoma, because the device would not be expected to work in such situations. • In patients with retrolental tumor, thyroid eye disease, Sturge-Weber Syndrome or any other type of condition that may cause elevated episcleral venous pressure. **WARNINGS/PRECAUTIONS:** • For prescription use only. • This device has not been studied in patients with uveitic glaucoma. • Do not use the device if the iStent inject® lid has been opened or the packaging appears damaged. In such cases, the sterility of the device may be compromised. • Due to the sharpness of certain injector components (i.e. the insertion sleeve and trocar), care should be exercised to grasp the injector body. Dispose of device in a sharps container. • iStent inject® W is MR-Conditional; see MRI Information below. • Physician training is required prior to use of the iStent inject® W System. • Do not re-use the stent(s) or injector, as this may result in infection and/or intraocular inflammation, as well as occurrence of potential postoperative adverse events as shown below under "Potential Complications." • There are no known compatibility issues with the iStent inject® W and other intraoperative devices. (e.g., viscoelastics) or glaucoma medications. • Unused product & packaging may be disposed of in accordance with facility procedures. Implanted medical devices and contaminated products must be disposed of as medical waste. • The surgeon should monitor the patient postoperatively for proper maintenance of intraocular pressure. If intraocular pressure is not adequately maintained after surgery, the surgeon should consider an appropriate treatment regimen to reduce intraocular pressure. • Patients should be informed that placement of the stents, without concomitant cataract surgery in phakic patients, can enhance the formation or progression of cataract. **ADVERSE EVENTS:** Please refer to Directions For Use for additional adverse event information. **CAUTION:** Please reference the Directions For Use labelling for a complete list of contraindications, warnings and adverse events.

© 2024 Glaukos Corporation. Glaukos, iStent®, iStent inject® and iStent inject® W are registered trademarks of Glaukos Corporation. PM-EU-0294





## Practice Fundamental Glaucoma

**Going with the (glaucoma) flow.** To more accurately determine the stages of glaucoma in patients, a team of scientists from Genoa, Italy, have developed an easily reproducible method to analyze swept-source OCT-A images. The quantitative method uses variation analysis of the OCT-A images – with black pixels representing no flow, white pixels representing high flow, and gray pixels representing intermediate flow levels – to identify the various blood flow patterns in the macular and optic nerve that are characteristic of glaucoma. The team hopes that their novel technique could also provide new parameters for diagnosing glaucomatous damage. PMID: 38615097.

**Trabeculotomy and QoL.** Is quality of life (QoL) negatively impacted after a trabeculotomy? A team of researchers based at Copenhagen University Hospital sought to answer this question by surveying 58 glaucoma patients before and 12 months after the procedure. Assessing factors such as the number of glaucoma medications taken, intraocular pressure (IOP), and visual acuity, they found that patients' QoL generally remained consistent before and after trabeculotomy. They believe these results highlight the procedure's "stabilizing effect on both objective and subjective visual function," as well as helping clinicians to better understand

the issues patients can face post-trabeculotomy. PMID: 38655879.

**Predictors of glaucoma medication adherence.** Examining the long-term patterns of glaucoma medication adherence in Danish patients, a BMJ Open Ophthalmology study has found that the first two years of a regime can be a crucial period for determining the patient's future adherence. Additionally, the register-based study – which looked at over 30,000 glaucoma patients over a ten-year period between 2000 and 2018 – found that increased age, a low comorbidity score, and being female were also associated with better adherence rates. PMID: 38626933.

**Foreseeing the (glaucoma) future.** Exploring the temporal relationship in retinal nerve fiber layer thickness (RNFLT) alterations, blood flow changes, and mean deviation (MD) changes in glaucoma patients, researchers of an IOVS study employed structural equation models (SEMs) on data from 345 eyes of 174. Specifically trying to understand if previously measured parameters gathered from a hospital visit could predict the rates of another given parameter after six months, the team concluded that MD changes can be used to help predict both blood flow changes and RNFLT alterations in glaucoma. PMID: 38564193.

### IN OTHER NEWS

*Phacoemulsification wins the POAG bout.* Authors of a new Clinical Ophthalmology study have determined that phacoemulsification is better at treating primary angle closure glaucoma (POAG) than using laser peripheral iridotomy (LPI). PMID: 38596663.

*UKEGS Research Award 2024.* Glaucoma UK has announced the launch of its United Kingdom & Eire Glaucoma Society (UKEGS) Research Award, which offers up to £50,000 to innovative glaucoma research projects looking to make a positive impact in the field. The closing date for submissions is August 1, 2024.

*Retinal thinning in Parkinson's.* A new study has used OCT data to examine whether any retinal changes could be observed in "treatment-naïve" Parkinson's disease (PD) patients. The researchers found that PD patients showed a significantly reduced retinal thickness when compared with healthy controls, differentiating it from the lesser retinal thinning caused by POAG. PMID: 38517802.



## AI-Powered Glaucoma Risk Stratification

### Using deep language models (DLMs) to identify the eyes most likely to need surgical intervention

How can we improve early risk stratification in glaucoma? While there are a number of viable answers to this question, I see deep language models (DLM) as a particularly promising approach. By 2040, estimates suggest there will be more than 110 million people affected by the condition worldwide – though, if appropriately treated, only a small number of these patients will undergo significant visual deterioration over time.

Identifying and treating patients at higher risk for rapid glaucoma worsening earlier is paramount for reducing the possibility of vision loss and functional impairment. Specifically, early risk stratification enables non-specialists, like general ophthalmologists and optometrists, to refer higher-risk patients to glaucoma specialists promptly while setting longer follow-up intervals for lower-risk individuals. There's just one problem: we're short-staffed.

Though the number of eye care professionals in most countries has increased in recent years, it still remains insufficient (1). Indeed, we are at the precipice of a surge in glaucoma cases and relying solely on fellowship-trained glaucoma specialists to triage all patients may become impractical. DLMs, in this regard, could be key. In fact, we recently trained a DLM using data from glaucoma patients at the Wilmer Eye Institute spanning 2013 to 2021 (2) – a process in which we sought to predict which eyes would go on to need surgery for uncontrolled glaucoma.

Our dataset comprised several thousand eyes with baseline visual field (VF) and optical



*Eye image credit: Rawapixel.com*

coherence tomography (OCT) data, as well as clinical and demographic information. During preprocessing, we oriented and stacked OCT and VF data into a three-channel image. Then, a vision transformer was used to extract features from images, followed by spatial features fed into a fully connected neural network for prediction (needing future surgery for uncontrolled glaucoma). The training process included mapping input data to the probability of requiring glaucoma surgery, followed by validation, performance evaluation, and iterative improvement.

Notably, our DLMs achieved AUC values over 0.8 at predicting future surgery

from a single baseline ophthalmology visit. Our model also made surgical predictions for different time intervals, up to five years in the future – thus giving us a sense of how “urgent” the need for surgical intervention was. To do this, our DLM relied on several key input features: lower VF MD, higher IOP, thinner average OCT RNFL thickness, and higher VF PSD.

However, several considerations stand in the way of translating AI-driven predictive models from research settings to routine clinical practice. First, DLMs possess an inherent “black box” nature, which makes it difficult to interpret the underlying rationale





behind their predictions. It is essential that clinicians understand how these models arrive at their predictions so that they can trust them for decision-making. Today, various techniques exist to generate and display model results interpretably to the clinician – such as feature importance in the results presented above.

In addition, DLMs heavily rely on large volumes of labelled data for training, and the quality, diversity, and representativeness of this data significantly impact model performance – biased or unrepresentative datasets can lead to skewed or unreliable predictions. Adhering to standards such

as patient privacy and data security will, therefore, be essential for responsible model development and deployment.

For future work, prospective and external validation is essential; studies must prioritize assessing DLM performance across diverse patient populations and healthcare settings. Additionally, future work must seek to understand how patient outcomes change when AI-assisted care is implemented. Concurrently, we must optimize the deployment of DLMs in clinical settings by studying how best to integrate such models into the workflow and how best to leverage the complementary strengths of

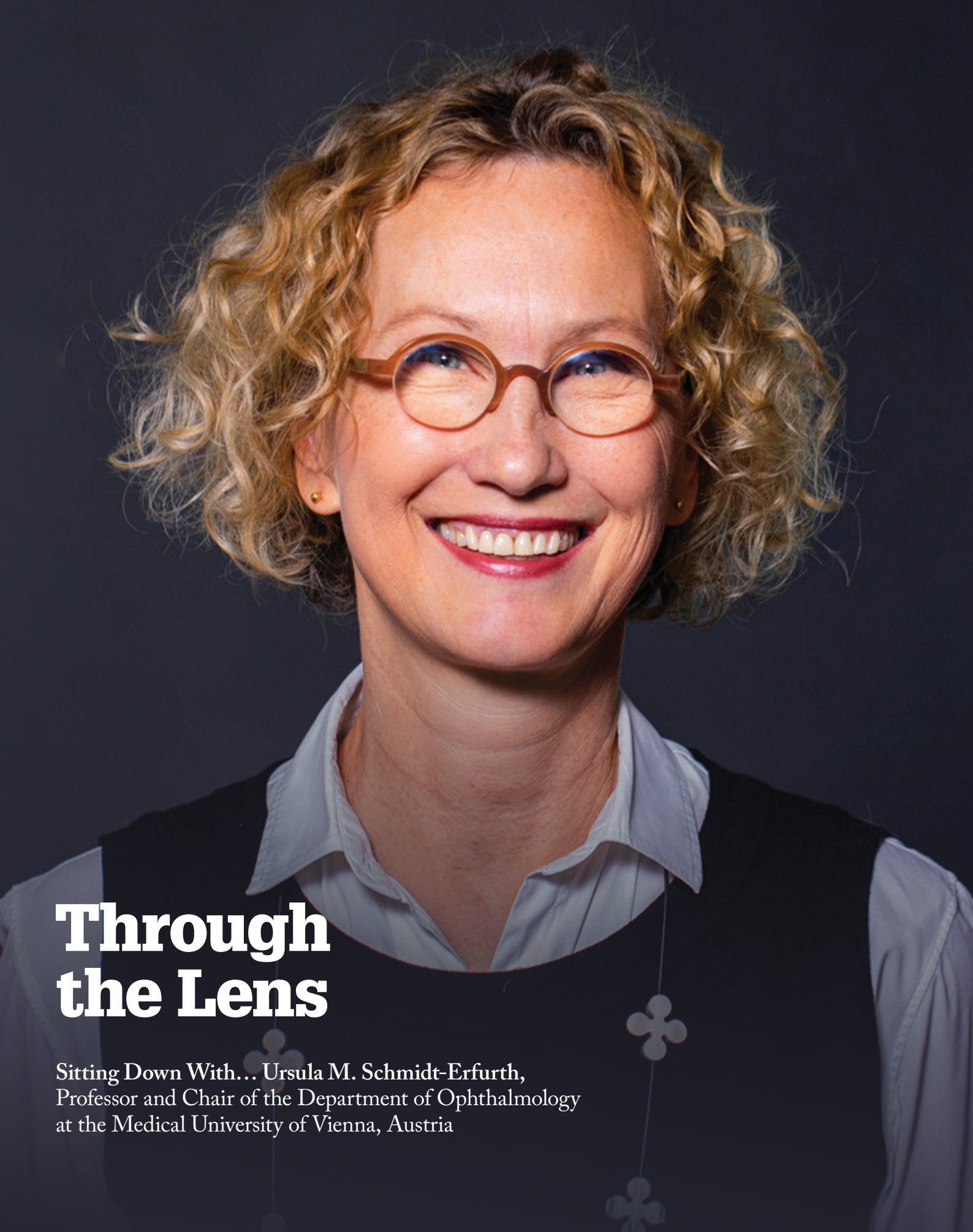the AI model and the clinician to arrive at the best decision for our patients.

I predict that AI will become an integral component of glaucoma care within the next 10 years. However, we need to study the important details outlined above to ensure that AI's potential is maximized.

*Jithin Yohannan is Assistant Professor of Ophthalmology, Glaucoma and Anterior Segment, at Johns Hopkins Wilmer Eye Institute, Columbia and Bel Air, MD.*

*See references online at: [top.txp.to/ai/glaucoma](http://top.txp.to/ai/glaucoma)*





# Through the Lens

Sitting Down With... Ursula M. Schmidt-Erfurth,  
Professor and Chair of the Department of Ophthalmology  
at the Medical University of Vienna, Austria



How and why did you become an ophthalmologist?

The significance of visual perception cannot be overstated; it constitutes 90 percent of our sensory input. From the way we dream to understanding the emotions of others, our existence is innately tied to what we see. If you consider our perception of reality, for example, this is almost entirely driven by our personal, seen experiences. What someone sees as blue, another might perceive as green – and it is this convergence of objectivity and subjectivity that has held my attention across the years.

How did you shift gears from developing photodynamic therapy for AMD to the application of artificial intelligence?

Photodynamic therapy was a big step away from burning the retina at the affected area seen on angiography. The old rule was: if it shows up on angiography, burn it with a laser. But the bright spot becomes a dark spot, which is, of course, a scar and loss of retinal function. In my mind, there had to be alternative approaches.

After searching through the literature for other pathological vessels that can be closed, I came across photodynamic therapy. At the time, this method was used against tumors by occluding their vessels and injecting dye into the vasculature. It is activated by light, which causes the internal wall of the vessels to become damaged, meaning they don't leak any more or continue to grow. This was a huge step.

It was my first patent – acquired with my team at Harvard – and it shaped the treatment of age-related macular degeneration (AMD) for 10 years (from 1996 to 2006), resulting in millions of people treated.

Not long after this insight, I established a reading center dedicated to analyzing

images from clinical trials, particularly those of the retina, to assess the efficacy of various substances. We became a hub for image analysis crucial to regulatory approval in a vast market. Operating from Vienna, Austria, we embraced digital medicine early on, delving into digital image analysis, and harnessing insights from extensive datasets. “Big data” led to the establishment of the Laboratory for Ophthalmic Image Analysis (OPTIMA, a computer science group in 2013, spearheaded by true artificial intelligence (AI) experts, not just clinicians with a passing interest in IT. Our focus shifted towards developing algorithms capable of pinpointing disease biomarkers in the retina with unmatched precision, speed, and reproducibility. Currently, my primary focus lies in leveraging AI for the diagnosis and treatment of retinal diseases in real-world clinical practice.

How might AI impact teaching and learning in the future?

AI has the capacity to bring healthcare professionals together; it is not something we should fear. It sets the stage for improved communication and insights that will more and more change our understanding of ophthalmic treatment. But it needs big data. In medicine, we need to pool together our images and learn from the experiences of countless patients, moving beyond anecdotal evidence to evidence-based practices backed by the data of millions. Shared care is bringing early diagnoses to everyone – even the people that wouldn't have time or means to see an eye doctor. And because AI is not as expensive as a human expert, it is also not as limited.

AI significantly improves our understanding of disease mechanisms. Take geographic atrophy, for example. An AI-based analysis of trials for this disease showed that the retina

progressively thins, leading to the dropout of photoreceptors before pigment loss becomes clinically apparent. This discovery fundamentally changed our understanding and educational approach to AMD. Moreover, the digital era facilitates instantaneous sharing of insights and knowledge through platforms like virtual conferences. The exchange of insights owes much to AI's ability to vividly illustrate complex features and phenomena and detect associations.

Could you tell us about your proudest achievements?

Generally, the past is encouraging – because it serves as a foundation for future growth. With each insight comes a question, which leads to another answer. Rather than pinpointing a singular highlight, I embrace the ongoing evolution of ideas. It is a continuous, dynamic process – or a collaborative effort where minds engage in dialogue, exchanging expertise and inspiration. This interconnectedness and exchange of knowledge have always fuelled my passion and continue to do so today.

What career advice do you have for the rising stars of ophthalmology?

I would refrain from advising someone to build – or care – about their “career.” Follow your passion and find growth in the things that matter to you. Don't fixate on side-effects like awards to define your professional life either. Instead, pursue what genuinely interests you, even if it is challenging. Seek advice, gather ideas, and collaborate with others who share the same spirit and can offer valuable insights. Progress may be gradual, and there will be times when things move slowly, but don't let that deter you. Ultimately, find fulfillment in what you do and surround yourself with a supportive community that you enjoy being a part of.

# BIOMECHANICS MEETS TOMOGRAPHY

## HEY CORVIS ST

I just took a look at the tomography.  
These values call for caution.  
I don't think I would operate.

## HI PENTACAM

The biomechanics looks good, though.  
The cornea is very stable.  
I don't see any problem with operating.

## O.K. TOGETHER NOW

Tomography and corneal biomechanics  
together make the decision easier:  
Surgery could be an option.

Corvis® ST meets Pentacam®:  
Combined measurement results  
for a safe decision on surgery

Benefit from the combination of biomechanical data from the Corvis® ST and tomographic data from the Pentacam®. Provide surgical care to more patients safely!



Want to learn more about the optimized TBI  
and corneal biomechanics?

Check out [www.corneal-biomechanics.com](http://www.corneal-biomechanics.com) for more...