



A Sponsored Supplement From
the Ophthalmologist

As Easy as ABiC

Meet the masters of the new comprehensive MIGS

Authors

Mahmoud Khaimi

Mahmoud Khaimi is a Clinical Associate Professor at the Dean McGee Eye Institute/University of Oklahoma in Oklahoma City, USA. He is recognized as a world authority on canal based surgery and has given numerous national and international lectures.

Norbert Koerber

Norbert Koerber specializes in cataract and glaucoma surgery, and runs a group practice and an outpatient surgery center in Cologne, Germany. He has published over 150 publications and presentations in the field of cataract, refractive and glaucoma surgery.

Mark Gallardo

Mark Gallardo is an ophthalmologist and glaucoma specialist. He has worked in ophthalmology for nearly 20 years, and currently is affiliated with Hospitals of Providence Sierra Campus, Las Palmas Medical Centre and University Medical Center of El Paso, Texas, USA.

Savak Teymoorian

Sev Teymoorian is a board certified ophthalmologist, and a cataract and glaucoma specialist at Harvard Eye Associates, Laguna Hills, California, USA.

Leon Au

Leon Au is a consultant glaucoma specialist at the Manchester Royal Eye Hospital, UK. He is an international leader in innovative MIGS and conducts clinical trials with these new procedures.

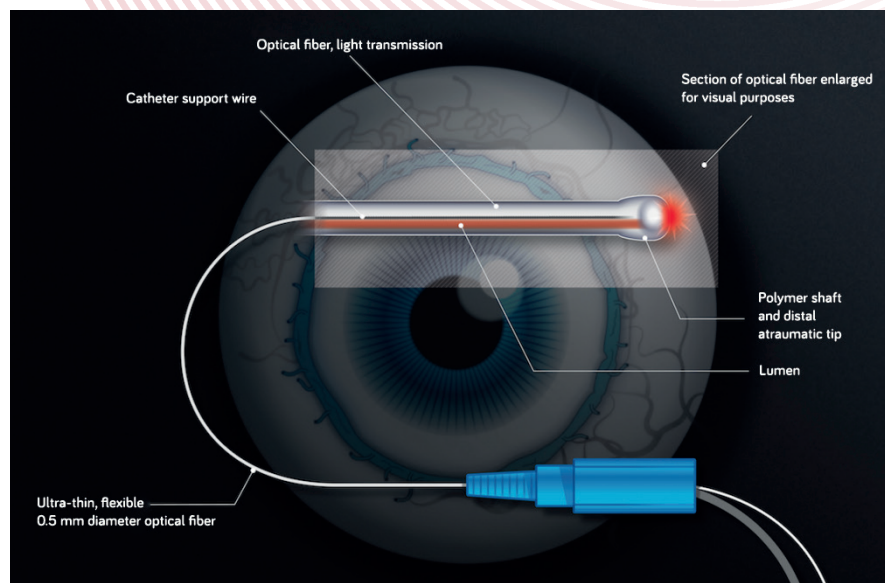
Introducing ab- interno canaloplasty (ABiC)



By Mahmoud Khaimi, MD

After a decade of traditional canaloplasty procedures, I have accumulated probably more data on the intervention than any other US surgeon. Ab externo canaloplasty is an intricate operation, comprising probe insertion into Schlemm's canal; attachment of a prolene suture to the probe; probe retraction with viscodilation; and suture ligation to maintain canal patency. Some traditional canaloplasty patients, however, get viscodilation without suturing – and, when I reviewed my data, I saw that these patients had excellent three-year outcomes. This revelation suggested that the ab externo suture approach was unnecessary – and that's how I came to be involved in the genesis and subsequent development of ABiC.

I had tremendous confidence in ABiC from the start; having employed traditional canaloplasty for years, I knew that treating the drainage system gives excellent results. Traditional glaucoma surgery such as trabeculectomy and glaucoma drainage devices are associated with sight-threatening risks; MIGS procedures are safer, but most of them are little better than a crapshoot, because surgeons cannot know the location of the blockage. From a theoretical standpoint, ABiC makes far more sense, as it safely rejuvenates the entire natural out-flow system. With hindsight, the advantages are obvious. Absent a diagnostic that identifies the site of outflow blockage, why not treat



Features of the iTrack catheter.

Summary of percentage reduction in IOP and medication use compared to baseline

	ALL EYES (n=59 pre-op)		PHACO + ABiC (n=35 pre-op)		STANDALONE ABiC (n=24 pre-op)	
	12-month	18-month	12-month	18-month	12-month	18-month
n (eyes)	38	34	18	18	20	16
Reduction in IOP	25.7%	23.6%	24.1%	22.8%	27.9%	25.0%
Reduction in number of medications	76.2%	64.8%	89.5%	84.2%	64.8%	44.1%

Table 1: Retrospective analysis, single-center, non-randomized study of efficacy and safety of ABiC in reducing IOP and glaucoma medication dependence in patients with uncontrolled mild to moderate primary open angle glaucoma over 18 months (I). "Healon" viscoelastic used for canal dilation (~ 35 clicks).

the whole outflow system? Indeed, doing so addresses all drainage problems, regardless of their precise location – whether in trabecular meshwork (TM), Schlemm's or collector channels.

Unfortunately, ABiC hadn't been done before, so I had to work it out myself. There were no guidelines regarding appropriate incision sites or optimal goniotomy and viscodilation techniques. My long experience of traditional canaloplasty was tremendously helpful, however, and I developed a simple technique based on tools available to all surgeons. And once people became aware of ABiC, patients began coming from all over

the world to have the procedure. I've done over 1000 ABiCs so far, and the 18-month outcomes are quite impressive (Table 1).

I used to boast that traditional canaloplasty was the safest, least invasive procedure, but it can't compare with ABiC. My view, however, is that being safe is good but not good enough. Our job is to actually reduce IOP as that's the only way to treat glaucoma. Furthermore, reducing IOP results in decreased medication burden; patients have an almost 100 percent chance of a lower number of drops after ABiC, and an excellent chance of requiring no drops at all.

Despite being so minimally invasive,

ABiC is extremely effective: it not only forces open herniations in Schlemm's canal, but it also dilates all the collector channels. And you can see it happening! As you withdraw the catheter and push viscoelastic through the collector channels and into the venous system, forcing away the blood, the perilimbal vessels blanch right in front of you. You don't see this with any other technique.

ABiC also mediates an ~80 percent reduction in post-operative chair time, and eliminates the 4–6 week recovery period of traditional glaucoma surgery: with ABiC, patients can see with the treated eye straight after surgery. Previously, post-operative glaucoma care involved complex rehabilitation of fragile patients, but now it's like outpatient care. The difference between ABiC and traditional methods is like night and day – it has absolutely revolutionized patient outcomes.

On the right track

The unique attributes of the iTrack catheter are critical to ABiC. Firstly, its fiber optic tip gives the surgeon continuous feedback regarding location, so there is no chance of unknowingly ending up in a suprachoroidal drainage system. With competing devices, you never know exactly where you are.

Secondly, the iTrack's internal guide wire makes it sufficiently sturdy to push through herniations, but not so rigid that it might force an artificial pathway. Thirdly, the iTrack's sophisticated injector releases a precisely measured aliquot of viscoelastic per click. No other viscodilation devices come close to the iTrack.

“Absent a diagnostic that identifies the site of outflow blockage, why not treat the whole outflow system?”

ABiC is very broadly applicable: candidates include virtually all those with open angle glaucoma, or any kind of secondary open angle glaucoma, who need IOP reduction. The only absolute contraindications to ABiC

are patients with neovascular glaucoma or chronic angle closure glaucoma, as their drainage systems are closed up with synechiae, preventing access to the canal. For the great majority of patients, ABiC is easily combined with cataract surgery. And regardless of whether glaucoma or cataract drives the surgery, the required intervention can be combined with the procedure for the other condition, because they are both so atraumatic. Furthermore, the post-ABiC IOP will almost certainly be lower without drops than pre-ABiC IOP with drops. Finally, ABiC is FDA-approved as a stand-alone procedure – and that's a huge advantage, because most other MIGS procedures must be done with cataract surgery. Only ABiC can be used either stand-alone or combined. And only ABiC treats the entire system in a very natural way. There are no residual implants, no tissue ablation, and no bridges burnt with regard to future surgical options.

In summary, my plea to the glaucoma community is this: we don't know the site of outflow blockage, so why don't we take a comprehensive approach and dilate the whole drainage system using this very safe, natural and efficacious method?

Reference

1. Data to be presented at ESCRS LISBON 2017

The Evolution of ABiC



By Norbert Koerber, MD, FEBO

Schlemm's canal-based interventions for IOP reduction are well-known and long

established. Traditional (ab externo) canaloplasty procedures regularly achieve IOPs of 12.3 to 12.5 mmHg when combined with cataract surgery, and 14 mmHg in stand-alone operations in phakic eyes. Its excellent risk profile (no sight-threatening complications) is well suited to patients for whom trabeculectomy carries unacceptable risk. But it's difficult and time-consuming: it can require an hour of demanding precise surgery.

Simpler is better

Canaloplasty usually involves suture implantation; however, we observed that

canaloplasty patients had very similar outcomes regardless of whether or not they received a suture (1), raising a question: if viscodilation alone is sufficient for efficacy, why not dilate the canal from the inside and avoid the challenges of the ab externo suturing approach? And that was the genesis of ABiC.

ABiC's principle of action, therefore, is the same as for traditional canaloplasty, namely viscoelastic-mediated dilation of three targets – Schlemm's canal, the TM and collector channel ostia. By opening the canal and the ostia, and stretching the TM to create microruptures, ABiC

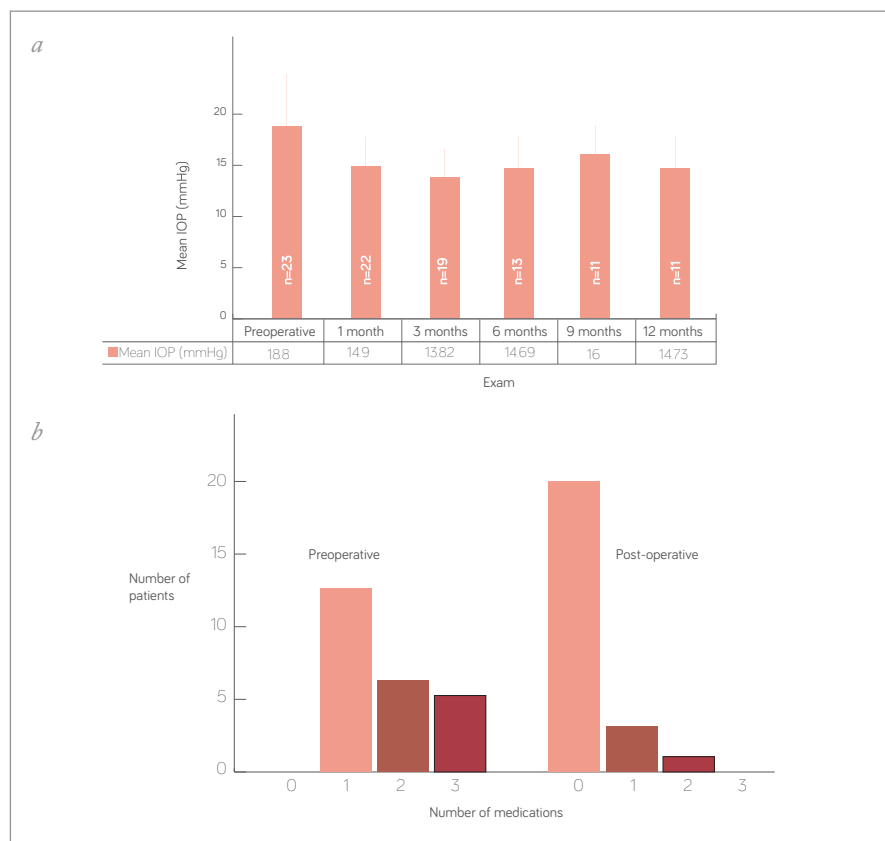


Figure 1. Reductions in post-operative IOP and medication use after ABiC. Twenty three eyes (10 OS, 13 OD) of 23 patients (mean age, 78 ± 5.62 years; 12 male: 11 female) were enrolled in the study. Reductions in mean IOP at 1, 3, 6, 9 and 12 months (a) correspond to reductions in IOP of 20.74%, 26.49%, 21.86%, 14.89%, and 21.65% respectively. Overall, the mean number of medications was reduced from 1.69 preoperatively to 0.21 at the last follow-up visit. Preoperatively, all patients required at least one medication, with 5/23 (22%) patients requiring three medications to control IOP (b). At the last follow-up visit, only 4/23 (17%) of patients still required anti-glaucoma medication (one medication in three patients, two medications in one patient), versus 100% of patients preoperatively.

restores natural drainage.

A principle differentiator of ABiC, however, is that it addresses the whole 360° circumference of the canal. No other MIGS is as comprehensive. For example, implant-based systems affect only one small part of the canal, which may or may not comprise an effective outflow to collector channels. And ablative procedures that address more than just the point of implantation, like the trabectome, often irreversibly destroy part of the TM. Only ABiC recognizes real pathology by addressing the whole drainage system.

ABiC seems at least as safe as traditional

canaloplasty, and is perhaps a little safer in some aspects. Sometimes we see transient post-operative hyphema due to reflux from collector channels into the anterior chamber (AC) via Schlemm's; in fact, this is not a complication, but welcome evidence of good connectivity between the anterior chamber and the outflow system. I've seen a single case of Descemet's detachment in peripheral cornea, when viscoelastic was pushing into the cornea – but this resolved without further action. Certainly, patients undergoing ABiC require no more recovery time than for stand-alone cataract operations. By

contrast, traditional canaloplasty is associated with a few days of foreign body sensation and weeks of disturbed vision – and post-trabeculectomy astigmatic changes may take weeks to resolve. Another point is that ABiC leaves no implant (unlike other MIGS), making it a repeatable process. Furthermore, ABiC is much faster and easier to perform than traditional canaloplasty – it takes just 5–10 minutes. Anyone familiar with a gonioscope can easily adapt to ABiC.

As for efficacy, ABiC certainly reduces IOP to levels similar to those achieved by other MIGS – about 15 mmHg in combined operations. However, other MIGS are associated with high medication rates at one year, and ABiC out-performs them on this measure. My own study showed significant ABiC-mediated reductions in post-operative IOP and medication burden in patients with primary open-angle glaucoma (Figure 1).

My goal is to treat patients early, and I'm satisfied with a somewhat higher IOP if the medication burden is reduced – glaucoma medication has compliance issues, so a procedure that reduces eyedrop burden is very beneficial. ABiC is an ideal procedure for my purposes, as it mediates medication reduction in a low-risk way without precluding future surgical approaches. It's also compatible with combination approaches; indeed, there's an argument that ABiC should be offered with laser trabeculoplasty, and certainly in our surgery we'd recommend ABiC for patients who intend to have cataract surgery.

ABiC has grown into a procedure that is fast, effective, safe and easily combined with other interventions – and that's why there is so much interest in the technique among cataract surgeons and other ophthalmologists. I think uptake will continue to grow, especially if forthcoming three-year data demonstrate efficacy over the longer term. All the signs are looking good so far!

Reference

1. RA Lewis et al, *J Cataract Refract. Surg.*, 37, 682–690 (2011). PMID: 21420593.

Surgical Pearls: ABiC



By Mark Gallardo, MD

When it comes to ABiC, correct performance of each step will assist the procedure as a whole. Equally, suboptimal execution of any step will compromise the entire intervention. I have identified some 'dos and don'ts' which may help those wishing to embark on this procedure for the first time.

Initial incisions

Following the creation of a temporal clear corneal incision, make a side-port incision using a 15° super-sharp blade or a 27 gauge needle. Direct the side-port incision towards the nasal drainage angle; this allows the iTrack catheter to lie in the nasal angle and be easily grasped (a side-port incision perpendicular to the limbus may make the catheter move towards the center of the eye – more difficult to grab).

Make the side-port incision at 12 o'clock, irrespective of whether it is the patient's left or right eye; this will familiarize you with both forehand and backhand movements (which you will need when you encounter an obstruction in the canal requiring circumnavigation in the opposite direction).

Avoid limbal vessels when making corneal incisions; bleeding will stain the gonioprism coupling agent (viscoelastic) on the cornea and obscure your view. Stained viscoelastic can be washed away with balanced salt solution, but this only encourages more bleeding – a never-ending cycle.

Introduce viscoelastic into the AC. I recommend viscodispersive OVDs – these

better maintain AC pressure, and allow a deeper nasal angle for a better view. Viscocohesive agents tend to "burp" out of the clear corneal wound when you are manipulating instruments in the AC, resulting in a shallower AC and blood regurgitation into Schlemm's canal and possibly into the AC. Again, this will obstruct your view.

Some surgeons use constriction agents to pull peripheral iris away from the nasal angle; others suggest that a dilated pupil may help avoid damage to the central iris. Personally, I simply proceed with the pupil in the state that I find it.

Catheter: prepare, prime and re-prime Prepare the iTrack by immersion in balanced salt solution; this activates and lubricates the catheter surface. Next, prime the catheter with viscoelastic; I use Healon GV rather than Healon because I think it gives superior viscodilation. Re-prime the iTrack just before use in case the viscoelastic has withdrawn from the tip (sometimes we've had to re-prime with 8 clicks – which would represent 3 or 4 untreated clock hours!).

Introduce the iTrack through the side-port incision, oriented towards the nasal angle; secure it by taping it to the patient's forehead (experience shows this is the best way – Figure 1).

Make the otomy: a horizontal score – about 0.5 mm – in the pigmented portion

of the TM. ABiC novices should use a 25 gauge needle for this step. Don't go deep; only insert the very tip of the needle (overshooting the canal and entering the scleral plexus will cause bleeding). Applying posterior pressure on the lip of the TM at this point will reveal the outer wall of the canal and confirm your location.

Remember: ensure the eye is pressurized! Hypotony will result in blood entering the canal and the AC, staining viscoelastic and obstructing your view.

Grasp the catheter tip with surgical microforceps at an oblique angle – this facilitates canal intubation. An acute angle will complicate catheter introduction and risks damaging TM with the forceps. Only grasp 1–1.5 mm of the catheter – enough to push it into the canal and keep it secured in the canal, but not so much that it's unmanageably pliable.

You can't always avoid bleeding – Schlemm's is connected to the episcleral venous system. If blood obstructs your view of the ostia, place the iTrack proximal to the otomy and slide it over the pigmented portion of the TM. When you get to the ostia, the catheter naturally falls into it and enters the canal. The TM is like a train track – just let the catheter follow it.

Circumnavigation and viscodilation Push the catheter through the entire 360°

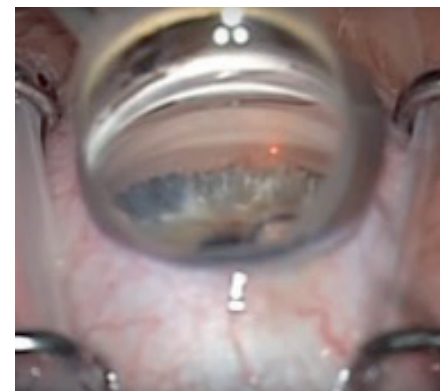
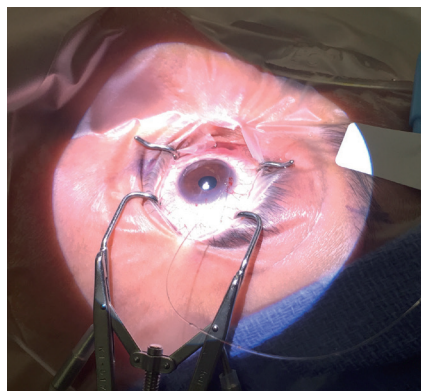


Figure 1. The catheter taped to a patient's forehead (left) and the iTrack fiber optic tip visible through the sclera (right). Credit: Mark Gallardo.

circumference. At times, blood may obscure good visualization; however, once the iTrack has been securely seated in the canal, further progress only requires that the surgeon can see the catheter. This allows one to grasp the iTrack catheter, even at a point distal to theotomy site, and continue circumnavigation. If there is too much blood in the AC to safely manipulate the catheter, introduce more viscoelastic to push aside the blood, or evacuate old viscoelastic and replace it.

If you encounter an obstruction during circumnavigation, infusing a little Healon GV – two or three clicks – into the canal often dilates it enough for the catheter to pass through. Alternatively, grasp smaller lengths of the catheter to make it more

rigid, so you can push through.

If the catheter is misdirected into the suprachoroidal space, withdraw it a little and try again. The beauty of the iTrack is the fiber optic tip – you always know where you are (Figure 1). If misdirection continues or if you encounter an obstruction you are unable to bypass, withdraw the catheter from the eye, make a paracentesis 180° away from the initial side-port incision, and circumnavigate in the opposite direction. Usually the false track and/or obstruction can be circumvented from the other direction; another iTrack advantage is that its length allows you to circumnavigate the entire canal.

With ABiC, we have a hyperpressurized AC (not the hypotonic AC of traditional

canaloplasty) which enables us to infuse more Healon and better dilate the distal system. A withdrawal rate of one clock hour every 1.5–2 seconds is fine; infuse two clicks of viscoelastic every clock hour.

Take care not to extend theotomy during withdrawal – it's important to minimize trauma to the TM, which can lead to scarring and creation of a non-functional area of TM. I use a second instrument – a Leicester hook – as a fulcrum to bear any force and protect the lip of theotomy. Check for blanching of the episcleral system – this confirms that the distal system is patent.

Finally, ensure you remove the viscoelastic! Residual OVD material blocks TM, causing post-operative pressure spikes.

ABiC (MIGS) with Selective Laser Trabeculoplasty (SLT)



By Savak "Sev" Teymoorian, MD, MBA

Over the last few years, we have witnessed a dramatic shift in glaucoma care which includes improvements in our ability to diagnose disease – through technological advancements such as OCT and electroretinography (ERG) – as well as our ability to treat it due to the "MIGS revolution". The overall result is that we're changing our approach of how we care for our patients; we've gone from reactively responding in cases of advanced disease to diagnosing and intervening at an earlier

stage. This, in turn, has encouraged the development of better surgical treatments for all patients – and especially for those with early-stage disease. These novel interventions, such as MIGS, allow us to reduce IOP very effectively, with minimal risk to the patient. But MIGS-mediated IOP reduction isn't always enough, and sometimes our patients still need additional therapies for IOP control.

However, I question the rationale of simply accepting a "MIGS 'n' Meds" approach. As physicians we try to improve patients' quality of life (QoL), but whatever benefits eyedrops may bring, they are not always associated with an enhanced QoL for the patient. And we are all familiar with the reasons for low compliance – side effects, cost, and administration issues to name a few. But now that we've pushed the surgical envelope with MIGS, why can't we also improve the medication angle? Reducing IOP while simultaneously decreasing eyedrop dependence would be the best scenario for many patients – and would improve their QoL.

MIGS 'n' SLT

In fact, there exist mechanisms for relieving the

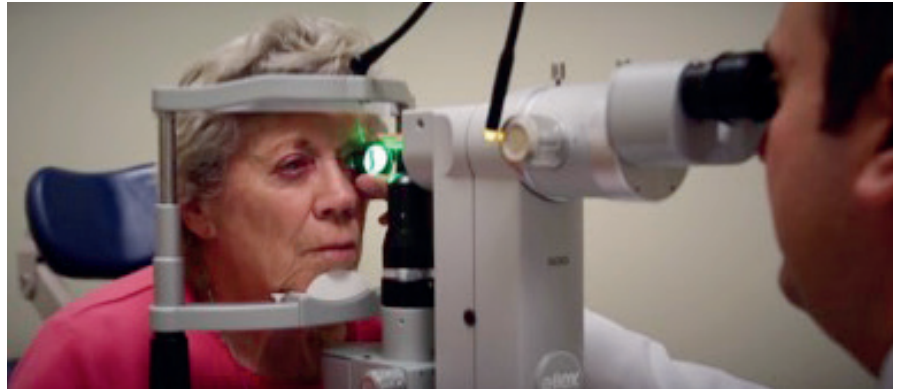
medication burden after a MIGS procedure; in particular, the treatment paradigm that utilizes a MIGS-SLT combination is a very effective way of controlling IOP without recourse to eyedrops. My experience is that MIGS augmentation with SLT provides an effective treatment combination that, though not suitable for everyone, is suitable for a large majority of patients; after all, most patients fall within the range of being ocular hypertensive to having moderate glaucomatous disease, and it is in these patients that MIGS procedures are increasingly used. I've found that combining SLT with MIGS procedures such as ABiC enables patients to achieve well-controlled IOPs at targeted levels. It's atraumatic and effective – they recover very quickly after surgery and rarely need additional procedures.

Despite this, many physicians automatically revert to eyedrops when they want to supplement MIGS. Why would you accept a therapy modality that has such a low compliance rate when the great majority of your patients could have their IOP reduced by a MIGS-SLT combination? It's like an addiction! In fact, it's interesting to pose these kinds of questions in real life. So during my various presentations at

conferences I routinely ask my colleagues: "How would you treat a newly diagnosed glaucoma patient?" and 70 percent propose medication; but if I ask "How would you want to be treated?" 70 percent opt for SLT! In the end, however, physician attitudes may be overtaken by increased patient awareness. I'm doing my bit in that regard – in my clinic waiting rooms, we always have videos playing, one of which shows a real-life SLT procedure that I perform on a patient (available at <http://bit.ly/SLTSevTey>). As a result, I find that many patients are already interested in and ready to discuss the laser concept by the time they come into the examination room.

Which MIGS?

Regarding the choice of MIGS, my initial personal preference is for procedures that minimize the treatment footprint. And of the three categories of MIGS – canal-based, suprachoroidal and sub-conjunctival – the least disruptive procedures are the canal-based approaches that enhance the conventional outflow. Of these, ABiC reinvigorates the normal physiological flow rather than relying on the creation of artificial drainage channels. So if you want to improve QoL in the most natural, least risky way, ABiC seems like an obvious option. Although it may not reduce IOP as much as trabeculectomy might, it has a far better side-effect profile – providing



A patient undergoing SLT. Credit: Sev Teymoorian.

a more favorable risk-to-benefit ratio. When selecting among treatment options, risk-to-benefit must be considered since the goal is to provide the highest QoL for our patients. ABiC can also be augmented with SLT if necessary.

Which patients?

The earliest-stage cases I could contemplate for SLT-MIGS would be those with very high risk of ocular hypertension or very early glaucoma with a visually significant cataract. They'll need cataract surgery anyway, so you can just augment that with a MIGS procedure. You could also justify early intervention with MIGS in cases where the cataract isn't visually significant, but glaucoma is getting worse; however, these would be mild or moderate cases rather than early cases.

Ask yourself this...

In summary, for anybody still addicted to MIGS 'n' Meds, let's just think about the rationale of the strategy. The intent is to reduce IOP so as to stabilize glaucoma, maintain good vision, and ultimately provide a good QoL for the patient. But, as noted above, everyone knows glaucoma medications are associated with poor compliance – so very often glaucoma will progress despite the eyedrop prescription. And now we know there's a better way – combine MIGS with SLT. The side effect profile is the same or better, and there are no compliance issues. So if a patient is having a MIGS procedure, such as ABiC, why not complement it with the laser when needed? And finally, to any physician who remains wedded to MIGS 'n' Meds, let me pose this: what would you do in your own eye?

ABiC in the MIGS Treatment Armamentarium



By Leon Au, MD

MIGS is a term that embraces techniques and devices intended to lower IOP by methods which are less traumatic than conventional 'trab or tube' approaches. Current MIGS procedures mostly fall into three categories: sub-conjunctival drainage procedures, suprachoroidal / supra-ciliary drainage procedures, and Schlemm's canal-based procedures.

Schlemm's canal-based procedures aim to restore the natural physiological

aqueous outflow. This can be achieved by TM removal techniques, such as the Kahook Dual Blade (New World Medical), the Trabectome or gonioscopy-assisted transluminal trabeculotomy. TM resistance can also be bypassed using devices such as the iStent (Glaukos) and the Hydrus (Ivantis). Furthermore, Schlemm's canal can be dilated with viscoelastic, as in ABiC (Ellex). All these procedures share the advantages of an excellent safety profile and the avoidance of post-operative hypotony.

The pressure lowering effect, however, is limited by the distal drainage resistance, which forms an IOP “floor” of around 16 mmHg, meaning that these procedures are more suitable in patients with mild-to-moderate glaucoma or in patients who also require cataract surgery.

By contrast, sub-conjunctival devices like the Xen implant (Allergan) and the InnFocus microshunt (Santen) aim to divert aqueous extra-ocularly into a sub-conjunctival / Tenon's space, rather than attempting to restore physiological outflow; in appropriate patients, they can deliver very effective IOP reductions. Further, they can work well as stand-alone interventions – whereas other MIGS procedures rely on the synergistic effect of phacoemulsification to deliver their pressure lowering effects. Given their non-physiological nature, higher risk profile and the need for post-operative bleb management, sub-conjunctival methods tend to be used later in the treatment paradigm.

Suprachoroidal drainage procedures also rely on non-physiological outflow mechanisms; examples include the iStent Supra (Glaukos; not currently available) and the CyPass micro-stent (Alcon). Another drawback of these systems is that the suprachoroidal space tends to be very “reactive” – scarring can be a significant issue. Subconjunctival fibrotic activity can be modulated with the use of antimetabolites, but this is not yet possible in the suprachoroidal space. Moreover, the long term efficacy and safety outcomes of suprachoroidal drainage devices are yet to be established.

Choosing the most appropriate MIGS procedure for your patient

Generally, the choice of MIGS procedure tends to be influenced by surgeon preference, desired IOP lowering effect, safety profile and – to some degree – reimbursement criteria. That said, the prospect of reducing medication burden is becoming increasingly important to physicians. In fact, the entire

treatment paradigm is evolving away from the use of multiple eye-drops because of well-characterized issues of adherence and persistence, together with their negative effects on ocular surface and quality of life. MIGS procedures that reduce the need for medication in patients with mild-to-moderate glaucoma can therefore be highly desirable; they may be useful even in more advanced cases, as a reduction in the number of topical medications required allows recovery of ocular surface and enhances the success of future filtration surgery. Of course, MIGS provides more than just medication reduction: the IOP-lowering effects of these procedures have been widely characterized – and in suitable cases, opting for MIGS may avoid the need for more invasive drainage surgery.

“Another benefit of ABiC is its ‘fit and forget’ nature.”

However, any surgical procedure contemplated in the early, asymptomatic stages of disease must, above all, be safe. Again, Schlemm's canal approaches, not least ABiC, have a highly favorable safety profile that doubtless influences surgeon choice in many instances.

Another benefit of ABiC is its ‘fit and forget’ nature. Other MIGS interventions, such as the Xen implant, require multiple postoperative visits and bleb management, and necessitate the prolonged use of postoperative steroids (and bleb interventions such as needling are required in about 30 percent of patients).

The choice of MIGS intervention is also influenced by patient-specific issues. For example, conjunctival surgery is contraindicated in people with ocular

surface problems, such as severe dry eye, pemphigoid, or conjunctival scarring from previous surgery – and is also less successful in Afro-Caribbean and diabetic patients. For these patients, Schlemm's-based surgery or suprachoroidal drainage devices provide useful alternatives. That said, the suprachoroidal space is very reactive and scarring can be a problem; by contrast, we have yet to identify any risk factors for failure in Schlemm's interventions.

The need for cataract surgery also may influence the choice of MIGS; in cataract patients with mild-to-moderate glaucoma, combining Schlemm's surgery with cataract removal will both improve vision and reduce the topical medication burden. Indeed, Schlemm's procedures have been shown to work particularly well when combined with cataract surgery; in the US, the iStent (Glaukos) and CyPass (Alcon) are approved only in conjunction with cataract surgery. Conversely, Schlemm's canal-based surgeries are not as effective when employed as stand-alone interventions; however, there have been recent suggestions that ABiC is effective in a stand-alone context, and I look forward to seeing more data on this point.

As more data emerge, we will be better able to objectively compare the different MIGS procedures and identify the best procedure for different types of patient. A priori, however, there are good reasons why ABiC may make more sense than TM removal or stent implantation. In particular, these methods address only very small quadrants of the drainage system; the surgeon's hope is that the treatments will hopefully be positioned near significant collector channels. Unfortunately, there is still no definitive method for identifying collector channels preoperatively or perioperatively. ABiC, by contrast, treats the whole 360° of the canal. It is also the only procedure that addresses the blockage of collector channels by TM herniations. The emerging ABiC data are extremely encouraging, and we look forward to further clinical trials, in larger populations and with longer follow-ups.